



# Journal of the ASEAN Federation of Endocrine Societies

Volume No. 41 Special Edition 1 | ISSN 2308-118x (Online)



MEMS ANNUAL CONGRESS  
**MAC 16** 2026



## SYNERGY IN ENDOCRINOLOGY

**22 - 24 MAY 2026**  
Hilton & Le Méridien Kuala Lumpur

[www.memsmac.org](http://www.memsmac.org)

Messages  
Organising Committee  
Faculty  
Programme  
Adult Oral Presentation  
Adult Best Poster Presentation  
Adult Best Case Report Presentation  
Adult E-Poster  
Paediatric Oral Presentation  
Paediatric Best Poster Presentation  
Paediatric Best Case Report Presentation  
Paediatric E-Poster  
Basic Science E-Poster



[www.asean-endocrinejournal.org](http://www.asean-endocrinejournal.org)

# JAFES





# Journal of the ASEAN Federation of Endocrine Societies

Volume No. 41 Special Edition 1 | ISSN 2308-118x (Online)

The publication of the abstracts for the 2026 MEMS Annual Congress as a special edition of the Journal of the ASEAN Federation of Endocrine Societies is a service of the journal to its member societies. The statements and opinions expressed in this publication are those of the individual authors and do not necessarily reflect the views of the Journal of the ASEAN Federation of Endocrine Societies (JAFES). The abstracts included have been selected by the Convention's Scientific Committee and have not undergone the editorial deliberation and peer review of the JAFES. JAFES is not responsible or liable in any way for the currency of the information, for any errors, omissions or inaccuracies, or for any consequences arising therefrom. With respect to any drugs mentioned, the reader is advised to refer to the appropriate medical literature and the product information currently provided by the manufacturer to verify appropriate dosage, method and duration of administration, and other relevant information. In all instances, it is the responsibility of the treating physician or other healthcare professional, relying on independent experience and expertise, as well as knowledge of the patient, to determine the best treatment for the patient.



**Malaysian Endocrine  
& Metabolic Society**



## Welcome Message by the President of MEMS

Dear distinguished guests, esteemed colleagues, and friends,

It is my profound honour to officially welcome you to the **16<sup>th</sup> Malaysian Endocrine and Metabolic Society (MEMS) Annual Congress 2026 (MAC 16)**.

When we first envisioned this gathering, our goals were anchored by our theme, **'Synergy in Endocrinology.'** Today, that vision is a reality, and I am exceptionally proud to announce that we are joined by over 1,000 delegates representing eight different countries. We are deeply honoured by your attendance, which stands as a profound reflection of our unified commitment to advancing endocrine healthcare.

**'Synergy'** embodies our steadfast commitment to dismantling medical silos, integrating clinical expertise with cutting-edge research, and cultivating the multidisciplinary collaboration necessary to treat complex endocrine disorders. Within our modern healthcare framework, we recognize that endocrine conditions do not exist in isolation; rather, they are deeply embedded within an intricate, interconnected web of metabolic processes.

To truly reflect our theme of synergy, the scientific programme has been meticulously planned to bring together a distinguished faculty of local and international experts, whose combined insights will illuminate how we can harness our collective intelligence to elevate the standard of patient care.

The enthusiasm for research and innovation at this year's congress is truly remarkable, underscored by the submission of an outstanding **296 abstracts**.

At its core, MAC 16 serves as a collaborative community designed for the exchange of knowledge. I strongly encourage you to engage deeply in academic discourse, review the diverse abstract presentations, and forge meaningful professional connections. These interactions are the foundation of the innovative spirit our field requires.

This prestigious congress would not have materialized without the tireless dedication of our Organising Committee and the unwavering support of our industry partners.

Let us utilize our time together to translate the ideal of 'Synergy' into a lived reality for the patients we serve across Malaysia and beyond.

I wish you a highly engaging, inspiring, and fruitful congress.

**Warmest regards,**  
**Dr Nurain Mohd Noor**

President  
Malaysian Endocrine and Metabolic Society (MEMS)



## Welcome Message from MAC 16 Chairperson

Greetings everyone!

On behalf of the Organising Committee, it is my great pleasure to warmly welcome you to the **16<sup>th</sup> MEMS Annual Congress 2026 (MAC 16)**.

Guided by the theme, '**Synergy in Endocrinology**,' this congress reflects the importance of collaboration in advancing endocrine and metabolic care across disciplines and regions.

This year, we received **296 abstract submissions**, reflecting strong scientific engagement and ongoing innovation within the endocrine community. MAC16 brings together **approximately 1,000 participants from eight countries**, providing a valuable platform for knowledge exchange and professional collaboration.

The pre-congress programme highlights focused, hands-on learning centred on the subject of **pituitary**, offering practical insights into dynamic testing and clinical application.

The main scientific programme features a distinguished faculty of international and regional experts. Highlights include the **3<sup>rd</sup> edition of the MAC Olympiad**, a flagship Endocrine Quiz Championship that brings together trainees and clinicians in a dynamic test of knowledge and clinical reasoning. The congress will conclude with a featured debate on the subject '**Incretin-Based Therapies: Friend or Foe?**', addressing a key and evolving area in contemporary practice.

We gratefully acknowledge the support of our industry partners, whose contributions have been instrumental to the success of this meeting.

We hope MAC16 will foster meaningful exchange, collaboration, and continued advancement in endocrine and metabolic health.

### **Dr Elliyyin Katiman**

Chairperson, Organising Committee  
MAC16 Annual Congress 2026



## MAC 16 Organising Committee

<b>MEMS President &amp; MAC Advisor</b>	: Dr Nurain Mohd Noor
<b>Organising Chair</b>	: Dr Elliyyin Katiman
<b>Scientific Chair (Adults)</b>	: Dr Tong Chin Voon
<b>Scientific Co-Chair (Paediatrics)</b>	: Professor Dr Noor Shafina Mohd Nor
<b>Committee Members</b>	: Dr Kang Waye Hann
	: Dr Lee Yee Lin
	: Dr See Chee Keong
	: Dr Siti Sanaa Wan Azman
	: Dr Subashini Rajoo
	: Dr Yusniza Yusoff
	: Ms Cheah Yet Mei



## International Faculty



**Prof Dr Jorma  
Toppari**  
*Finland*



**Prof Dr Miguel  
Debono**  
*United Kingdom*



**Prof Dr Mohamed  
Hassanein**  
*United Arab Emirates*



**Prof Dr Simon Pearce**  
*United Kingdom*



**Prof Dr Syed  
Faisal Ahmed**  
*United Kingdom*



**Assoc Prof Dr Rashida  
Farhad Vasanwala**  
*Singapore*



**Dr Akshay Jain**  
*Canada*



**Dr Daphne Gardner**  
*Singapore*



**Dr Edy Kornelius**  
*Taiwan, China*



**Dr Sonia Davison**  
*Australia*



**Dr Troy Puar**  
*Singapore*

## Faculty



**Prof Dato' Dr  
Mafauzy Mohamed**  
*Malaysia*



**Emeritus Prof Dr  
Chan Siew Pheng**  
*Malaysia*



**Prof Dr Chan Wah Kheong**  
*Malaysia*



**Prof Dr Jeyakantha  
Ratnasingam**  
*Malaysia*



## Faculty



**Prof Dr Lim Lee Ling**  
*Malaysia*



**Prof Dr Lim Soo Kun**  
*Malaysia*



**Prof Dr Muhammad  
Yazid Jalaludin**  
*Malaysia*



**Prof Dr Nor Azmi  
Kamaruddin**  
*Malaysia*



**Prof Dr Norlaila Mustafa**  
*Malaysia*



**Prof Dr Norlela Sukor**  
*Malaysia*



**Prof Dr Nur Azurah  
Abdul Ghani**  
*Malaysia*



**Prof Dr Rohana  
Abdul Ghani**  
*Malaysia*



**Prof Dr Shelina  
Oli Mohamed**  
*Malaysia*



**Prof Dr Shireene  
Ratna Vethakkan**  
*Malaysia*



**Assoc Prof Dr Chooi  
Kheng Chiew**  
*Malaysia*



**Assoc Prof Dr Elena Azizan**  
*Malaysia*



**Assoc Prof Dr  
Kang Waye Hann**  
*Malaysia*



**Assoc Prof Dr  
Suhaimi Hussain**  
*Malaysia*



**Assoc Prof Dr Chow Yok Wai**  
*Malaysia*



**Datuk Dr Asri Ranga  
Abdullah Ramaiah**  
*Malaysia*



**Datuk Dr Zanariah Hussein**  
*Malaysia*



**Dr Alexander Tan**  
*Malaysia*



**Dr Arini Nuran Md Idris**  
*Malaysia*



**Dr Azraai Bahari Nasruddin**  
*Malaysia*

## Faculty



**Dr Boey Ching Yeen**  
*Malaysia*



**Dr Chong Jen Lim**  
*Malaysia*



**Dr Fatimah Zaherah  
Mohamed Shah**  
*Malaysia*



**Dr Florence Tan**  
*Malaysia*



**Dr Foo Siew Hui**  
*Malaysia*



**Dr Janet Hong**  
*Malaysia*



**Dr Jeanne Wong  
Sze Lyn**  
*Malaysia*



**Dr Joyce Hong**  
*Malaysia*



**Dr Kiran Nair**  
*Malaysia*



**Dr Koay Yeang Wee**  
*Malaysia*



**Dr Kuan Yueh Chien**  
*Malaysia*



**Dr Lim Kim Piow**  
*Malaysia*



**Dr Lim Poi Giok**  
*Malaysia*



**Dr Lim Song Hai**  
*Malaysia*



**Dr Malathi Karupiah**  
*Malaysia*



**Dr Mandeep Singh  
Awtar Singh**  
*Malaysia*



**Dr Muthukkumaran  
Thiagarajan**  
*Malaysia*



**Dr Nalini M Selveindran**  
*Malaysia*



**Dr Ng Eng Khim**  
*Malaysia*



**Dr Noor Rafhati  
Adyani Abdullah**  
*Malaysia*

## Faculty



**Dr Nor Aizan Binti  
Ab Liah @ Ariffin**  
*Malaysia*



**Dr Nor Azham  
Hakim Darail**  
*Malaysia*



**Dr Nor Shaffinaz  
Yusoff Azmi**  
*Malaysia*



**Dr Nur Safira Abd Isa**  
*Malaysia*



**Dr Nurain Mohd Noor**  
*Malaysia*



**Dr Nurshadia Samingan**  
*Malaysia*



**Dr Raja Aimee Raja  
Abdullah**  
*Malaysia*



**Dr Raja Nurazni  
Raja Azwan**  
*Malaysia*



**Dr Radhakrishna  
A. Sothiratnam**  
*Malaysia*



**Dr Rokiah Ismail**  
*Malaysia*



**Dr Rosnawati Yahya**  
*Malaysia*



**Dr Saiful Kassim**  
*Malaysia*



**Dr Sarah Mubarak**  
*Malaysia*



**Dr See Chee Keong**  
*Malaysia*



**Dr Sharmila S  
Paramasivam**  
*Malaysia*



**Dr Siti Sanaa Wan Azman**  
*Malaysia*



**Dr Subashini Rajoo**  
*Malaysia*



**Dr Tan Li Ping**  
*Malaysia*



**Dr Wu Loo Ling**  
*Malaysia*



**Dr Yeap Swan Sim**  
*Malaysia*

**MAC 16 PRE-CONGRESS WORKSHOP**

# MASTERCLASS ON THE MASTER GLAND

Event ID CPDE77828

Clarke Ballroom, Level 6, Le Méridien, Kuala Lumpur  
21<sup>st</sup> May 2026, Thursday




## PROGRAMME

- 08:30 - 09:00 **Registration & Welcome Break**
- 09:00 - 09:15 **Welcome & Introduction**
- 09:15 - 10:05 **Bridging Anatomy and Imaging in Pituitary Evaluation**  
Dr Nur Safira Abd Isa
- 10:05 - 10:20 **MRI Quiz**
- 10:20 - 10:40 **Break**
- 10:40 - 11:15 **Provoking the Pituitary: Dynamic Tests Decoded**  
Dr Azraai Bahari Nasruddin
- 11:15 - 11:50 **Optimizing Prolactinoma Care: Beyond Dopamine Agonist**  
Dr Subashini Rajoo
- 11:50 - 12:25 **Diagnosing AVP Deficiency in the Era of Copeptin**  
Prof Dr Jeyakantha Ratnasingam
- 12:25 - 13:00 **Medical Therapy in Acromegaly**  
Datuk Dr Zanariah Hussein
- 13:00 - 14:15 **Lunch Break and Networking**
- 14:15 - 14:50 **Cells, Stains, and Secrets: Understanding Pituitary HPE**  
Dr Nor Aizan Abillah @ Ariffin
- 14:50 - 15:25 **The Balancing Act: Water Balance Revisited**  
Prof Dr Nor Azmi Kamaruddin
- 15:25 - 16:00 **Cushing's Disease Thrombosis**  
Dr Subashini Rajoo
- 16:00 - 16:30 **Tea Break & Networking**



**Programme**

**22<sup>nd</sup> May 2026, Friday**

**BALLROOM B + C**



0730 - 0820	<b>Registration</b>		
0820 - 0830	<b>Opening Remarks</b> <i>Eliyyin Katiman, Organising Chair, MAC16</i> <b>Welcome Speech</b> <i>Nurain Mohd Noor, President MEMS</i>		
0830 - 0915	<b>PLENARY 1: Health Effects of Endocrine Disruptors</b> <i>Jorma Toppari</i> <b>Chairperson: Tong Chin Voon</b>		
0915 - 1000	<b>PLENARY 2: Beyond Replacement: Bridging the Gaps in Adrenal Insufficiency</b> <i>Miguel Debono</i> <b>Chairperson: See Chee Keong</b>		
1000 - 1015	Introduction to <b>Ministry of Health Malaysia Steroid Card</b>		
1015 - 1045	<b>Best Case Report Presentation (Ballroom C Foyer)</b> <b>Tea Break / Trade Exhibition + <i>Tour d'MAC &amp; Tour d'Central</i></b>		
	<b>BALLROOM B</b>	<b>BALLROOM C</b>	<b>CLARKE BALLROOM</b>
1045 - 1215	<b>Symposium 1: CALCIUM &amp; BONE</b> <b>Chairperson: Noor Lita Adam</b> Hungry Bone Syndrome: Anticipate, Assess and Address <i>Florence Tan</i> Drug Holiday for Osteoporosis: How to Do it Right? <i>Yeap Swan Sim</i> Refractory Hypercalcemia: When Standard Therapy Fails <i>Foo Siew Hui</i>	<b>Symposium 2: THYROID</b> <b>Chairperson: Yong Sy Liang</b> Cardiovascular Risks of Hyperthyroidism <i>Simon Pearce</i> Thyroid Nodules: Which to Biopsy, Which to Watch? <i>Nor Azham Hakim Darail</i> When TSH & T4 Disagree <i>Sharmila S Paramasivam</i>	<b>Symposium 3: DSD</b> <b>Chairperson: Meenal Mavinkurve</b> Clinical Approach to DSD <i>Wu Loo Ling</i> Diagnostic Challenges and Management of DSD <i>Syed Faisal Ahmed</i> Surgical and Ethical Considerations in DSD <i>Koay Yeang Wee</i>
1215 - 1255	<b>MTE 1: Medical Therapies for Cushing's</b> <i>Noor Rafhati Adyani Abdullah</i>	<b>MTE 2: Approach to Hypokalemic Endocrinopathies</b> <i>Troy Puar</i> <b>Chairperson: Kuan Yueh Chien</b>	<b>MTE 3: Management of Osteoporosis in Children and Adolescents</b> <i>Rashida Farhad Vasanwala</i> <b>Chairperson: Annie Leong</b>
1255 - 1355	<b>Zuellig Pharma Lunch Symposium</b> <b>The Ascent to New Heights</b> <b>Chairperson: Chan Siew Pheng</b> <i>The Next Ascent: Dual Agonism Beyond GLP-1</i> <i>Jeyakantha Ratnasingam</i> <i>SURPASS the Status Quo: Reaching New Heights to Outpace DKD Progression</i> <i>Lim Soo Kun</i> <i>The SURMOUNT Expedition: Mapping the New Summit of Weight Loss</i> <i>Chong Jen Lim</i>	<b>Novo Nordisk Pharma Lunch Symposium</b> <b>Unravelling the Complex Interplay of CKM in T2D Management</b> <b>Chairperson: Rohana Abdul Ghani</b> <i>SUSTAINable Glycaemic and Weight Control in T2D with GLP-1 RAS</i> <i>Malathi Karupiah</i> <i>Connecting Heart and Kidney in Type 2 Diabetes: A Cardio-Renal-Metabolic Update</i> <i>Akshay Jain</i>	<b>AstraZeneca Lunch Symposium</b> <b>Tying the Knot Early: A Strategic Union for Better Outcomes</b> <i>Diabetes Care in Malaysia : Where Are We Today ?</i> <i>Lim Lee Ling</i> <i>Don't Wait to Escalate : The Power of Early Intensification</i> <i>Norlela Sukor</i> <i>Case in Focus : Optimising Early with the Right Therapy</i> <i>Ng Eng Khim</i> <i>The Clinician's Perspective : What Works in Practice ?</i> <i>Lim Lee Ling</i> <i>Norlela Sukor</i> <i>Ng Eng Khim</i>
			

## Programme

22 <sup>nd</sup> May 2026, Friday			
1355 - 1420	Trade Exhibition + <i>Tour d'MAC &amp; Tour d'Sentral</i>		
	<b>BALLROOM B</b>	<b>BALLROOM C</b>	<b>CLARKE BALLROOM</b>
1420 - 1500	<b>MTE 4: DTC: What's New in 2026?</b> <i>Kuan Yueh Chien</i>	<b>MTE 5: Optimizing Testosterone Replacement Therapy: Formulation Matters</b> <i>Kang Waye Hann</i>	<b>MTE 6: From Uncertain Diagnosis to Precision Medicine in DSD</b> <i>Syed Faisal Ahmed</i> <b>Chairperson: Rashdan Zaki Mohamed</b>
1500 - 1630	<b>Symposium 4: ADRENAL</b> <b>Chairperson: Subashini Rajoo</b> <i>When Aldosterone is Not Alone?</i> <i>Norlela Sukor</i> <i>From Somatic Mutations to Steroid Phenotype: Urinary Steroid Signatures in Primary Aldosteronism</i> <i>Elena Azizan</i> <i>Salivary Cortisol in Clinical Practice: When, Why and How?</i> <i>Miguel Debono</i>	<b>Symposium 5: OBESITY</b> <b>Chairperson: Masni Mohamed</b> <i>Rethinking Obesity: Limitations of BMI and Better Metrics</i> <i>Lim Lee Ling</i> <i>Obesity Care: Beyond the Drug</i> <i>Mandeep Singh Awtar Singh</i> <i>Thin Outside, Risky Inside: Managing TOFI</i> <i>Rohana Abdul Ghani</i>	<b>Symposium 6: DIABETES (Paediatric)</b> <b>Chairperson: Mazidah Noordin</b> <i>Clinical Conundrums in Childhood Diabetes</i> <i>Arini Nuran Md Idris</i> <i>Complexities in Managing T1DM in Young Children and Adolescents</i> <i>Nalini M Selveindran</i> <i>T2DM Management: What is New?</i> <i>Muhammad Yazid Jalaludin</i>
1630 - 1720	<b>Pharmaniaga High-Tea Symposium</b>  <i>Novel Combination of OAD with DPP4-inhibitor (Gemigliptin)</i> <i>Radhakrishna A. Sothiratnam</i>  	<b>Abbott Laboratories High-Tea Symposium</b> <b>Chairperson: Lim Lee Ling</b>  <i>Preserving Sight Through Early Intervention in Diabetic Retinopathy</i> <i>Shelina Oli Mohamed</i> <i>Optimizing Diabetes Management with iCGM</i> <i>Chan Siew Pheng</i>  	<b>MAC Olympiad</b>
		<b>Best Poster Presentation (Adult)</b> <i>Ballroom C Foyer</i>	<b>Best Poster Presentation (Paeds)</b> <i>Clarke Ballroom Foyer</i>
1720 - 1800	Trade Exhibition + <i>Tour d'MAC &amp; Tour d'Sentral</i>		
1930 - 2200	<b>MEMS Annual Dinner (exclusively for members &amp; by invitation only)</b>		




## Programme

23<sup>rd</sup> May 2026, Saturday

	BALLROOM B	CLARKE BALLROOM	
0740 - 0820	<p><b>Novartis Corporation Sunrise Symposium</b> Chairperson: <i>Jeyakantha Ratnasingam</i></p> <p><i>The Marathon Mindset for LDL-C: Advancing Long Term LDL-C Control Beyond Oral Therapies</i> <i>Lim Lee Ling</i></p> 	<p><b>Amgen Biopharmaceuticals Sunrise Symposium</b> Chairperson: <i>Wong Ming</i></p> <p><i>Prevention of Cardiovascular Events in Diabetic Patients</i> <i>Saiful B Kassim</i></p> 	
	<b>BALLROOM B + C</b>		
0820 - 0905	<p><b>PLENARY 3: Thyroid Hormone and Wellness: Help, Hype or Harm?</b> <i>Simon Pearce</i> Chairperson: <i>Yusniza Yusoff</i></p>		
0905 - 0950	<p><b>PLENARY 4: Long-Term Clinical and Psychological Outcomes in DSD</b> <i>Syed Faisal Ahmed</i> Chairperson: <i>Noor Shafina Mohd Nor</i></p>		
0950 - 0955	<p><b>Insights from CDIC</b></p>		
0955 - 1020	<p><b>Best Case Report Presentation (Ballroom C Foyer)</b> <i>Tour d'Central</i> Draw Tea Break / Trade Exhibition + <i>Tour d'MAC</i></p>		
	BALLROOM B	BALLROOM C	CLARKE BALLROOM
1020 - 1150	<p><b>Symposium 7: DIABETES MELLITUS</b> Chairperson: <i>Wan Mohd Izani Wan Mohamed</i></p> <p><i>Screening of Type 1 Diabetes - Related Autoimmunity</i> <i>Jorma Toppari</i></p> <p><i>Deprescribing in Type 2 Diabetes: Who, When, and How</i> <i>Raja Nurazni Raja Azwan</i></p> <p><i>Treatment Options for Lean Prediabetes</i> <i>Mafauzy Mohamed</i></p>	<p><b>Symposium 8: REPRODUCTIVE</b> Chairperson: <i>Elliyin Katiman</i></p> <p><i>From Gut to Ovary: Expanding Role of GLP-RA in PCOS and Women Fertility</i> <i>Nor Shaffinaz Yusoff Azmi</i></p> <p><i>Role of ART in Male Infertility</i> <i>Sarah Mubarak</i></p> <p><i>Low T and the Metabolic Domino Effect</i> <i>See Chee Keong</i></p>	<p><b>Symposium 9: GROWTH AND PUBERTY</b> Chairperson: <i>Tee Pian Pian</i></p> <p><i>Understanding Early Puberty: From Diagnosis to Management</i> <i>Lim Poi Giok</i></p> <p><i>Evaluation and Management of Delayed Puberty in Boys</i> <i>Raja Aimee Raja Abdullah</i></p> <p><i>Advances in the Treatment Strategies in Children with Short Stature</i> <i>Jeanne Wong Sze Lyn</i></p>
1150 - 1230	<p><b>MTE 7: Primary Aldosteronism: Case-Based Updates from the New Guideline</b> <i>Troy Puar</i> Chairperson: <i>Kuan Yueh Chien</i></p>	<p><b>MTE 8: Short and Long-Term Management of Graves' Disease</b> <i>Simon Pearce</i> Chairperson: <i>Yusniza Yusoff</i></p>	<p><b>MTE 9: From Growth Charts to Treatment Decisions in Short Stature</b> <i>Janet Hong</i> Chairperson: <i>Alexis Anand Dass Lordudas</i></p>

## Programme

**23<sup>rd</sup> May 2026, Saturday**

	BALLROOM B	BALLROOM C	CLARKE BALLROOM
1230 - 1330	<p><b>Zuellig Pharma Lunch Symposium</b> Chairperson: <i>Nurain Mohd Noor</i></p> <p><b>ONE Way to See Glucose: Real-Time Insights for Better Decisions</b></p> <p><i>From Monitoring to Meaning: Why Real-Time CGM is Redefining Diabetes Care</i> <i>Lim Lee Ling</i></p> <p><i>Driving Better Outcomes: Real-Time CGM in Paediatric and Type 1 Diabetes</i> <i>Muhammad Yazid Jalaluddin</i></p> <p><i>The Regional Perspective: Lessons From Singapore CGM Adoption</i> <i>Daphne Gardner</i></p> 	<p><b>Novo Nordisk Pharma Lunch Symposium</b> Chairperson: <i>Chan Siew Pheng</i></p> <p><b>Keeping it Real: For Real Results in Obesity Management</b></p> <p><i>Targeting Fat, Preserving Muscle: Quality Weight Loss from the Right Places</i> <i>Jeyakantha Ratnasingam</i></p> <p><i>INFORM: Rewiring Cravings for Better Outcomes</i> <i>Chan Siew Pheng</i></p> <p><i>Decoding the Metabolic Conundrum with Semaglutide: Multiorgan Protection in Obesity</i> <i>Akshay Jain</i></p> 	<p><b>Servier Lunch Symposium</b> Chairperson: <i>Sharifah Faradila</i></p> <p><i>Beyond Either-Or: Gliclazide in Combination Therapies Today</i> <i>Mohamed Hassanein</i></p> <p><i>T2D Decisions in Sustainable Reality: When to Combine, Continue, or Switch with Gliclazide, SGLT2i and GLP-1 RA</i> <i>Chow Yok Wai</i></p> 
1330 - 1400	<p><b>Trade Exhibition + <i>Tour d'MAC</i></b></p>		
1400 - 1440	<p><b>MTE 10: Hypoglycemia Made Simple</b> <i>Lim Kim Piow</i></p>	<p><b>MTE 11: Menopause Care across Spectrum</b> <i>Sonia Davison</i> Chairperson: <i>Elliyin Katiman</i></p>	<p><b>MTE 12: Approach to Hypoglycemia in Infants and Children</b> <i>Suhaimi Hussain</i> Chairperson: <i>Teoh Sze Teik</i></p>
1440 - 1610	<p><b>Symposium 10: PITUITARY</b> Chairperson: <i>Mohamed Badrulnizam Long Bidin</i></p> <p><i>Autoimmune &amp; Immune Checkpoint Inhibitor Induced Hypophysitis</i> <i>Nor Azmi Kamaruddin</i></p> <p><i>Pituitary Dysfunction after TBI</i> <i>Fatimah Zaherah Mohamed Shah</i></p> <p><i>Sellar Crisis: Pituitary Apoplexy</i> <i>Siti Sanaa Wan Azman</i></p>	<p><b>Symposium 11: ENDOCRINE DISORDERS IN PREGNANCY</b> Chairperson: <i>Lim Siang Chin</i></p> <p><i>Use of Diabetes Technology in Pregnancy: Evidence and Practice</i> <i>Norlaila Mustafa</i></p> <p><i>Obesity and Pregnancy: Endocrine Risks and Primary Care Interventions</i> <i>Shireene Ratna Vethakkan</i></p> <p><i>Long-term Metabolic Risk After Gestational Diabetes</i> <i>Nurain Mohd Noor</i></p>	<p><b>Symposium 12: MULTIENDOCRINE CONCERNS</b> Chairperson: <i>Cheng Hooi Peng</i></p> <p><i>Paediatric Hypothyroidism: When and How to Treat?</i> <i>Joyce Hong</i></p> <p><i>Diagnostic Challenges in Paediatric Calcium and Bone Disorders</i> <i>Rashida Farhad Vasanwala</i></p> <p><i>Practical Guide to Assessment and Management of PCOS in Adolescents</i> <i>Nur Azurah Abdul Ghani</i></p>
1610 - 1700	<p><b>HOE Pharmaceuticals (Taisho Pharmaceutical) High-Tea Symposium</b> Chairperson: <i>Alexander Tan</i></p> <p><i>MASLD: The Silent Epidemic – Importance of Screening and Risk Stratification</i> <i>Chan Wah Kheong</i></p> 	<p><b>Boehringer Ingelheim High-Tea Symposium</b> Chairperson: <i>Chan Siew Pheng</i></p> <p><i>The 2026 Shield: Turning Evidence into Action in CKD Care</i> <i>Tan Li Ping</i></p> <p><i>Powerful Catalyst for Early Intensification in Diabetes Care</i> <i>Jeyakantha Ratnasingam</i></p> 	<p><b>Viatrix High-Tea Symposium</b> Chairperson: <i>Zanariah Hussein</i></p> <p><i>Optimizing clinical outcomes in Diabetic Peripheral Neuropathy: From Early Detection to Effective Treatment</i> <i>Lim Lee Ling</i></p> <p><i>Discussion</i> <i>Rohana Abdul Ghani, Lim Lee Ling</i></p> 
	<p><b>Young Investigator Award (Adult)</b> <i>Parry Room</i></p>	<p><b>Young Investigator Award (Paeds)</b> <i>Davidson Room</i></p>	

## Programme

**23<sup>rd</sup> May 2026, Saturday**

**BALLROOM B + C**

1700 - 1930 **MEMS AGM** *exclusively for members only*  
*Clarke Ballroom*

**Trade Exhibition +** *Tour d'MAC*

1900 - 2200 **GlaxoSmithKline Pharmaceutical Dinner Symposium**  
*Chairperson: Chan Siew Pheng*

*Shingles Prevention in 50+ Patients with Cardiovascular Metabolic Conditions*  
*Alexander Tan*




*Managing Shingles Risk in Metabolic Dysregulation: A Patient in Focus*  
*Alexander Tan*

*A Clinical Picture of Shingles Complications in Patients with CRM Co-morbidities*  
*Rosnawati Yahya*

**GSK**

## Programme

24<sup>th</sup> May 2026, Sunday

	BALLROOM B	CLARKE BALLROOM	
0740 - 0820	<p><b>Sun Pharma Sunrise Symposium</b> Chairperson: <i>Subashini Rajoo</i> <i>Navigating T2DM: From SU, DPP-4i to SGLT-2i</i> <i>Chooi Kheng Chiew</i></p> 	<p><b>Zuellig Pharma Sunrise Symposium</b> Chairperson: <i>See Chee Keong</i> <i>Closing the Gap in Acromegaly: Are We Truly in Control?</i> <i>Jeyakantha Ratnasingam</i></p> 	
0820 - 0905	<p><b>PLENARY 5: Beyond Estrogen: Testosterone in Women</b> <i>Sonia Davison</i> Chairperson: <i>Elliyin Katiman</i></p>		
0905-0915	<p><b>Short Break</b></p>		
	BALLROOM B	BALLROOM C	CLARKE BALLROOM
0915 - 1045	<p><b>Symposium 13: NEUROENDOCRINE TUMORS</b> Chairperson: <i>G R Letchuman Ramanathan</i> <i>Functional Imaging in NET: Which to Choose?</i> <i>Boey Ching Yeen</i> <i>Precision Oncology in NET</i> <i>Muthukkumaran Thiagarajan</i> <i>Familial Pheochromocytoma Carrier Surveillance Protocol</i> <i>Zanariah Hussein</i></p>	<p><b>Symposium 14: DIABETES &amp; CV</b> Chairperson: <i>Kang Waye Hann</i> <i>Treat to Target in MASLD</i> <i>Chan Wah Kheong</i> <i>Small Protein, Big Risk</i> <i>Edy Cornelius</i> <i>Timing the Heart in Prediabetes</i> <i>Asri Ranga Abdullah Ramaiah</i></p>	<p><b>Symposium 15: OBESITY IN CHILDREN</b> Chairperson: <i>Ting Tzer Hwu</i> <i>Key Considerations in the Evaluation of Childhood Obesity</i> <i>Nurshadia Samingan</i> <i>Strategies on Dietary Management in Obesity</i> <i>Rokiah Ismail</i> <i>Emerging therapies in Obesity: Beyond Lifestyle Modification</i> <i>Lim Song Hai</i></p>
1045 - 1100	<p><b>Tea Break</b></p>		
1100 - 1145	<p><b>DKSH Symposium</b> <i>Driving Extra Miles in Diabetic Kidney Disease: Navigating Disease Progression and Cardiometabolic Comorbidities</i> <i>Ng Eng Khim</i> <i>Kiran Nair</i></p>		
1145-1150	<p><i>Tour d'MAC</i> Draw</p>		
1150 - 1235	<p><b>DEBATE: Incretin-based Therapies: Friend or Foe</b> <i>Alexander Tan vs Azraai Bahari Nasruddin</i> Moderator: <i>Chan Siew Pheng</i></p>		
1230 - 1300	<p><b>Prize Giving &amp; Closing Ceremony</b></p>		

## Table of Contents

### Adult Oral Presentation

- 1 **OP\_A001**  
**ONE-HOUR OGTT REVEALS WHAT CONVENTIONAL SCREENING MISSES: A HIDDEN PREDIABETES BURDEN IN MALAYSIA**  
Gerard Jason Mathews, Seetha Devi Subramanian, Nor Shaffinaz Yusoff Azmi Merican, Shartiyah Ismail, Joel Mathews, Leng Ean Charis Kong, Chong Hui Khaw, Shubash Shander Ganapathy, Arvinder-Singh HS
- 2 **OP\_A002**  
**OBESITY AND INSULIN THERAPY AS PREDICTORS OF ENDOTHELIAL DYSFUNCTION IN TYPE 2 DIABETES MELLITUS WITH EARLY CKD**  
Nursyahirah Ishak, Nur' Aini Eddy Warman, Rohana Abd Ghani
- 3 **OP\_A003**  
**ISOLATION OF FUNCTIONAL HUMAN LEYDIG CELLS: A DIFFERENTIAL-ADHESION APPROACH WITH MULTI-MODAL PHENOTYPIC AND STEROIDOGENIC VALIDATION**  
Yee Jia Heng, Pooi Pooi Leong, Omar Ahmed Fahmy Ahmed, Waye Hann Kang
- 4 **OP\_A004**  
**WHO SUCCEEDS IN INSULIN DEINTENSIFICATION? REAL-WORLD PREDICTORS AND MODIFIABLE FACTORS FROM PRIMARY CARE**  
Yee Theng Chong, Mohammad Ashwad Muhd Zin, Anisha K. Nijar, Nur Syellawathy Ahmad, Mohd Khairi Mohd Noor, Noorhazliza Abdul Patah, Erleena Nur Hassan, Izwan Effendy Bin Ismail, Najwa Aziz, Min Chiee Leon, Hui Ting Ng, Khairatun Hisan Mohd Napiah, Manothini A/P Perumal, Shih Ling Selene Ng Shih Ling, Ming Hui Liew, Cha Chee Chong
- 5 **OP\_A005**  
**A PROSPECTIVE STUDY IN INSULIN REGIMEN DE-ESCALATION FROM MULTIPLE DAILY INJECTION IN PATIENTS WITH POORLY CONTROLLED TYPE 2 DIABETES MELLITUS**  
Yik Hin Chin, Xun Yi Tiong, Noor Lita Adam, Subashini Rajoo, Chin Voon Tong, Miza Hiriyanti Binti Zakaria, Daanisha Nayar, Sze Wei Lim, Siew Hui Foo
- 6 **OP\_A006**  
**SINGLE-CELL SPATIAL PROFILING REVEALS IMMUNE-STEROIDOGENIC CROSSTALK IN ADRENALS OF PATIENTS WITH PRIMARY ALDOSTERONISM**  
Noorzaileen Eileena Zaidi, Amnani Aminuddin, Aina Nadheera Abd Rahman, Faezah Abdul Latif, Emily Goodchild, Kate Laycock, Eva Wozniak, Charles Mein, Muaatamarulain Mustangin, Nor Adzimah Johdi, Nor Haslinda Abd Aziz, Adli Ali, Azraai Bahari Nasruddin, Miroslav Solar, Troy Puar Hai Kiat, Norlela Sukor, William Drake, Morris Jonathan Brown, Elena Aisha Azizan

## Adult Best Poster Presentation

- 7 **BP\_A001**  
EFFECTIVENESS OF A NEWLY DEVELOPED YOUTUBE DIABETES EDUCATION:  
A MULTICENTRE RANDOMIZED CONTROLLED TRIAL  
Phei Ching Lim, Yi Woei Tang, Jia Hui Cheng, Leong Seng Tan, Hooi Hoon Tan, Chong Hui Khaw
- 8 **BP\_A002**  
EFFECTIVENESS OF DIABETES EDUCATION VIA MOBILE APPLICATION (T-MANIS) IN  
IMPROVING GLYCEMIC CONTROL AMONG PATIENTS WITH TYPE 2 DIABETES  
Tean Chooi Fun, Khaw Chong Hui, Ijaz binti Hallaj Rahmatullah, Lim Phei Ching, Lok Jin Lyn,  
Song Li Bin, Ye Xiaoyan
- 9 **BP\_A003**  
HEREDITARY VERSUS SPORADIC MEDULLARY THYROID CARCINOMA:  
A SINGLE TERTIARY CENTRE COHORT STUDY  
Qin Zhi Lee, Raja Nurazni Raja Azwan, Chin Voon Tong, Zanariah Hussein
- 10 **BP\_A004**  
EFFECTIVENESS OF THE COMPREHENSIVE METABOLIC THERAPY (CoMeT)  
PROGRAMME ON ANTHROPOMETRIC, METABOLIC AND BODY COMPOSITION IN  
ADULTS WITH OBESITY: A PILOT PRE-POST STUDY  
Amie Anne Augustine and Md Syazwan Md Amin
- 11 **BP\_A005**  
THE ROLE OF FREE TRIIODOTHYRONINE TO FREE THYROXINE RATIO IN THE  
DIFFERENTIAL DIAGNOSIS OF THYROTOXICOSIS: A CROSS-SECTIONAL STUDY  
Menon Saiechwaran, Sy Liang Yong, Vijiya Mala Velayutham, Jason Tan Seng Hong, Avni Patel,  
Zienna Zufida binti Zainol Rashid, Hanisah Abdul Hamid, Salbiah binti Mohd Isa, Li Vern Lim
- 12 **BP\_A006**  
REAL-WORLD USE OF TOLVAPTAN IN HYPONATREMIA: A SINGLE-CENTRE  
EXPERIENCE  
Fei Bing Yong, Nur Hidayah Mohd Makhatar, Siew Wai Shuit, Shamharini Nagaratnam,  
Zanariah Hussein

## Adult Best Case Report Presentation

- 13 **BC\_A001**  
46 XY GONADAL DYSGENESIS MIMICKING TURNER SYNDROME: DIAGNOSTIC CHALLENGES AND CLINICAL IMPLICATIONS  
Suseelah Bala Subramaniam, Rabeah Md Zuki, Loh Hoong Heng
- 14 **BC\_A002**  
DIVERGENT OUTCOMES OF RESCUE THERAPEUTIC PLASMA EXCHANGE IN REFRACTORY THYROID STORM: A CASE SERIES  
Mas Suria Mat Daud, Teh Roseleen Nadia Roslan, Marisa Khatijah Borhan, Norhayati Yahaya
- 15 **BC\_A003**  
SOLVING THE UNLOCALIZED PARATHYROID: EXPERIENCE WITH SELECTIVE VENOUS SAMPLING IN THREE PATIENTS  
Yee Weai Cheong, Hwee Ching Tee, Ho Jin Hui, Shireen Siow Leng Lui, Aida Shazlin Binti Hamiddin, Siti Zubaidah Sharif
- 16 **BC\_A004**  
SUPRASELLAR MOGAD: RARE ENDOCRINE MANIFESTATIONS OF HYPOPITUITARISM AND DIABETES INSIPIDUS  
Sing Yee Sim
- 17 **BC\_A005**  
PITUITARY-DRIVEN GONADAL HYPERSTIMULATION: A RARE PRESENTATION OF FUNCTIONING GONADOTROPH ADENOMA  
Nurbadriah Jasmiad, Wei Wei Ng, Anilah Abdul Rahim, Ijaz Hallaj Rahmatullah
- 18 **BC\_A006**  
PROTEINURIA AND HYPOTHYROIDISM: TWO CASES ILLUSTRATING A BIDIRECTIONAL THYROID-KIDNEY RELATIONSHIP  
Manoharan Thunisha and Yueh Chien Kuan

## Adult E-Poster

- 19 **EP\_A002**  
EVALUATION OF MORNING CORTISOL IN DIAGNOSIS AND MANAGEMENT OF ADRENAL INSUFFICIENCY IN A TERTIARY HOSPITAL IN CENTRAL PAHANG  
Saravanaa Nalliah and See Chee Keong
- 19 **EP\_A003**  
PRIMARY ALDOSTERONISM IN A MALAYSIAN TERTIARY CENTRE: A RETROSPECTIVE AUDIT OF CLINICAL CHARACTERISTICS, DIAGNOSTIC PATHWAYS, AND TREATMENT OUTCOMES (2018–2025)  
Ahmad Hambal Bin Zamari and Yusniza Yusoff
- 20 **EP\_A004**  
SINGLE-STAGE ADRENALECTOMY AND HYSTERECTOMY FOR PHEOCHROMOCYTOMA WITH GIANT UTERINE FIBROID: A MULTIDISCIPLINARY PERIOPERATIVE CHALLENGE  
Fei Bing Yong, Sarojini Devi Simanchalam, Hidayatil Alimi Keya Nordin, Nithiya Devi Kandasami, Sadhana Sadar Mahamad, Suhaimi Jaafar, Mohd Wajdi Zanuddin, Poh Shean Wong, Chin Voon Tong, Noor Lita Adam, Zanariah Hussein
- 20 **EP\_A005**  
MIMICKING PHEOCHROMOCYTOMA: HYPERTENSIVE CRISIS FROM ADRENAL HEMATOMA IN JAK2-POSITIVE POLYCYTHEMIA RUBRA VERA  
Dhanya Ganesan, Hwee Ching Tee, Jin Hui Ho, Shireen Siow Leng Lui
- 21 **EP\_A006**  
TWO HEARTBEATS, ONE TUMOR: NON-FUNCTIONING ADRENOCORTICAL TUMOR IN PREGNANCY  
Nur Nisrina Yahya and Noor Rafhati Adyani Abdullah
- 22 **EP\_A007**  
WHEN NSTEMI IS NOT CORONARY DISEASE: MINOCA REVEALING PHEOCHROMOCYTOMA  
Shaleela Mohd Esha, Hazwani Aziz, Elliyyin Katiman
- 22 **EP\_A008**  
THE DOPAMINE DILEMMA: EXOGENOUS L-DOPA OR RARE DOPAMINOMA?  
Amal Hanani Abdul Halim and Farhi Ain Jamaluddin
- 23 **EP\_A009**  
THE HEMODYNAMIC PARADOX: SYNCHRONOUS ROBOTIC SURGERY FOR NORMOTENSIVE PHEOCHROMOCYTOMA IN VHL  
Thiru Murugaan Balakrishnan, Nurbadriah Jasmiad, Ng Wei Wei, Anilah Abdul Rahim, Ijaz Hallaj Rahmatullah, Subashini Rajoo
- 23 **EP\_A010**  
DISSEMINATED HISTOPLASMOSIS PRESENTING AS ADDISONIAN CRISIS: A DIAGNOSTIC MIMIC OF TUBERCULOSIS WITH BILATERAL ADRENAL MASSES  
Aminuddin Baki Amran, Nur Aini Eddy Warman, Aimi Fadilah Mohamad, Nur Haziqah Baharum, Mohd Hazriq Awang, Fatimah Zaherah Mohamed Shah, Rohana Abdul Ghani

- 24 **EP\_A011**  
**LARGE “GROWING” ADRENAL MASS WITH AN UNEXPECTED HISTOLOGY**  
Ling Hui Kiu, Ee Wen Loh, Pei Lin Chan, Florence Hui Sieng Tan
- 24 **EP\_A012**  
**SILENT ADRENAL MASS WITH DIAGNOSTIC CHALLENGE: A CASE OF HUGE NON-FUNCTIONING ADRENAL LESION MIMICKING MALIGNANCY**  
Sarojini Devi Simanchalam, Hamizah Hamzah, Lee Qin Zhi, Poh Shean Wong, Chin Voon Tong, Tiang Koi Ng, Nor Afidah Karim, Noor Lita Adam
- 25 **EP\_A013**  
**A DIAGNOSTIC TRAP: ECTOPIC ACTH CUSHING SYNDROME WITH INCIDENTAL PITUITARY MICROADENOMA**  
Khai Seong Khor, Ying Jie Tan, Lay Ang Lim
- 26 **EP\_A014**  
**BILATERAL ADRENAL MASSES WITH RAPID DETERIORATION: A RARE CASE OF PRIMARY ADRENAL LYMPHOMA**  
Melody Tsen Shu Ling, Cheong Yee Weai, Hwee Ching Tee, Jin Hui Ho, Shireen Siow Leng Lui
- 26 **EP\_A015**  
**METASTATIC MALIGNANT PHEOCHROMOCYTOMA DRIVEN BY DNMT3A SOMATIC MUTATION**  
Vijayrama Rao Sambamoorthy, Zanariah Hussein, Anthony Louis Kindu
- 27 **EP\_A016**  
**CONGENITAL ADRENAL HYPERPLASIA WITH HYPOGONADISM IN A MAN: 3 $\beta$ -HYDROXYSTEROID DEHYDROGENASE DEFICIENCY VS. LIPOID HYPERPLASIA?**  
Marisa Masera Marzukie, Quan Hziung Lim, Shireene Ratna Vethakkan, Jeyakantha Ratnasingam
- 28 **EP\_A017**  
**METASTASIS OR MIMIC? NAVIGATING THE WORKUP OF A LARGE ADRENAL INCIDENTALOMA IN THE SETTING OF LUNG CANCER**  
Mohd Firdaus Mohamad Kamil, Masliza Hanuni Mohd Ali, Wan Mohd Hafez Wan Hamzah
- 28 **EP\_A018**  
**A HIDDEN DIAGNOSIS: DISSEMINATED HISTOPLASMOSIS MIMICKING TUBERCULOSIS IN THE ELDERLY**  
Wan Muhamad Amir Wan Md Zin, Moon Yan Yap, Meroshini Sundaran, Siti Nabilah ‘Atiqah Othman, Siti Nabihah Mohamed Hatta, Maz Anirah Abdul Azis
- 28 **EP\_A019**  
**OVERWHELMING OPPORTUNISTIC INFECTIONS AS THE INITIAL PRESENTATION OF SEVERE CUSHING SYNDROME**  
Kirthene Gopal, Ooi Chuan Ng, Yee Lin Lee
- 29 **EP\_A020**  
**BEYOND HYPONATREMIA: UNMASKING ADDISON’S DISEASE**  
Aminath Naqsha, Ilham Ismail, Mahrunissa Mahadi, Yik Hin Chin, K.J. Lingeswary Krishnan, Norlaila Mustafa, Norasyikin A.Wahab
- 30 **EP\_A021**  
**WHEN TISSUE IS THE ISSUE: PRESUMPTIVE DIAGNOSIS AND TREATMENT OF BILATERAL ADRENAL TUBERCULOSIS**  
Norul Ain Mat Seman, Maslina Hanuni MA, Wan Hafez Wan Hamzah

- 30 **EP\_A022**  
**BEYOND MITOTANE IN A PATIENT WITH HIGHLY AGGRESSIVE ADRENOCORTICAL CARCINOMA**  
Muhammad Shukri Johar, Siti Sanaa Wan Azman, Dorothy Maria Anthony Bernard, Foo Siew Hui
- 31 **EP\_A023**  
**WHEN CORTISOL OVERWHELMS THE HEART: A FATAL CASE OF METASTATIC ADRENOCORTICAL CARCINOMA PRESENTING AS ACUTE HEART FAILURE**  
Tze Liang Lee, Shaleni Nagappen, Deviga Latchumanan
- 31 **EP\_A024**  
**SOLITARY PROGRESSION TO BONE: A RARE MANIFESTATION OF ADRENOCORTICAL CARCINOMA**  
Mohd Fyzal Bahrudin, Jia Miao Tan, Chin Voon Tong
- 32 **EP\_A025**  
**CONUNDRUM IN THE MANAGEMENT OF A RARE CAUSE OF CUSHING SYNDROME**  
Wee Mee Cheng, Lit Sin Yong, Poh Shean Wong, Nor Afidah binti Karim, Noor Lita Adam
- 32 **EP\_A026**  
**SYNERGIZING ARTIFICIAL INTELLIGENCE WITH CLINICIANS' EXPERTISE: TOWARDS PERSONALIZED PROACTIVE DIABETES CARE IN MALAYSIAN PRIMARY HEALTH CLINICS**  
Sindeh Woweham, Mohd Nazri Mohd Daud, George George Mathew, Hazwani Hanum Hashim, Khairun'naim Khairuddin
- 33 **EP\_A027**  
**PREVALENCE OF DIABETIC PERIPHERAL NEUROPATHY AND ITS ASSOCIATION WITH SERUM NEURON-SPECIFIC ENOLASE AMONG TYPE 2 DIABETES MELLITUS PATIENTS**  
Siti Kaamilah Mohd Zin, Fatimah Zaherah Mohamed Shah, Nor Amelia Mohd Fauzi, Rohana Abdul Ghani, Nur 'Aini Eddy Warman
- 33 **EP\_A028**  
**RECURRENT DIABETIC KETOACIDOSIS: PREDICTORS AND CLINICAL OUTCOMES IN A 24-YEAR RETROSPECTIVE COHORT**  
Liang Wei Wong, Lisa Mohamed Nor, Raja Nurazni binti Raja Azwan, Adilah Zulaikha binti Abd Latib, Hidayatil Alimi bin Keya Nordin, Qin Zhi Lee, Kean Heng Lim, Jia Ling Low, Mohd Fyzal bin Bahrudin, Syaza binti Izhar Hisham, Jia Whey Jacelyn Ong, Chin Voon Tong
- 34 **EP\_A029**  
**CLINICAL UTILITY OF MODIFIED ASIAN FINDRISC AND RANDOM CAPILLARY BLOOD GLUCOSE FOR THE DETECTION OF DYSGLYCEMIA IN THE ADULT POPULATION**  
Jie En Tan, Nor Shaffinaz Yusoff Azmi Merican, Florence Hui Sieng Tan
- 35 **EP\_A030**  
**UNDERSTANDING DIABETES LITERACY IN SEREMBAN: PREDICTIVE FACTORS AND CLINICAL IMPLICATIONS**  
Wee Mee Cheng, Nadiyah Aminah Azizan, Wan Farahiyah Wan Muhmad, Aun Aun Chua, Poh Shean Wong, Lit Sin Yong, Nor Afidah Karim, Noor Lita Adam
- 35 **EP\_A031**  
**ORAL ALPHA-LIPOIC ACID, VITAMIN B COMPLEX, AND VITAMIN E COMBINATION (BIONERV E+) FOR TREATING SYMPTOMATIC DISTAL SENSORY POLYNEUROPATHY: INTERIM ANALYSIS OF A RANDOMIZED, PLACEBO-CONTROLLED TRIAL**  
Fathimath Shazoo, Ilham Ismail, Rathika Rajah, Wan Asyraf Wan Zaidi, Rabani Remli, Mahrunissa Mahadi, Norlaila Mustafa, Roszita Ibrahim, Norasyikin A. Wahab

- 36 **EP\_A032**  
**EFFICACY AND SAFETY OF SGLT2 INHIBITORS IN ELDERLY ( $\geq 75$  YEARS) WITH TYPE 2 DIABETES: A REAL-WORLD STUDY**  
Siew Wai Shuit, Shamharini Nagaratnam, Fei Bing Yong, Norisha Nandini Passkaren, Keen Tien Boey, Nur Syahirah Asarapoo, Sathya Rajagopal, Vikanesa Mahalingam, Zanariah Hussein
- 36 **EP\_A033**  
**EXTREME GLYCEMIC SEVERITY AND MORTALITY RISK IN THE TB-DM CO-PANDEMIC: A RETROSPECTIVE ANALYSIS OF CLINICAL OUTCOMES**  
Mohammad Ulilamri Tukiman, Chitra Devi Subramaniam, Yusniza Yusoff, Mohammad Nur Syafiq Mohamad Azman, Choo Jia Qing
- 37 **EP\_A034**  
**IMPACT OF GLYCEMIC CONTROL ON TUBERCULOSIS TREATMENT OUTCOMES IN PATIENTS WITH DIABETES MELLITUS: A RETROSPECTIVE AUDIT**  
Chitra Devi Balasubramaniam, Mohammad Ulilamri Tukiman, Yusniza Yusoff, Mohammad Nur Syafiq Mohammad Azman, Choo Jia Qing
- 38 **EP\_A035**  
**RISK STRATIFICATION AND REFERRAL PATTERNS FOR METABOLIC LIVER DISEASE IN TYPE 2 DIABETES: REAL-WORLD FIB-4 UTILIZATION**  
Calven Fu Hao Lim, Min Chow, Jess Jie Ying Ng
- 38 **EP\_A036**  
**REAL-WORLD CLINICAL EXPERIENCE OF SUBCUTANEOUS SEMAGLUTIDE IN PUBLIC HOSPITAL-BASED DIABETES CARE: A RETROSPECTIVE OBSERVATIONAL STUDY**  
Zanariah Hussein, Navin Kumar Loganadan, Subashini Rajoo
- 39 **EP\_A037**  
**IMPACT OF GLYCEMIC BURDEN ON RENAL FILTRATION DECLINE AND PROTEINURIA IN TYPE 1 DIABETES MELLITUS**  
Sian Lin Toh, Chee Keong See, Wei Hong Chin
- 39 **EP\_A038**  
**CLINICAL AND BIOCHEMICAL CHARACTERISTICS OF ADULT DIABETIC KETOACIDOSIS: T1DM VS T2DM**  
Mohd Fyzal Bahrudin, Chin Voon Tong, Raja Nurazni Raja Azwan, Adilah Zulaikha Abd Latib, Hidayatil Alimi Keya Nordin, Qin Zhi Lee, Kean Heng Lim, Jia Ling Low, Syaza Izhar Hisham, Liang Wei Wong, Jia Whey Jacelyn Ong, Lisa Mohamed Nor, Zanariah Hussein
- 40 **EP\_A039**  
**HIDDEN BURDEN OF DIABETES RISK AMONG HEALTHCARE WORKERS IN A TERTIARY HOSPITAL**  
Hui Soon Lim, Ee Wen Loh, Sing Yee Sim, Pei Lin Chan, Florence Hui Sieng Tan
- 41 **EP\_A040**  
**EFFECTIVENESS OF INSULIN DEINTENSIFICATION AND PREDICTORS OF GLYCEMIC CONTROL IN POORLY CONTROLLED TYPE 2 DIABETES MELLITUS: A RETROSPECTIVE COHORT STUDY IN MALAYSIAN PRIMARY CARE**  
Anuar Mohamad, Mohd Ali 'Imran Ab Rahaman, Ping Foo Wong, Mohammad Zainie Hassan, Miguelinda Vitus Kimsin, Hiang Ngee Chan, Megat Muhammad Haris Megat Zainal

- 41 **EP\_A041**  
**IMPACT OF A RAPID OPTIMIZATION CLINIC ON GLYCEMIC CONTROL AND INSULIN DEINTENSIFICATION IN PATIENTS WITH DIABETES: AN EARLY RETROSPECTIVE AUDIT**  
Pang Hoy Yan, Varuna Shashti Dhevi Marimuthu, Amir Ridzwan Maula Mohd Nasir, Muhammad Firdaus Ghani, Chen Chiew Yee, Hidayatil Alimi Keya Nordin, Elliyyin Katiman
- 42 **EP\_A042**  
**RISK ASSESSMENT FOR RAMADAN FASTING IN PEOPLE WITH DIABETES IN HOSPITAL-BASED DIABETES CLINICS USING THE UPDATED 2026 IDF-DAR RISK CALCULATOR**  
Raja Nurazni Raja Azwan, Chin Voon Tong, Lisa Mohamed Nor, Marisa Khatijah Borhan, Syarifah Syahirah Syed Abas, Poh Shean Wong, Ying Jie Tan, Shartiyah Ismail, Eunice Yi Chwen Lau, Yueh Chien Kuan, Noor Hafis Md Tob, Shu Teng Chai, Pei Lin Chan, Xe Hui Lee, Wei Wei Ng, Jin Hui Ho, Miza Hiriyanti Zakaria, Rabeah Md Zuki, Wan Mohd Hafez Wan Hamzah, Melissa Vergis, Choon Peng Sun, Vanusha Devaraja Pillai, Chee Koon Low, Shazatul Reza Mohd Redzuan, Xin-Yi Ooi, Siti Sanaa Wan Azman, Deviga Lachumanan, Saiful Shahrizal Shudim, Zanariah Hussein
- 43 **EP\_A043**  
**EFFECTIVENESS OF ORAL SEMAGLUTIDE VERSUS INJECTABLE DULAGLUTIDE IN ADULTS WITH TYPE 2 DIABETES AND OBESITY: A SINGLE-CENTRE EXPERIENCE**  
Nur Shairah Binti Mohamad Fazial, Raja Yunalis Binti Raja Iskandar, Nur Syuhaida Binti Noorazam, Saiful Shahrizal Bin Shudim
- 44 **EP\_A044**  
**GLYCEMIC AND METABOLIC OUTCOMES OF GLP-1 RECEPTOR AGONISTS IN TYPE 2 DIABETES: A SINGLE-CENTRE CLINICAL AUDIT**  
Shinye Eng and Rabeah Md Zuki
- 44 **EP\_A045**  
**A CLINICAL AUDIT OF DIABETIC RETINOPATHY SCREENING AMONG TYPE 2 DIABETES MELLITUS PATIENTS ATTENDING PUSAT PERUBATAN ANGKATAN TENTERA, SG BESI**  
Maizatullifah Miskan, Hasliza Abu Hassan, Ng Kien Keat, Ambigga Devi, Aida Jaffar, Siti Salmiah Awang
- 45 **EP\_A046**  
**PREVALENCE OF THYROID DYSFUNCTION IN TYPE 2 DIABETES MELLITUS AND ITS ASSOCIATION WITH BODY FAT MASS INDEX**  
Nabilah Farhana Hamidi, Nur Aini Eddy Warman, Rohana Abdul Ghani, Xin Wee Chen
- 45 **EP\_A047**  
**REAL-WORLD CONTINUOUS GLUCOSE MONITORING PATTERNS IN MALAYSIAN ADULTS WITH TYPE 2 DIABETES: A SINGLE-CENTRE STUDY**  
Ryan Jia Xian Koh, Siti Nabilah Atiqah Othman, Maszariffah Mashor, Azni Abdul Latif, Ooi Chuan Ng
- 46 **EP\_A048**  
**EUGLYCEMIC DIABETIC KETOACIDOSIS: CLINICAL INSIGHTS FROM A TERTIARY-CENTRE COHORT**  
Jia Ling Loh, Chin Voon Tong, Lisa Mohamed Nor
- 46 **EP\_A049**  
**AUDIT OF STAFF KNOWLEDGE OF HYPOGLYCEMIA MANAGEMENT IN A DISTRICT HOSPITAL**  
Hong Lee Hoong, Low Chee Koon, Abdullah Shamshir Abd Mokti

- 47 **EP\_A050**  
**AUDIT ON HbA1c TEST UTILIZATION AT HOSPITAL TELUK INTAN IN 2025**  
Sun Choon Peng, Syazana Jan Shari, Maisara Idris
- 47 **EP\_A051**  
**GLOBAL DIAGNOSTIC CRITERIA FOR GESTATIONAL DIABETES MELLITUS:  
A SCOPING REVIEW PROTOCOL TO INFORM POLICY IN MALAYSIA**  
Siti Sarah Hamzah, Shazana Rifham Abdullah, Nur Zati Iwani Ahmad Kamil, Liyana Ahmad Zamri,  
Nur Azlin Zainal Abidin, Sharifah Nortasya Sayed Muhamad Kamarudin
- 48 **EP\_A052**  
**SURVEY OF AWARENESS OF ARTIFICIAL INTELLIGENCE IN DIABETES CARE AMONG  
ENDOCRINOLOGISTS IN MALAYSIA**  
Jia Miin Sun and Chee Keong See
- 48 **EP\_A053**  
**DIABETIC KETOACIDOSIS IN PREGNANCY: CLINICAL TRIGGERS, OUTCOMES, AND  
MISSED OPPORTUNITIES—A CASE SERIES**  
Jia Whey Jacelyn Ong, Chin Voon Tong, Raja Nurazni binti Raja Azwan, Adilah Zulaikha binti Abd Latib,  
Hidayatil Alimi bin Keya Nordin, Qin Zhi Lee, Kean Heng Lim, Jia Ling Low, Mohd Fyzal bin Bahrudin,  
Syaza binti Izhar Hisham, Liang Wei Wong, Lisa Mohamed Nor, Nurain Mohd Noor
- 49 **EP\_A055**  
**THE PRICE OF POOR GLYCEMIC CONTROL BEFORE AND DURING PREGNANCY:  
GESTATIONAL HYPERTRIGLYCERIDEMIA**  
Pei Shin Lee, Poh Shean Wong, Fauzi Azizan Bin Hj Abdul Aziz
- 50 **EP\_A056**  
**TOO LOW FROM A SELF-BLOW: DIAGNOSTIC AND THERAPEUTIC CHALLENGES IN A  
CASE OF HIRATA'S SYNDROME**  
Tharsini Sarvanandan, Ying Guat Ooi, Jun Kit Khoo, Tricia Lopez, Nicholas Ken Yoong Hee,  
Shireene Vethakkan, Lee-Ling Lim, Jeyakantha Ratnasingam, Carolyn Chee, Pavai Sthaneshwar,  
Quan Hziung Lim
- 50 **EP\_A057**  
**NOT JUST ANOTHER CASE OF TYPE 2 DIABETES IN AN ADOLESCENT**  
Aminuddin Ab Rahman, Nga Xhi Wen Daniel, Noor Hafis Md Tob, Yong Siang Ng, Norhaliza Mohd Ali
- 51 **EP\_A058**  
**INSULIN-RECALCITRANT HYPERGLYCEMIA FOLLOWING CAPIVASERTIB THERAPY:  
A NOVEL CHALLENGE IN A NON-DIABETIC PATIENT**  
Jun Yang Tan and Waye Hann Kang
- 51 **EP\_A059**  
**THE VARIABLE NATURE OF BIOPSY-PROVEN VILDAGLIPTIN-INDUCED BULLOUS  
PEMPHIGOID IN AN ELDERLY PATIENT: A CASE SERIES**  
Mohd Fyzal Bahrudin, Chin Voon Tong, Raja Nurazni Raja Azwan, Hazleen Zainal, Zanariah Hussein
- 52 **EP\_A060**  
**FLUCONAZOLE-INDUCED REFRACTORY HYPOGLYCEMIA IN GLICLAZIDE THERAPY:  
A PREVENTABLE INTERACTION**  
Abdul Rahman Ismail and Nur Aini Eddy Warman

- 52 **EP\_A061**  
**THE HIDDEN RISK OF A FIRST-LINE THERAPY: RENAL ABSCESS WITH SGLT2 INHIBITOR USE**  
Wei Ton Wong, Khairi Syazwan Rashid, Afiq Hazim Ab Rahim
- 53 **EP\_A062**  
**DIVERGENT CLINICAL MANIFESTATIONS OF SEVERE HYPERTRIGLYCERIDEMIA: A CASE SERIES**  
Shinye Eng and Rabeah Md Zuki
- 53 **EP\_A063**  
**EXPANDING THE CLINICAL SPECTRUM OF MULTIPLE AUTOIMMUNE SYNDROME TYPE 3: A CASE SERIES OF OVERLAPPING ENDOCRINE AND SYSTEMIC AUTOIMMUNE DISEASES IN YOUNG ADULTS**  
Yanne Pradwi Efendi, Alexander Kam, Dinda Aprilia, Eva Decroli, Syafril Syahbuddin, Athari Fadhila
- 54 **EP\_A064**  
**A RARE DIAGNOSIS OF INSULIN AUTOIMMUNE SYNDROME CAUSING RECURRENT HYPOGLYCEMIA**  
Ju Vern Ew, Jia En Chew, Eunice Lau Yi Chwen
- 55 **EP\_A065**  
**A UNIQUE FAMILIAL CLUSTER OF TYPE 1 DIABETES: CLINICAL COURSE AND TREATMENT CONSIDERATION**  
Kian Guan Goh
- 55 **EP\_A066**  
**INDIVIDUALIZING THERAPY WITH REPAGLINIDE: A SINGLE-CENTRE EXPERIENCE**  
Ioanna Ting Yung Sim, Florence Hui Sieng Tan, Pei Lin Chan, Ee Wen Loh
- 56 **EP\_A067**  
**SUBARACHNOID HEMORRHAGE: A RARE BUT DEVASTATING COMPLICATION OF DIABETIC KETOACIDOSIS**  
Hui Min Tan, Mohd Irfan bin Moktar, Hwee Ching Tee
- 56 **EP\_A068**  
**ASSOCIATION OF TESTOSTERONE WITH INSULIN RESISTANCE AND BETA-CELL FUNCTION IN TYPE 2 DIABETES MELLITUS**  
Khoirun Mukhsinin Putra, Yulianto Kusnadi, Ratna Maila Dewi, Alwi Shahab
- 57 **EP\_A069**  
**WHOLE-BODY PHASE ANGLE AS A MARKER OF CELLULAR HEALTH IN A WORKPLACE LIFESTYLE INTERVENTION**  
Mohd Nahar Azmi Bin Mohamed and Nurul Zfarina Binti Mohd Zaid
- 57 **EP\_A070**  
**INTEGRATING BODY COMPOSITION AND BIOCHEMICAL MARKERS FOR METABOLIC RISK STRATIFICATION IN LIFESTYLE INTERVENTION**  
Mohd Nahar Azmi Bin Mohamed, Nor Zurina Zainol, Ng Ai Kah
- 58 **EP\_A071**  
**BEYOND BODY WEIGHT: BODY COMPOSITION AND CELLULAR HEALTH IN A WORKPLACE OBESITY INTERVENTION PROGRAMME**  
Mohd Nahar Azmi Bin Mohamed and Nurul Zfarina Binti Mohd Zaid

- 58 **EP\_A072**  
**BLOOD PRESSURE IMPROVES AFTER BARIATRIC SURGERY ACROSS PATIENT SUBGROUPS**  
Liyana Ahmad Zamri, Nur Azlin Zainal Abidin, Farah Huda Mohkiar, You Zhuan Tan, Fazliana Mansor, Yue Tsen Poh, Shu Yu Lim, Gee Tikfu
- 59 **EP\_A073**  
**A SINGLE-CENTRE MALAYSIAN COHORT STUDY ON PREDICTORS OF GLYCEMIC IMPROVEMENT 12 MONTHS AFTER BARIATRIC SURGERY**  
Anis Amalina Mohd Nadzri, Mohd Shazli Draman, Haron Ahmad
- 59 **EP\_A074**  
**REAL-WORLD EFFECTIVENESS OF SEMAGLUTIDE IN ADULTS WITH OBESITY AND TYPE 2 DIABETES IN A MALAYSIAN DISTRICT HOSPITAL**  
Shaleela Mohd Esha, Hazwani Aziz, Elliyyin Katiman
- 60 **EP\_A075**  
**EFFECTIVENESS OF GLP-1 RECEPTOR AGONISTS ON WEIGHT LOSS IN MALAYSIAN PATIENTS WITH TYPE 2 DIABETES**  
Noor Hafizah Ab Hamid, Mohammad Zulkarnain Bidin, Ooi Chuan Ng
- 61 **EP\_A076**  
**DETERMINANTS OF POLYCYSTIC OVARIAN SYNDROME AMONG ADOLESCENTS WITH OVERWEIGHT AND OBESITY: A CASE-CONTROL STUDY PROTOCOL**  
Shazana Rifham Abdullah, Nur Zati Iwani Ahmad Kamil, Siti Sarah Hamzah, Norhashimah Abu Seman, Farah Huda Mohkiar, Nur Azlin Zainal Abidin, Ezarul Faradianna Lokman, Azahadi Omar, Liyana Ahmad Zamri, Fatin Saparuddin, Syarifah Nortasya Sayed Muhamad Kamarudin, Puteri Sofia Nadira Megat Kamaruddin, B. Vimala A/P R.M.T. Balasubramaniam, Fazliana Mansor, Nur Azurah Abdul Ghani, Abqariyah Yahya, Rahima Dahlan @ Mohd Shafie, Ahmad Ali Zainuddin, Kimberly Yui Y'ng Wong, Janet Yeow Hua Hong, Nik Sumayyah Nik Mhd Nor, Mohd Fairulnizal Md Noh, Muhammad Yazid Jalaludin
- 61 **EP\_A077**  
**BASELINE PHYSICAL ACTIVITY ENHANCES GLP-1 RECEPTOR AGONIST WEIGHT LOSS IN OBESE MALAYSIAN PATIENTS WITH T2DM**  
Noor Hafizah Ab Hamid, Mohammad Zulkarnain Bidin, Ooi Chuan Ng
- 62 **EP\_A078**  
**GRAY-MARKET PEPTIDES, GRAVE CONSEQUENCES: SADDLE PULMONARY EMBOLISM AND DIABETIC KETOACIDOSIS FROM UNSUPERVISED RETATRUTIDE, AOD-9604, AND TESAMORELIN**  
Wan Zulhafizaini Bin Wan Jusoh and Md Syazwan Bin Md Amin
- 62 **EP\_A079**  
**POST-BARIATRIC METABOLIC EMERGENCY: A CASE OF DKA IN A NON-INSULIN-DEPENDENT PATIENT**  
Izzah Zafirah Jusoh, M.K. Mohd Firdaus, W.H. Wan Mohd Hafez, M.A. Masliza Hanuni
- 63 **EP\_A080**  
**STARVATION KETOACIDOSIS SECONDARY TO RETATRUTIDE-INDUCED GASTROPARESIS: A CASE REPORT**  
Shinye Eng and Rabeah Md Zuki

- 64 **EP\_A081**  
**ADRENAL SUPPRESSION DURING BIOLOGIC-FACILITATED STEROID TAPERING IN SEVERE ASTHMA: A REAL-WORLD TERTIARY-CENTRE EXPERIENCE**  
Sean Yi Xian Tay, Travers Brian Ramadass, Sakshi Malik, Shoaib Faruqi
- 64 **EP\_A082**  
**METASTATIC EXTRA-OVARIAN STEROID CELL TUMOR PRESENTING WITH HYPERANDROGENISM AND TRANSAMINITIS POST OOPHORECTOMY**  
Preeya Subramaniam, Vanusha Devaraja, Goh Qing Ci, Patricia Lee Siow Ping
- 65 **EP\_A083**  
**SEVERE HYPERTRIGLYCERIDEMIA-INDUCED ACUTE PANCREATITIS IN PREGNANCY: A CASE REPORT AND REVIEW OF MANAGEMENT**  
Shaleela Mohd Esha, Chua Yi Jiang, Wong Hui Chin, Ooi Xin Yi, Yong Sy Liang
- 65 **EP\_A084**  
**SEVERE PREMATURE CORONARY ARTERY DISEASE IN HOMOZYGOUS FAMILIAL HYPERCHOLESTEROLEMIA WITH MARKED LIPID REDUCTION AFTER INCLISIRAN THERAPY**  
Shaleela Mohd Esha, Hazwani Aziz, Elliyyin Katiman
- 66 **EP\_A085**  
**CONCURRENT DIABETIC KETOACIDOSIS AND THYROID STORM IN LATE PREGNANCY: A RARE DUAL ENDOCRINE EMERGENCY**  
Sarojini Devi Simanchalam, Wong Poh Shean, Noor Lita Adam, Lee Pei Shin, Fauzi Azizan
- 66 **EP\_A086**  
**EXTRA-ADRENAL AND UNEXPECTED: A RARE CASE OF PRIMARY RETROPERITONEAL PARAGANGLIOMA**  
Raja Nurul Azafirah Raja Amir Shah, Masliza Hanuni Mohd Ali, Wan Mohd Hafez Wan Hamzah, Nor Hisham M
- 67 **EP\_A087**  
**WARBURG EFFECT-ASSOCIATED NON-INSULIN-MEDIATED HYPOGLYCEMIA IN CHRONIC INFECTION**  
Tilagamaty Murthy, Sharifah Noor Adrilla Long Mohd Noor Affendi, Shazatul Reza Mohd Redzuan, Gayathri Devi Krishnan, Subashini Rajoo
- 67 **EP\_A088**  
**WHEN HYPOGLYCEMIA SPEAKS LOUDER THAN THE CHEST: A DECADE-LATE RECURRENCE OF IGF-2-MEDIATED NON-ISLET CELL TUMOR HYPOGLYCEMIA**  
Li Li Kwan and Deviga Lachumanan
- 68 **EP\_A089**  
**MATERNAL HYPOGLYCEMIA WITH LARGE UTERINE FIBROID AND PARADOXICAL FETAL OVERGROWTH: PLAUSIBLE MECHANISMS**  
Jayaseelan Sekaran, Vickneswaran Marathamuthu, Ooi Chuan Ng
- 69 **EP\_A090**  
**OSTEOPOROSIS TREATMENT PRESCRIPTION IN VERY HIGH-RISK FRACTURE POPULATION: A SINGLE-CENTRE EXPERIENCE**  
Victoria Wei Fang Boey, Hwee Ching Tee, Jin Hui Ho

- 69 **EP\_A091**  
**REDEFINING DEFINITIVE THERAPY: PERCUTANEOUS ETHANOL ABLATION FOR PRIMARY HYPERPARATHYROIDISM IN A NONSURGICAL CANDIDATE**  
Thunissa Manoharan, Yueh Chien Kuan, Pei Lin Chan, Whilmore John, Dhayal Balakrishnan
- 70 **EP\_A092**  
**EXPANDING THE SPECTRUM OF VITAMIN D-DEPENDENT RICKET TYPE 2: DOMINANT-NEGATIVE VDR MUTATION AND POSTPUBERTAL CALCIUM ADAPTATION**  
Mohd Hazriq Awang, Shireene Ratna Vethakkan, Ooi Ying Guat, Tharsini Sarvanandan
- 70 **EP\_A093**  
**GIANT PARATHYROID ADENOMA WITH DELAYED HUNGRY BONE SYNDROME: A CASE REPORT**  
Aina Mardiah Zulkifle, Nurain Mohd Noor, Zulaikha Che Che Embi, Noor Lita Mohd Adam
- 71 **EP\_A094**  
**CLINICAL USE OF DENOSUMAB FOR REFRACTORY HYPERCALCEMIA: A RETROSPECTIVE CASE SERIES**  
Mohammad Amirul Shahril, Florence Hui Sieng Tan, Ee Wen Loh, Pei Lin Chan, Sing Yee Sim
- 71 **EP\_A095**  
**THE HIGH BONE DENSITY PARADOX: PRIMARY HYPERPARATHYROIDISM IN THE SETTING OF OSTEOPETROSIS**  
Marisa Masera Marzukie, Shireene Ratna Vethakkan, Jeyakantha Ratnasingam
- 72 **EP\_A096**  
**THE CALCIUM CHASE: UNMASKING PARATHYROID CARCINOMA WITH CONCURRENT PAPILLARY THYROID MICROCARCINOMA**  
Fatin Liyana Binti Shahabudin, Nur Nisrina Binti Yahya, Nor Shaffinaz Yusoff Azmi Merican, Shartiyah Ismail
- 73 **EP\_A097**  
**SEVERE OSTEOPOROSIS WITH FRAGILITY FRACTURE REVEALING PRIMARY HYPERPARATHYROIDISM**  
Sarojini Devi Simanchalam, Poh Shean Wong, Nor Afidah Abdul Karim, Noor Lita Adam, Fauzi Azizan
- 73 **EP\_A098**  
**A CHALLENGING CASE OF PARATHYROID CARCINOMA IN AN ADOLESCENT**  
S. Muhammad Imran and Tong Chin Voon
- 74 **EP\_A099**  
**PACLITAXEL-INDUCED HYPOCALCEMIA IN A PATIENT WITH METASTATIC BREAST DISEASE AND UNDERLYING HYPOPARATHYROIDISM**  
Marina Norman, Nur Aini Eddy Warman, Nur Haziqah Baharum, Aimi Fadilah Mohamad, Mohd Hazriq Awang, Fatimah Zaherah Mohamed Shah, Rohana Abdul Ghani
- 74 **EP\_A100**  
**BEYOND THE OBVIOUS: UNMASKING PARATHYROID CARCINOMA IN AN ATYPICAL PRESENTATION**  
Pei Shin Lee and Poh Shean Wong
- 75 **EP\_A101**  
**FATAL HYPERCALCEMIC CRISIS SECONDARY TO PRIMARY HYPERPARATHYROIDISM: A CASE REPORT**  
Pey Hui See, Ee Wen Loh, Pei Lin Chan, Florence Hui Sieng Tan

- 75 **EP\_A102**  
**CATASTROPHIC SKELETAL FRAGILITY IN TRANSFUSION-DEPENDENT HBE  $\beta$ -THALASSEMIA: ENDOCRINE SIDEROSIS AND FAILURE OF ANTI-RESORPTIVE THERAPY**  
Ahmad Syahmi Yusof Zaki, Nur Izat Muhamad, Ezelea Elwina Walter Sandosam, Wan Mohd Izani Wan Mohamed
- 76 **EP\_A103**  
**CRANIOFACIAL BROWN TUMOR SECONDARY TO PERSISTENT MULTIGLANDULAR PRIMARY HYPERPARATHYROIDISM: A REVERSIBLE COMPLICATION**  
Fathiyah Ramly, Siti Sanaa Wan Azman, Masliza Hanuni Mohd Ali, Wan Mohd Hafez Wan Hamzah
- 76 **EP\_A104**  
**HOW ATYPICAL ADENOMA WORE THE MASK OF CARCINOMA IN A YOUNG MAN WITH SKELETAL CRISIS**  
Chee Kit Tee, Yong Siang Ng, Noor Hafis Md Tob, Norhaliza Mohd Ali
- 77 **EP\_A105**  
**BROWN TUMOR: RARE TODAY, BUT NEVER TO BE FORGOTTEN**  
Min Jing Choo and Liang Wei Wong
- 78 **EP\_A106**  
**A MULTIMODAL APPROACH USING CALCITONIN, DENOSUMAB, AND HEMODIALYSIS FOR THE MANAGEMENT OF REFRACTORY HYPERCALCEMIA IN MALIGNANCY**  
Nur Haziqah Baharum, Mohd Hazriq A., Aimi Fadilah M., Nur Aini Eddy Warman, Fatimah Zaherah MS, Rohana A.G.
- 78 **EP\_A107**  
**THE PLACENTA AS A PARATHYROID: PREGNANCY-INDUCED NORMALIZATION OF REFRACTORY POSTSURGICAL HYPOPARATHYROIDISM**  
Dinehs Rao, Siti Sanaa Wan Azman, Dorothy Maria Anthony Bernard, Foo Siew Hui
- 79 **EP\_A108**  
**SEVERE TOPHACEOUS GOUT CAUSING PTH-INDEPENDENT HYPERCALCEMIA: AN UNCOMMON ASSOCIATION**  
Hu Chong Siang, Kuan Yueh Chien, Lee Ho Mi, Cheong Yaw Kiet
- 79 **EP\_A109**  
**NEITHER A FRIEND NOR A FOE: AN UNUSUAL CASE OF SEVERE SYMPTOMATIC HYPERCALCEMIA SECONDARY TO ATYPICAL PARATHYROID ADENOMA**  
Wye Hong Leong, Qing Ci Goh, Vanusha Devaraja Pillai, Siow Ping Lee, Maryam Ahmad Sharifuddin
- 80 **EP\_A110**  
**BEYOND MTC: CLINICAL MANIFESTATIONS OF MEN2A IN HEREDITARY MEDULLARY THYROID CANCER PATIENTS IN A TERTIARY CENTRE**  
Qin Zhi Lee, Chin Voon Tong, Raja Nurazni Raja Azwan, Zanariah Hussein
- 80 **EP\_A111**  
**SAFETY AND CLINICAL OUTCOMES OF RAMADAN FASTING IN PATIENTS WITH ARGININE VASOPRESSIN DEFICIENCY: A RETROSPECTIVE COHORT STUDY**  
Suprhamanyam Evali, Nurain binti Mohd Noor, Nao Chang Zhao, Noor Ashikin binti Ismail, Dineash Kumar Kannesan, Nur Arina binti Mohammed Zain

- 81 **EP\_A112**  
**A CASE SERIES OF CARCINOID SYNDROME: A SINGLE-CENTRE EXPERIENCE**  
Jie En Tan and Noor Ashikin Ismail
- 81 **EP\_A113**  
**AORTIC DISSECTION: A RARE COMPLICATION IN ACROMEGALY**  
Zanariah Hussein, Wan Faizal Wan Rahimi Shah, Hamdan Leman
- 82 **EP\_A114**  
**INSULINOMA IN PREGNANCY PRESENTING WITH RECURRENT HYPOGLYCEMIA: DIAGNOSTIC CHALLENGES, MULTIDISCIPLINARY MANAGEMENT, AND THERAPEUTIC DILEMMAS**  
Abdullah Faiz Zaihan, Srinivas Siwalinggam, Noor Hayatul Al Akmal Noralam, Kaeshaelya Thiruchelvam, Chia Siang Kow
- 83 **EP\_A115**  
**BALANCING DISEASE CONTROL AND METABOLIC HARM: A CASE OF IgG4-RELATED HYPOPHYSITIS**  
Asma' Mohd Nazlee, Dorothy Maria Anthony Bernard, Siti Sanaa Wan Azman, Siew Hui Foo
- 83 **EP\_A116**  
**A DIAGNOSTIC DILEMMA IN ECTOPIC ACTH SYNDROME: WHEN BIOCHEMISTRY AND IMAGING CONFLICT**  
Ioanna Ting Yung Sim, Florence Hui Sieng Tan, Sing Yee Sim, Pei Lin Chan, Ee Wen Loh
- 84 **EP\_A117**  
**FROM HYPERNATREMIA TO HYPONATREMIA: SEQUENTIAL CENTRAL AVP DEFICIENCY (AVP-D) AND CEREBRAL SALT WASTING (CSW) IN TUBERCULOUS MENINGITIS (TBM)**  
Chia Yin Por, Ee Wen Loh, Pei Lin Chan, Florence Hui Sieng Tan
- 84 **EP\_A118**  
**MASKING ANDROPAUSE BY A FUNCTIONING GONADOTROPH MACROADENOMA: DISCORDANT CLINICAL AND HORMONAL FINDINGS**  
Niken Febriharsari, Mirza Adhyatma, Hemi Sinorita
- 85 **EP\_A119**  
**WHEN HYPERPROLACTINEMIA FAILS TO SUPPRESS: THE SILENT GONADOTROPH IN A PITUITARY MACROADENOMA**  
Min Jing Choo and Liang Wei Wong
- 86 **EP\_A120**  
**PITUITARY STALK INTERRUPTION SYNDROME DIAGNOSED IN THE FOURTH DECADE: A RARE CAUSE OF PATHOLOGICAL FRACTURE IN ADULTHOOD**  
Muhammad Atif Sadiqqi bin Nor Azlan and Amalina Haydar Ali Tajuddin
- 86 **EP\_A121**  
**A SILENT INTERVAL WITH AGGRESSIVE RETURN: METASTATIC SDHB-MUTATED MEDIASTINAL PARAGANGLIOMA**  
Seetha Devi Subramanian, Nor Shaffinaz Yusoff Azmi Merican, Shartiyah Ismail
- 87 **EP\_A122**  
**PRUDENT MANAGEMENT OF MICROPROLACTINOMA IN A TRANSGENDER WOMAN ON FEMINIZING HORMONAL THERAPY**  
Zi Yang Lian, Nicholas Ken Yoong Hee, Shireene Vethakkan, Jeyakantha Ratnasingam

- 87 **EP\_A123**  
**DIAGNOSTIC AND THERAPEUTIC ROLE OF ENDOSCOPIC ULTRASOUND IN A CT-NEGATIVE OCCULT INSULINOMA**  
Chee Kit Tee, Yong Siang Ng, Noor Hafis Md Tob, Norhaliza Mohd Ali
- 88 **EP\_A124**  
**RARE PROGRESSION OF MICROPROLACTINOMA TO MACROPROLACTINOMA: A CASE REPORT**  
Shinye Eng and Rabeah Md Zuki
- 88 **EP\_A125**  
**EMPTY SELLA AS A CLUE TO IDIOPATHIC INTRACRANIAL HYPERTENSION PRESENTING WITH PULSATILE TINNITUS AND PROGRESSIVE HEARING LOSS**  
Jean Mun Cheah, Prasana Nair Gengadharan, Yuan Ye Beh, Shireene Ratna Vethakkan
- 89 **EP\_A126**  
**THE TWO-YEAR PARADOX: A “PANCREATIC ADENOCARCINOMA” REVEALED AS METASTATIC INSULINOMA**  
Lim Chee Jack, Gaayathri Krishnan, Ilham Ismail, Mahrunissa Mahadi, Nurul Atiqah Abu Sahmah, Tan Geok Chin, Norlaila Mustafa, Norasyikin A. Wahab
- 90 **EP\_A127**  
**DIAGNOSTIC DILEMMA IN INTERPRETING INFERIOR PETROSAL SINUS SAMPLING IN SUSPECTED CYCLICAL CUSHING’S DISEASE IN AN ADOLESCENT**  
Nicholas Wee Wern Phan, Pei Sun Tan, Subashini Rajoo, Vanusha A/P Devaraja Pillai, Shazatul Reza binti Mohd Redzuan, Gayathri Devi Krishnan, Sharifah Noor Adrilla Long Mohd Noor Affendi
- 90 **EP\_A128**  
**WHEN IGF-1 MISLEADS: DISCORDANT BIOCHEMICAL FINDINGS IN ACROMEGALY**  
Ashwini Chandrasekaran, Subashini Rajoo, Gayathri Devi Krishnan, Shazatul Reza, Sharifah Noor Adrilla, Xe Hui Lee
- 91 **EP\_A129**  
**BIG AND BLURRY: GIANT PROLACTINOMA CASE SERIES**  
Nur Farrah Anima, Qing Ci Goh, Vanusha Devaraja Pillai, Siow Ping Lee
- 91 **EP\_A130**  
**BEYOND THE INFARCT: THE SILENT SELLAR SURPRISE**  
Siti Nabilah Afni Pakururazi, Ilham Ismail, Mahrunissa Mahadi, Norlaila Mustafa, Norasyikin A. Wahab
- 92 **EP\_A131**  
**AVP DEFICIENCY AS THE INITIAL MANIFESTATION OF MULTISYSTEM LANGERHANS CELL HISTIOCYTOSIS: A DIAGNOSTIC ODYSSEY**  
Yuvaranee Samanaseh, Vanusha Devaraja, Goh Qing Ci, Patricia Lee Siow Ping
- 92 **EP\_A132**  
**A RARE CASE OF PITUITARY APOPLEXY ASSOCIATED WITH MIDDLE CEREBRAL ARTERY INFARCT: A CORRELATION OR COINCIDENCE?**  
Muhammad Fitri Azizi Mat Dait and Khairul Azmi Ibrahim
- 93 **EP\_A133**  
**DEFYING THE SCALPEL: MANAGEMENT OF PITUITARY APOPLEXY WITH HYDROCORTISONE**  
Lakshna Vani Nadarajan, Sarojini Devi Simanchalam, Poh Shean Wong, Hamizah Hamzah, Nor Afidah Abdul Karim, Noor Lita Adam

- 94 **EP\_A134**  
**MALIGNANT HYPERNATREMIA COMPLICATING A HYPOTHALAMIC TUMOR:  
AN ENDOCRINE EMERGENCY**  
Vijayrama Rao Sambamoorthy, Man Ee Chiew, Xe Hui Lee
- 94 **EP\_A135**  
**ISOLATED CRANIAL DIABETES INSIPIDUS UNMASKED AFTER HYPEROSMOLAR  
HYPERGLYCEMIC STATE IN TYPE 2 DIABETES MELLITUS**  
Suseelah Bala Subramaniam, Rabeah Md Zuki, Loh Hoong Heng
- 95 **EP\_A136**  
**RARE CASE: EMPTY SELLA SYNDROME, GROWTH HORMONE DEFICIENCY, AND  
HASHIMOTO'S THYROIDITIS IN THALASSEMIA SPECTRUM**  
Athari Fadhila Namanda Putri, Eva Decroli, Dinda Aprilia, Alexander Kam, Yanne Pradwi Efendi
- 95 **EP\_A137**  
**THYROID-STIMULATING HORMONE (TSH)-SECRETING MACROADENOMA  
PRESENTING WITH RECURRENT ATRIAL FIBRILLATION IN FAILURE**  
Muzhaffar Mokhtar, Masliza Hanuni Mohd Ali, Wan Mohd Hafez Wan Hamzah
- 96 **EP\_A138**  
**SMALL LESION, BIG IMPACT: EUS LOCALIZATION AND ABLATION OF A CT-OCCULT  
INSULINOMA**  
Tharshini Indrajothy, Vanusha Devaraja, Goh Qing Ci, Tay Yang Zet, Patricia Lee Siow Ping
- 97 **EP\_A139**  
**CUSHING DISEASE MASQUERADING AS POLYCYSTIC OVARY SYNDROME:  
A DIAGNOSTIC PITFALL IN SEVERE HYPERANDROGENISM**  
Jean Mun Cheah, Fei Bing Yong, K.J. Lingeswary, Jen Hoong Oon,  
Sharifah Noor Adrilla binti Long Mohd Noor Affendi, Gayathri Devi A/P Krishnan,  
Shazatul Reza binti Mohd Redzuan, Subashini Rajoo
- 97 **EP\_A140**  
**CRISIS IN THE MASTER GLAND: A CASE SERIES OF PITUITARY APOPLEXY**  
Lok Yee Chek, Wei Wei Ng, Ijaz binti Hallaj Rahmatullah, Anilah Abdul Rahim
- 98 **EP\_A141**  
**COEXISTENCE OF NONFUNCTIONING PITUITARY ADENOMA AND GRAVES'  
DISEASE: A DIAGNOSTIC CHALLENGE**  
Alexander Kam, Dinda Aprilia, Eva Decroli, Syafril Syahbuddin, Yanne Pradwi Efendi,  
Athari Fadhila Namanda Putri
- 98 **EP\_A142**  
**RECURRENT ISCHEMIC STROKE TWO DECADES AFTER CRANIOSPINAL  
RADIOTHERAPY FOR SUPRASellar GERMINOMA: A CASE OF SUSPECTED  
RADIATION-INDUCED CEREBROVASCULAR DISEASE**  
Choon Peng Sun and Ahmad Affan bin Hassannuddin
- 99 **EP\_A143**  
**ASSOCIATION BETWEEN MEN1 GENE AND AIHA**  
Fatihin Abdul Razak, Nur Aini Eddy Warman, Mohd Hazriq Awang, Aimi Fadilah Mohamad,  
Nur Haziqah Baharum, Fatimah Zaherah Mohamed Shah, Rohana Abdul Ghani

- 100 **EP\_A144**  
**BIOCHEMICAL DISCORDANCE IN ACROMEGALY COMPLICATED BY PITUITARY APOPLEXY AND SEVERE INSULIN RESISTANCE**  
Jean Mun Cheah, Fei Bing Yong, K.J. Lingeswary, Jen Hoong Oon, Sharifah Noor Adrilla binti Long Mohd Noor Affendi, Gayathri Devi A/P Krishnan, Shazatul Reza binti Mohd Redzuan, Subashini Rajoo
- 100 **EP\_A145**  
**GROWTH AGAINST THE CLOCK: HORMONAL THERAPY IN LATE-DIAGNOSED MOSAIC TURNER SYNDROME**  
Asma' Mohd Nazlee, Dorothy Maria Anthony Bernard, Siti Sanaa Wan Azman, Siew Hui Foo
- 101 **EP\_A146**  
**FULVESTRANT INTERFERENCE WITH ESTRADIOL IMMUNOASSAYS: A CASE REPORT AND REVIEW OF LABORATORY IMPLICATIONS**  
Dywei Lee and Waye Hann Kang
- 101 **EP\_A147**  
**PRIMARY AMENORRHEA IN A PATIENT WITH CONGENITAL ANOMALIES OF THE KIDNEY AND URINARY TRACT (CAKUT): UNMASKING ATYPICAL MRKH SYNDROME TYPE II**  
Dameil Saw Kah Kheng
- 102 **EP\_A148**  
**ACTIVE MODERATE-TO-SEVERE THYROID EYE DISEASE: A CASE SERIES**  
Salmi Fatirah Salim, Chee Koon Low, Abdullah Shamshir Abd Mokti, Akmal Haliza Zamli
- 102 **EP\_A149**  
**BEYOND THE PITUITARY STALK: PRIMARY HYPOTHYROIDISM AS A RARE PRESENTATION OF MULTISYSTEM LANGERHANS CELL HISTIOCYTOSIS**  
Fang Chan Lim and Shireen Siow Leng Lui
- 103 **EP\_A150**  
**IMMUNE-MEDIATED PANCYTOPENIA ASSOCIATED WITH GRAVES' DISEASE MIMICKING EVANS SYNDROME AND CARBIMAZOLE-INDUCED AGRANULOCYTOSIS**  
Ahmad Syahmi Yusof Zaki, Ezelea Elwina Walter Sandosam, Nur Izat Muhamad, Wan Mohd Izani Wan Mohamed
- 103 **EP\_A151**  
**COLD SPOT WITHIN A HOT NODULE: THYROID STORM FROM TOXIC ADENOMA REVEALING RARE HURTHLE CELL ADENOMA**  
Ying Guat Ooi, Jun Kit Khoo, Tharsini Sarvanandan, Quan Hziung Lim, Jeyakantha Ratnasingam, Lee Ling Lim, Shireene Ratna Vethakkan, Nicholas Ken Yoong Hee
- 104 **EP\_A152**  
**ACUTE THYROID PAIN IN PREGNANCY: PAINFUL HASHIMOTO'S THYROIDITIS VERSUS SUBACUTE THYROIDITIS—A CASE REPORT**  
Hamizah Hamzah, Sarojini Devi Simanchalam, Wong Poh Shean, Nor Afidah Karim, Noor Lita Adam
- 105 **EP\_A153**  
**THE HIDDEN HAZARD AFTER TOTAL PARATHYROIDECTOMY: A CASE REPORT**  
Jie En Tan and Chin Voon Tong

- 105 **EP\_A154**  
**SUBACUTE HYPOTHYROID MYOPATHY AS AN ATYPICAL PRESENTATION FOLLOWING RADIOIODINE THERAPY**  
Thesapiriya Jeyapal, Nur Aini Eddy Warman, Nur Haziqah Baharum, Aimi Fadilah Mohamad, Mohd Hazriq Awang, Fatimah Zaherah Mohamed Shah, Rohana Abdul Ghani
- 106 **EP\_A155**  
**HASHIMOTO'S THYROIDITIS PRESENTING WITH RECURRENT MASSIVE PLEURAL EFFUSION SUGGESTIVE OF LYMPHOCYTIC INTERSTITIAL PNEUMONITIS**  
Endah Pratamaningtias and Nyoman Satvika Dharma Yudha
- 106 **EP\_A156**  
**A RARE CASE OF COMPLETE HEART BLOCK SECONDARY TO NON-AUTOIMMUNE NON-FAMILIAL FORM OF THYROTOXICOSIS**  
Ket Meng Chin, Katherine Khor, Nor Azmi Kamaruddin
- 107 **EP\_A157**  
**STEROID-RESPONSIVE ENCEPHALOPATHY ASSOCIATED WITH THYROIDITIS**  
Chua Chong Yee, Nur Haziqah Baharum, Fadzliana Hanum Jalal, Gunavathy Muthusamy
- 107 **EP\_A158**  
**MUSCLE WEAKNESS IN THYROID DISEASE: WHEN IT IS NOT THYROTOXIC MYOPATHY?**  
Hamizah Hamzah, Sarojini Devi Simanchalam, Yap Yon Lek, Wong Poh Shean, Nor Afidah Karim, Nadiyah Mohd Noor, Noor Lita Adam
- 108 **EP\_A159**  
**GRAVES' DISEASE PRESENTING WITH PANCYTOPENIA: A RARE REVERSIBLE HEMATOLOGICAL ABNORMALITY IN THYROTOXICOSIS**  
Wei Ton Wong, Che Azzah Hanim Che Yahya, Nurul Atikah Abdul Aziz
- 108 **EP\_A160**  
**A COSTLY ASSUMPTION: MISINTERPRETATION OF THYROID FUNCTION TESTS DELAYING GUILLAIN-BARRÉ SYNDROME DIAGNOSIS IN PREGNANCY**  
Chen Huey Ng and Wei Ton Wong
- 109 **EP\_A161**  
**BETA BLOCKER-INDUCED RAYNAUD PHENOMENON IN A CASE OF GRAVES' DISEASE**  
Lui Tjun Yew and Gerard Jason Mathews
- 110 **EP\_A162**  
**LYMPHOCYTIC TURNED LYMPHOMATOUS: A CASE OF HASHIMOTO'S THYROIDITIS**  
Suprhamanyam Evali, Amie-Anne Augustine, Shamharini Nagaratnam
- 110 **EP\_A163**  
**DISCORDANT TFT AFTER TOTAL THYROIDECTOMY: CHALLENGES OF DIAGNOSING RESISTANCE TO THYROID HORMONE**  
Tan Jia Miao, Pavai Sthaneshwar, Shireene Ratna Vethakkan
- 111 **EP\_A164**  
**FROM STABILITY TO STORM: THYROID STORM AFTER A DECADE OF ANTITHYROID DRUG**  
Jun Kit Khoo, Tharsini Sarvanandan, Ying Guat Ooi, Quan Hziung Lim, Carolyn Wai Ling Chee, Lee Ling Lim, Jeyakantha Ratnasingam, Shireene Ratna Vethakkan, Nicholas Ken Yoong Hee

- 111 **EP\_A165**  
**UNEXPECTED CARDIOVASCULAR COLLAPSE AFTER RADIOIODINE THERAPY IN A PATIENT WITH SEVERE GRAVES' CARDIOMYOPATHY**  
Choon Peng Sun and Ahmad Affan Bin Hassannuddin
- 112 **EP\_A166**  
**ACUTE ISCHEMIC STROKE MASKING UNDERLYING HYPERTHYROIDISM: A DIAGNOSTIC PITFALL OF NON-THYROIDAL ILLNESS SYNDROME**  
Ashwin Kaur and Ooi Chuan Ng
- 112 **EP\_A167**  
**WHEN THYROID MEETS DENGUE AND HEPATITIS: A CASE OF SEVERE THYROTOXICOSIS WITH MULTIORGAN DYSFUNCTION**  
Shamila Sutharsan and Yusniza Yusoff
- 113 **EP\_A168**  
**PRESENCE OF MACRO-TSH: A RARE MIMICKER OF SUBCLINICAL HYPOTHYROIDISM**  
Zi Yang Lian, Nicholas Ken Yoong Hee, Shireene Vethakkan, Jeyakantha Ratnasingam, Farhi Ain Jamaluddin
- 114 **EP\_A169**  
**OVERT HYPOTHYROIDISM PRESENTING WITH ISOLATED LOWER MOTOR NEURON FACIAL NERVE PALSY**  
Murshidah Ainun Mukhtar, Rabeah Md Zuki, Wei Chin Mow, Nurul Farehah Mohd Nazri
- 114 **EP\_A170**  
**FIRE IN THE GLAND: A RARE CASE OF GRAVES' DISEASE IN CYSTIC FIBROSIS**  
Mohd Deenie Mohd Rodzhan, Yik Hin Chin, Norasyikin A. Wahab, Norlaila Mustafa, Ilham Ismail, Mahrunissa Mahadi
- 115 **EP\_A171**  
**THYROID-LIVER INTERPLAY: EARLY RECOGNITION OF CARBIMAZOLE-INDUCED CHOLESTASIS AMID THYROTOXICOSIS**  
Zhi Ling Ng, Siti Nabihah Hatta, Yohggesh Arumugam, Ooi Chuan Ng
- 115 **EP\_A172**  
**THE EVOLVING BIOCHEMICAL PROFILE: FROM LOW FT4/LOW TSH TO ISOLATED HYPOTHYROXINEMIA IN PREGNANCY**  
Wei Ton Wong, Muhammad Amir Arif Mohammad Nizam, Amila Syahida Rusli
- 116 **EP\_A173**  
**WHEN TSH SUPPRESSION BECOMES HARMFUL: THYROXINE OVER-REPLACEMENT DRIVING CARDIOVASCULAR DECOMPENSATION IN ADVANCED HEART FAILURE**  
Ahmad Syahmi Yusof Zaki, Nur Izat Muhamad, Ezelea Elwina Walter Sandosam, Wan Mohd Izani Wan Mohamed
- 116 **EP\_A174**  
**SEVERE BIOCHEMICAL THYROTOXICOSIS WITHOUT CLINICAL HYPERTHYROIDISM IN ESRF FOLLOWING PARATHYROIDECTOMY: A DIAGNOSTIC AND THERAPEUTIC PITFALL**  
Ahmad Syahmi Yusof Zaki, Nur Izat Muhamad, Ezelea Elwina Walter Sandosam, Wan Mohd Izani Wan Mohamed

- 117 **EP\_A175**  
**THYROTOXICOSIS ASSOCIATED WITH GUILLAIN-BARRÉ SYNDROME:  
A RARE AUTOIMMUNE OVERLAP**  
Nur Asmak Abdullah, Rabeah Md Zuki, Mohamed Azlam Micdhadhu
- 118 **EP\_A176**  
**SYNERGISTIC USE OF PLASMAPHERESIS AND LITHIUM IN REFRACTORY THYROID  
STORM**  
Humaira Nuraqilah Mohd Yusof, Nur Aini Eddy Warman, Nur Haziqah Baharum, Aimi Fadilah Mohamad,  
Mohd Hazriq Awang, Fatimah Zaherah Mohamed Shah, Rohana Abdul Ghani
- 118 **EP\_A177**  
**HYPERTHYROIDISM AND GESTATIONAL TROPHOBLASTIC DISEASE: A CASE REPORT**  
K.J. Lingeswary, Jean Mun Cheah, Fei Bing Yong, Jen Hoong Oon, Aniqah Shamimi,  
Sharifah Noor Adrilla binti Long Mohd Noor Affendi, Gayathri Devi A/P Krishnan,  
Shazatul Reza Binti Mohd Redzuan, Subashini Rajoo
- 119 **EP\_A178**  
**A DIAGNOSTIC MASQUERADE: RESISTANCE TO THYROID HORMONE MIMICKING  
TSH-SECRETING PITUITARY ADENOMA**  
Deviga Lachumanan
- 119 **EP\_A179**  
**DYNAMIC AUTOIMMUNE THYROIDITIS IN MYELODYSPLASTIC SYNDROME:  
FROM PAINLESS THYROTOXICOSIS TO OVERT HYPOTHYROIDISM**  
Dekritiana Dian Pratiwi and Hemi Sinorita
- 120 **EP\_A180**  
**A THORN IN THE TREATMENT OF GRAVES' DISEASE: THE HIDDEN ALLERGEN**  
Suprhamanyam Evali, Siew Huang Lee, Karen Christelle, Anilah Abdul Rahim
- 120 **EP\_A181**  
**TITRATING THE MIND: REFRACTORY SCHIZOPHRENIFORM PSYCHOSIS AS AN  
ISOLATED "CEREBRAL STORM" IN GRAVES' DISEASE**  
Fang Chan Lim
- 121 **EP\_A182**  
**SUBACUTE THYROIDITIS VS SUPPURATIVE THYROIDITIS: A DIAGNOSTIC CHALLENGE**  
Jia En Chew, Ju Vern Ew, Albert Li Ren Chong, Eunice Yi Chwen Lau
- 122 **EP\_A183**  
**RESCUE PLASMA EXCHANGE IN THYROID STORM: SUCCESSFUL BRIDGING TO  
THIONAMIDE THERAPY**  
Pei Sun Tan, Hafizah Mohd Amadzun, Sharifah Noor Adrilla Long Mohd Noor Affendi,  
Gayathri Devi Krishnan, Shazatul Reza binti Mohd Redzuan, Subashini Rajoo

## Paediatric Oral Presentation

- 123 **OP\_P001**  
**BRIDGING THE GAP: ADOPTION AND BARRIERS TO CONTINUOUS GLUCOSE MONITORING IN PAEDIATRIC TYPE 1 DIABETES**  
Sok Bee Lim, Siti Sarah Ahmad Dardiri, Nalini M. Selveindran, Arini Nuran Md Idris, Janet Yeow Hua Hong
- 124 **OP\_P002**  
**CENTRAL PRECOCIOUS PUBERTY: EVALUATION OF PREDICTED AND FINAL ADULT HEIGHT IN GIRLS WHO RECEIVED GNRH ANALOGS**  
Adam Mohd Noor, Muhammad Yazid Jalaludin, Lixian Oh
- 125 **OP\_P003**  
**ETIOLOGICAL YIELD AND TREATMENT PATTERNS IN PAEDIATRIC ARGININE VASOPRESSIN DEFICIENCY: A SINGLE-CENTRE COHORT STUDY**  
Siti Sarah Ahmad Dardiri, Nalini M Selveindran, Sok Bee Lim, Arini Nuran Md Idris, Janet YH Hong
- 126 **OP\_P004**  
**HEALTH-RELATED QUALITY OF LIFE IN CHILDREN AND ADOLESCENTS WITH X-LINKED HYPOPHOSPHATEMIA (XLH) AT UNIVERSITI MALAYA MEDICAL CENTRE**  
Nur Syafiqah Hamizi, Muhammad Yazid Jalaludin, Mohd Shafiq Azanan, Nur Sabrina Rusli
- 127 **OP\_P005**  
**PREVALENCE AND NEONATAL PREDICTORS OF METABOLIC BONE DISEASE OF PREMATURE IN HOSPITAL TUNKU AZIZAH KUALA LUMPUR**  
Muhamad Hanif Halim, Choi Siang Choong, Arini Nuran Md Idris, Yee Lin Lee

## Paediatric Best Poster Presentation

- 128 **BP\_P001**  
**DIABETES-RELATED DISTRESS IN ADOLESCENTS WITH TYPE 1 DIABETES**  
Nur Sabrina Rusli, Mohd Shafiq Azanan, Azriyanti Anuar Zaini
- 129 **BP\_P002**  
**INCIDENCE, CLINICAL PRESENTATION, AND OUTCOME OF HYPERTHYROIDISM IN CHILDREN AND ADOLESCENTS: A SINGLE-CENTRE STUDY**  
Sivaneshwary Selvam and Nurshadia Binti Samingan
- 130 **BP\_P003**  
**GLYCEMIC CONTROL IN ADOLESCENTS WITH TYPE 1 DIABETES MELLITUS (T1DM): THE ROLE OF HEALTH LITERACY AND NUMERACY**  
Sharon Chung Tuang Yuk, Joyce Hong Soo Synn, Lim Poi Giok, Yang Wai Wai
- 131 **BP\_P004**  
**METABOLIC DYSFUNCTION-ASSOCIATED STEATOTIC LIVER DISEASE AMONG CHILDREN AND ADOLESCENTS IN A TERTIARY CENTRE IN SARAWAK**  
Geraldine Yee Pei Lim, Victoria David, Kiew Siong Lau, Chiong Hung Kiew, Hooi Peng Cheng
- 132 **BP\_P005**  
**EFFECTIVENESS AND SAFETY OF LOW-DOSE DIAZOXIDE IN TRANSIENT HYPERINSULINEMIC HYPOGLYCEMIA**  
Nuramalina Mazeli, Yong Hong Lee, Pian Pian Tee, Song Hai Lim

## Paediatric Best Case Report Presentation

- 133 **BC\_P001**  
MEDICAL MANAGEMENT OF PAEDIATRIC CUSHING SYNDROME PRESENTING WITH SEVERE HYPERCORTISOLISM  
Yee Lin Lee, Chun Jie Lee, Tzer Hwu Ting, Ooi Chuan Ng
- 134 **BC\_P002**  
PAEDIATRIC NODAT FOLLOWING KIDNEY TRANSPLANT: CLINICAL CHARACTERISTICS OF FOUR CASES AT HOSPITAL TUNKU AZIZAH  
Rohani Ahmad, Yap Yok Chin, Arliena Amin, Lim Poi Giok

## Paediatric E-Poster

- 135 **EP\_P001**  
EVALUATION OF ACANTHOSIS NIGRICANS AS A PREDICTIVE CLINICAL MARKER FOR METABOLIC RISK IN CHILDREN WITH OBESITY  
Annie Leong, Nurshadia Samingan, Muhammad Yazid Jalaludin, Azriyanti Anuar Zaini
- 135 **EP\_P002**  
PHENOTYPIC SPECTRUM AND GONADAL OUTCOMES IN CHILDREN WITH 45,X/46,XY MOSAICISM: A LONGITUDINAL COHORT STUDY  
Vaidevi Poospalangam, Janet Hong, Arini Nuran, Nalini M Selveindran
- 136 **EP\_P003**  
HEIGHT VELOCITY AND BODY MASS INDEX CHANGES DURING GONADOTROPIN-RELEASING HORMONE AGONIST THERAPY IN CHILDREN WITH CENTRAL PRECOCIOUS PUBERTY (CPP)  
Alexis Lordudass, Nuratikah Mohd Ghazali, Jay Yin Lim, Mazidah Noordin, Noor Shafina Mohd Nor
- 136 **EP\_P004**  
A SPECTRUM OF THYROID DYSFUNCTION IN CHILDREN WITH DOWN SYNDROME: A MALAYSIAN TERTIARY CENTRE EXPERIENCE  
Priyadarshini Puvanendran, Azriyanti Binti Anuar Zaini, Wan Hanaa Mardhiah Binti Wan Zainuddin
- 137 **EP\_P005**  
PREVALENCE OF HYPOTHYROIDISM AND GROWTH OUTCOMES AMONG PATIENTS WITH DOWN SYNDROME  
Siti Nur Khairiah Bt Mohd Rozali, Suhaimi Hussain, Surini Yusoff
- 137 **EP\_P006**  
CLINICAL CHARACTERISTICS AND OUTCOMES OF PAEDIATRIC HYPERTHYROIDISM: A 10-YEAR SINGLE CENTRE RETROSPECTIVE COHORT STUDY FROM NEGERI SEMBILAN  
Munzir Jamil, Mastura Ibrahim, Meenal Mavinkurve
- 138 **EP\_P007**  
CLINICAL AUDIT OF CLONIDINE AS A FIRST-LINE PROVOCATIVE AGENT TO EXCLUDE GROWTH HORMONE DEFICIENCY IN CHILDREN WITH SHORT STATURE  
Mazidah Noordin, Sook Weih Lew, Alexis Anand Dass, Jay Yin Lim, Noor Shafina Mohd Nor

- 138 **EP\_P008**  
**CLINICAL OUTCOMES OF GONADOTROPIN-RELEASING HORMONE AGONIST THERAPY IN CHILDREN WITH CENTRAL PRECOCIOUS PUBERTY**  
Siti Zakiyyah Bakhtiar, Jia Nyuk Chong, Hooi Peng Cheng
- 139 **EP\_P009**  
**PAEDIATRIC GLUCOCORTICOID-INDUCED HYPERGLYCEMIA AND DIABETIC KETOACIDOSIS: AN UNDER-RECOGNIZED COMPLICATION OF CANCER THERAPY**  
Sasirekha Krisnan Morthy, Annie Leong, Nurshadia Samingan, Azriyanti Anuar Zaini
- 140 **EP\_P010**  
**INFANT HYPOGLYCEMIA REVEALING FACTITIOUS DISORDER IMPOSED ON ANOTHER**  
Mastura Ibrahim, Munzir Jamil, Meenal Mavinkurve
- 140 **EP\_P011**  
**A SILENT COMPLICATION OF PROLONGED IMMOBILIZATION: FRAGILITY FRACTURE IN A CHRONICALLY ILL ADOLESCENT WITH THALASSEMIA**  
Saw Shi Hui
- 141 **EP\_P012**  
**A RARE PAEDIATRIC CASE OF AVPR2-RELATED NEPHROGENIC SYNDROME OF INAPPROPRIATE ANTIDIURESIS IN PENANG**  
Wei Lian Lean, Raja Aimee Binti Raja Abdullah, Gaik Siew Ch'ng, Voon Lee Lim
- 141 **EP\_P013**  
**PARTIAL ANDROGEN INSENSITIVITY SYNDROME PRESENTING AS AMBIGUOUS GENITALIA IN A 46, XY INFANT**  
Muhammad Shafiq Safwan bin Md Latip, Shi Chyn Lim, Yee Lin Lee
- 142 **EP\_P014**  
**CONGENITAL TOXOPLASMOSIS WITH CRANIAL DIABETES INSIPIDUS AND HYDROCHLOROTHIAZIDE**  
May Hou Yap, Nurul Farah Wahidah Abd Razak, Sze Teik Teoh
- 142 **EP\_P015**  
**STARVED BONES, FAILING HEART: UNCOMMON YET LIFE THREATENING HYPOCALCEMIC CARDIOMYOPATHY IN NUTRITIONAL RICKETS**  
Siti Nur Hanim Najwa binti Sheikh Osman and Sze Teik Teoh
- 143 **EP\_P016**  
**MATURITY-ONSET DIABETES OF THE YOUNG ASSOCIATED WITH A ABCC8 VARIANT**  
Jia Cheng Ong and Suhaimi Hussain
- 143 **EP\_P017**  
**RECOGNIZING RENI SYNDROME: A CASE OF ADRENAL INSUFFICIENCY, ICHTHYOSIS, AND PROTEINURIA**  
Noor Zakirah Noordin, Saw Shi Hui, Noor Arliena binti Mat Amin
- 144 **EP\_P019**  
**46XX, TESTICULAR DSD WITH A NEGATIVE SRY: WHAT YOU SEE IS NOT ALWAYS THE TRUTH**  
Chia Ying Kang and Sze Teik Teoh

- 144 **EP\_P020**  
**THE SYSTEMIC COST OF INTRALESIONAL TRIAMCINOLONE FOR PAEDIATRIC KELOIDS**  
Naveen Nair Gangadaran, Mastura Ibrahim, Meenal Mavinkurve
- 145 **EP\_P021**  
**GROWTH HORMONE THERAPY IN PAEDIATRIC ONCOLOGY SURVIVORS: CASE SERIES FROM A MALAYSIAN TERTIARY CENTRE**  
Nur Amalina Yusof, Lim Poi Giok, Arliena Amin
- 145 **EP\_P022**  
**WHEN PUBERTY COMES TOO SOON: CENTRAL PRECOCIOUS PUBERTY WITH PITUITARY MICROADENOMA AND PINEAL CYST**  
Fawza Nabila Faudzi, Asmalaini Mohamad, Nalini M. Selveindran
- 146 **EP\_P023**  
**BECKWITH-WIEDEMANN SYNDROME PRESENTING AS PERSISTENT NON-KETOTIC HYPOGLYCEMIA IN A PRETERM INFANT**  
Wan Nurzahiah Wan Zakaria, Yee Lin Lee, Sin Yin Gan, Tong Wooi Ch'ng, Zurina Zainudin
- 146 **EP\_P024**  
**BEYOND OBESITY: DIAGNOSTIC CHALLENGES OF BARDET-BIEDL SYNDROME**  
Shahidatul Munirah Mohammad Salihuddin and Suhaimi Hussain
- 147 **EP\_P025**  
**ABCD SYNDROME: A RARE BUT UNDERRECOGNIZED CAUSE OF HYPERCALCEMIA IN DOWN SYNDROME**  
Nurul Farah Wahidah Abd Razak and Sze Teik Teoh
- 147 **EP\_P026**  
**BEYOND GRAVES' DISEASE AND TYPE 1 DIABETES MELLITUS: THYROTOXIC HEART FAILURE AND EMERGING POLYGLANDULAR SYNDROME TYPE 2**  
Sharon Mui Kim Lim, Li Yuen Nyin, Zulaikha Che Imbi, Farizan AB Ghani
- 148 **EP\_P027**  
**NOT JUST DEHYDRATION: A CASE OF EARLY ONSET PERSISTENT HYPERNATREMIA IN A PRETERM BABY**  
Sin Yin Gan, Wan Nurzahiah Wan Zakaria, Zurina Zainudin, Yee Lin Lee

### Basic Science E-Poster

- 149 **EP\_S001**  
**THE EFFECT OF TUBE TYPE AND TIME ON GLUCOSE STABILITY**  
Prisheila Mahendran, Pawai Sthaneshwar, Jeyakantha Ratnasingam, Farhi Ain Binti Jamaluddin, Ai Chin Yeoh, Nurdini Binti Alias, Khalida Binti Ramdzan
- 149 **EP\_S003**  
**THERAPEUTIC PLASMA EXCHANGE FOR PREOPERATIVE STABILIZATION IN GRAVES' DISEASE COMPLICATED BY AGRANULOCYTOSIS**  
Muhammad Azim Puad, Nadia Nordin, Elliyyin Katiman, Hazwani Aziz, Hidayatil Alimi Keya Nordin

## Adult Oral Presentation

### OP\_A001

#### ONE-HOUR OGTT REVEALS WHAT CONVENTIONAL SCREENING MISSES: A HIDDEN PREDIABETES BURDEN IN MALAYSIA

Gerard Jason Mathews<sup>1,2</sup>, Seetha Devi Subramanian<sup>2</sup>, Nor Shaffinaz Yusoff Azmi Merican<sup>2</sup>, Shartiyah Ismail<sup>2</sup>, Joel Mathews<sup>2</sup>, Leng Ean Charis Kong<sup>3</sup>, Chong Hui Khaw<sup>4</sup>, Shubash Shander Ganapathy<sup>5</sup>, Arvinder-Singh HS<sup>3</sup>

<sup>1</sup>Hospital Canselor Tuanku Muhriz, Hospital Universiti Kebangsaan Malaysia (HUKM)

<sup>2</sup>Hospital Sultanah Bahiyah

<sup>3</sup>Hospital Raja Permaisuri Bainun

<sup>4</sup>Hospital Pulau Pinang

<sup>5</sup>National Institutes of Health

#### INTRODUCTION

Prediabetes or intermediate hyperglycemia (IH) represents a critical phase in the trajectory toward type 2 diabetes mellitus (T2DM). Recent evidence from the International Diabetes Federation (IDF) suggests that 1-hour OGTT (1HOGTT)  $\geq 8.6$  mmol/L is a more sensitive biomarker for early beta-cell dysfunction, with enhanced detection of IH and future T2DM risk. Conventional screening using hemoglobin A1c (HbA1c) or 2-Hour OGTT (2HOGTT) may delay identification of prediabetes, narrowing the window for early intervention. This study evaluates 1HOGTT as a screening tool for prediabetes among Malaysians.

#### METHODOLOGY

This cross-sectional study enrolled adults without prior T2DM or prediabetes. Participants underwent 1HOGTT, 2HOGTT, and HbA1c, classified as per the Malaysian Clinical Practice Guideline for T2DM (6th Edition) and IDF 2024 criteria. Agreement between tests was assessed using McNemar's test and Cohen's kappa. Diagnostic accuracy was evaluated via receiver operating characteristic (ROC) curve analysis. Cost-effectiveness was determined using reagent cost only.

#### RESULTS

The majority of the 310 participants were female (71.6%), Malay (87.1%), with average age of 40. The 1HOGTT identified prediabetes in 21.6% ( $n = 67$ ) compared to 17.1% ( $n = 53$ ) by HbA1c and 2.6% ( $n = 8$ ) by 2HOGTT. McNemar's test confirmed statistically significant discordance between 1HOGTT and 2HOGTT (chi-square = 53.397,  $p < 0.001$ ): 61 participants were prediabetic by 1HOGTT but normal by 2HOGTT, versus only 2 in the reverse direction. No significant discordance was found between 1HOGTT and HbA1c (chi-square = 2.817,  $p = 0.093$ ). 1HOGTT demonstrated excellent discriminatory ability against 2HOGTT (AUC = 0.908; 95% CI: 0.837–0.978), significantly outperforming HbA1c (AUC = 0.664; CI: 0.462–0.867; DeLong  $p = 0.012$ ). In a population-level cost analysis, 1HOGTT achieved lowest cost per prediabetes case detected (RM 5.79) – approximately 8.3 times and 8.1 times more cost-effective than 2HOGTT (RM 48.08) and HbA1c (RM 46.78) respectively.

#### CONCLUSION

1HOGTT identifies a significant proportion of individuals with prediabetes missed by 2HOGTT and HbA1c. Incorporating 1HOGTT enhances the detection of prediabetes, is cost-effective, and enables timely preventive measures in our population with high diabetes burden.

## OP\_A002

### OBESITY AND INSULIN THERAPY AS PREDICTORS OF ENDOTHELIAL DYSFUNCTION IN TYPE 2 DIABETES MELLITUS WITH EARLY CKD

Nursyahirah Ishak<sup>1</sup>, Nur' Aini Eddy Warman<sup>1</sup>, Rohana Abd Ghani<sup>1</sup>

<sup>1</sup>Universiti Teknologi MARA (UiTM)

#### INTRODUCTION

Endothelial dysfunction (ED) is an early marker of atherosclerosis and plays a role in the pathophysiology of cardiovascular complications in type 2 diabetes mellitus (T2DM). Metabolic factors such as adiposity and insulin resistance contribute to early vascular dysfunction, particularly in patients with preserved kidney function. This study aimed to identify factors associated with ED in T2DM and early-stage chronic kidney disease (CKD).

#### METHODOLOGY

This study was conducted at Universiti Teknologi MARA (UiTM), Sungai Buloh, and involved 107 adults with T2DM and estimated glomerular filtration rate  $\geq 60$  mL/min/1.73 m<sup>2</sup> (CKD stages 1–2). Endothelial function was assessed using ultrasound-based brachial artery flow-mediated dilation (FMD), with  $\leq 7.1\%$  defining ED. Clinical, anthropometric, metabolic, and renal parameters were compared between groups. Logistic regression analyses were performed to identify independent predictors, with  $p$ -values  $< 0.05$  considered statistically significant.

#### RESULTS

Of the cohort, 48.6% ( $n = 52$ ) had abnormal FMD. They tended to have higher BMI (31.36 vs 28.38 kg/m<sup>2</sup>,  $p = 0.020$ ), larger waist circumference (100.48 vs 94.53 cm,  $p = 0.026$ ), and were more likely to be on insulin therapy (71.2 vs 49.1%,  $p = 0.020$ ). The total daily insulin dose was higher in the abnormal FMD group (0.48 vs 0.35 U/kg), but this difference did not reach statistical significance ( $p = 0.140$ ). There were no significant differences in hemoglobin A1c, blood pressure, or renal parameters. In multivariate analysis, BMI (adjusted OR 1.07, 95% CI 1.00–1.14,  $p = 0.037$ ) and insulin therapy (adjusted OR 2.43, 95% CI 1.07–5.51,  $p = 0.034$ ) remained independently associated.

#### CONCLUSION

In patients with T2DM and early CKD, higher BMI and insulin therapy are independently associated with ED. These findings highlight the role of obesity and insulin resistance in early vascular dysfunction, emphasizing the importance of weight-targeted strategies alongside glycemic control and further identifying high-risk individuals to reduce cardiovascular risk.

## OP\_A003

### ISOLATION OF FUNCTIONAL HUMAN LEYDIG CELLS: A DIFFERENTIAL-ADHESION APPROACH WITH MULTI-MODAL PHENOTYPIC AND STEROIDOGENIC VALIDATION

Yee Jia Heng<sup>1</sup>, Pooi Pooi Leong<sup>1</sup>, Omar Ahmed Fahmy Ahmed<sup>2</sup>, Waye Hann Kang<sup>3</sup>

<sup>1</sup>Department of Preclinical Sciences, M. Kandiah Faculty of Medicine and Health Sciences, Universiti Tunku Abdul Rahman

<sup>2</sup>Department of Urology, Faculty of Medicine and Health Sciences, Universiti Putra Malaysia

<sup>3</sup>Department of Medicine, M. Kandiah Faculty of Medicine and Health Sciences, Universiti Tunku Abdul Rahman

#### INTRODUCTION

Leydig cells (LCs) are the principal source of testosterone in males, underpinning male reproductive health and androgen-dependent physiology. Precise isolation of viable human LCs is essential for mechanistic steroidogenesis research and cell-based therapeutic development. Existing protocols rely on density-gradient centrifugation, which is technically demanding and often compromises yield and viability. Here, we describe a simplified density-gradient-free approach using differential adhesion to enrich functional human LCs from testicular tissue.

#### METHODOLOGY

Human testicular fragments (~5 mm<sup>3</sup>) were minced and enzymatically digested with collagenase IV (2 mg/mL) at 37°C for 20 min under gentle agitation (100 RPM). The suspension was filtered (45 µm) and plated onto poly-L-lysine-coated T25 flasks. After 24 hours, non-adherent cells were removed by PBS washing. Viability exceeded 90% by trypan blue exclusion. Cells were maintained in DMEM/F12 with 10% FBS, 1% Antibiotic-Antimycotic, and 10 ng/mL luteinizing hormone (LH) to preserve the mature LC phenotype. Characterization employed immunofluorescence and flow cytometry using antibodies against SF-1, StAR, LHCGR, PDGFRA, and TEM-1. Testosterone secretion was quantified by ELISA under basal conditions and LH-stimulated conditions (10 ng/mL).

#### RESULTS

The protocol yielded ~1.25 × 10<sup>6</sup> LCs per gram of tissue with >80% purity. Adherent HLCs displayed dense cytoplasmic lipid granules and intercellular networks consistent with active steroidogenesis. Flow cytometry confirmed 84.7% StAR<sup>+</sup> cells, indicative of a robust steroidogenic population. A distinct progenitor subpopulation (PDGFRα<sup>+</sup>/TEM-1<sup>+</sup>) comprising ~28% of primary cultures, suggests retention of regenerative capacity. Basal testosterone secretion averaged 8.88 ng/mL per 24 hours, confirming preserved functional activity post-isolation.

#### CONCLUSION

This differential-adhesion protocol efficiently isolates functional human LCs without density-gradient media. Multi-modal validation integrating immunofluorescence, flow cytometry, and ELISA confirms both phenotypic identity and steroidogenic competence, providing a reproducible and accessible platform for LC research and translational applications in male hypogonadism and androgen replacement.

## OP\_A004

### WHO SUCCEEDS IN INSULIN DEINTENSIFICATION? REAL-WORLD PREDICTORS AND MODIFIABLE FACTORS FROM PRIMARY CARE

Yee Theng Chong<sup>1</sup>, Mohammad Ashwad Muhd Zin<sup>1</sup>, Anisha K Nijar<sup>1</sup>, Nur Syellawathy Ahmad<sup>2</sup>, Mohd Khairi Mohd Noor<sup>3</sup>, Noorhazliza Abdul Patah<sup>4</sup>, Erleena Nur Hassan<sup>5</sup>, Izwan Effendy Ismail<sup>6</sup>, Najwa Aziz<sup>7</sup>, Min Chiee Leon<sup>8</sup>, Hui Ting Ng<sup>9</sup>, Khairatun Hisan Mohd Napiyah<sup>7</sup>, Manothini A/P Perumal<sup>4</sup>, Shih Ling Selene Ng Shih Ling<sup>5</sup>, Ming Hui Liew<sup>6</sup>, Cha Chee Chong<sup>3</sup>

<sup>1</sup>Klinik Kesihatan Kelana Jaya

<sup>2</sup>Pejabat Kesihatan Daerah Petaling

<sup>3</sup>Klinik Kesihatan Seksyen 7 Shah Alam

<sup>4</sup>Klinik Kesihatan Seri Kembangan

<sup>5</sup>Klinik Kesihatan Taman Medan

<sup>6</sup>Klinik Kesihatan Puchong Batu 14

<sup>7</sup>Klinik Kesihatan Seksyen 19 Shah Alam

<sup>8</sup>Klinik Kesihatan Kampung Melayu Subang

<sup>9</sup>Klinik Kesihatan Kota Damansara

#### INTRODUCTION

Insulin therapy is essential in the management of type 2 diabetes mellitus (T2DM), but is often associated with treatment burden, hypoglycemia, and potential overtreatment. Insulin deintensification is increasingly recommended for appropriately selected patients; however, there is limited real-world evidence to guide patient selection and to identify modifiable factors that influence successful insulin deintensification. This study aimed to identify clinical predictors, including modifiable factors, associated with successful insulin deintensification in a primary care setting.

#### METHODOLOGY

A multicentre retrospective observational study was conducted across seven government primary care clinics in the Petaling District. Adult patients with T2DM undergoing insulin deintensification were included. Successful insulin deintensification was defined as maintenance or improvement of hemoglobin A1c following insulin discontinuation, dose reduction, or reduction in injection frequency. Paired outcomes were analyzed using the Wilcoxon signed-rank test. Between-group comparisons were performed using the Mann-Whitney U test and Chi-square or Fisher's exact test. Multivariable logistic regression was used to identify independent predictors of successful insulin deintensification.

#### RESULTS

A total of 261 patients were included. Glycemic control remained stable following insulin deintensification ( $p = 0.334$ ). Significant reductions in body weight ( $-0.41$  kg,  $p = 0.012$ ) and total daily insulin dose (23.1% reduction,  $p < 0.001$ ) were observed. Univariate analysis did not demonstrate significant differences between groups. However, multivariable logistic regression identified SGLT-2 inhibitor use (aOR 3.23, 95% CI 1.28–8.18,  $p = 0.013$ ) and regular SMBG (aOR 2.00, 95% CI 1.05–3.81,  $p = 0.035$ ) as independent predictors of successful insulin deintensification.

#### CONCLUSION

Insulin deintensification can be successfully implemented without compromising glycemic control. Identified predictors, including modifiable factors such as SGLT-2 inhibitor use and SMBG, provide clinically actionable insights to guide patient selection and treatment optimization. These findings challenge the traditional reluctance toward insulin deintensification and support a more evidence-based and individualized approach in routine clinical practice.

## OP\_A005

### A PROSPECTIVE STUDY IN INSULIN REGIMEN DE-ESCALATION FROM MULTIPLE DAILY INJECTION IN PATIENTS WITH POORLY CONTROLLED TYPE 2 DIABETES MELLITUS

Yik Hin Chin<sup>1</sup>, Xun Yi Tiong<sup>2</sup>, Noor Lita Adam<sup>3</sup>, Subashini Rajoo<sup>4</sup>, Chin Voon Tong<sup>5</sup>, Miza Hiriyanti Binti Zakaria<sup>6</sup>, Daanisha Nayar<sup>1</sup>, Sze Wei Lim<sup>1</sup>, Siew Hui Foo<sup>1</sup>

<sup>1</sup>Endocrine Unit, Hospital Selayang

<sup>2</sup>Clinical Research Centre, Sarawak General Hospital, Institute for Clinical Research

<sup>3</sup>Endocrine Unit, Hospital Tuanku Jaafar Seremban

<sup>4</sup>Endocrine Unit, Hospital Kuala Lumpur

<sup>5</sup>Endocrine Unit, Institut Endokrin, Hospital Putrajaya

<sup>6</sup>Endocrine Unit, Hospital Sultanah Maliha

#### INTRODUCTION

Multiple daily insulin injections, while effective for glycemic control, impose considerable costs on healthcare systems and carry inherent risks including hypoglycemia, weight gain, and poor treatment adherence. This study evaluates the glycemic effects of insulin regimen de-escalation from multiple daily injections in poorly controlled type 2 diabetes mellitus (T2DM) patients and explores the predictors of successful insulin de-escalation.

#### METHODOLOGY

This is a multi-centred, prospective observational study of adult T2DM patients on multiple daily insulin injections with hemoglobin A1c (HbA1c) 7–12% who underwent de-escalation to one or two injections. Patients were reassessed at 3 months and 6 months. Primary endpoint was change in HbA1c from baseline. Secondary endpoints were changes in body weight, hypoglycemia frequency, treatment adherence and predictors of successful insulin de-escalation defined by at least a 0.3% reduction in HbA1c while on de-escalated regimen.

#### RESULTS

A total of 80 patients were included. HbA1c improved from 9.23 to 8.52% ( $p < 0.001$ ) with total daily insulin dose reduction from  $0.81 + 0.35$  units per kg to  $0.46 + 0.24$  units per kg. Symptomatic hypoglycemia decreased from 22.5 to 5.0%. Insulin adherence improved from 50.0 to 92.3%. Body weight decreased by 1.4 kg. Forty-nine patients (61.3%) were successfully de-intensified. Factors associated with successful insulin de-escalation included a high baseline HbA1c, high fasting blood glucose and higher estimated glomerular filtration rate, while increased age, disease duration and being Indian were associated with unsuccessful insulin de-escalation. After adjustment of the confounders, only HbA1c (OR 2.07, 95% CI 1.23–3.46,  $p = 0.006$ ) and the status of being Indian (OR 0.21, 95% CI 0.05–0.94,  $p = 0.041$ ) remained as significant positive and negative predictors respectively for successful insulin de-intensification.

#### CONCLUSION

Insulin regimen de-escalation, when combined with optimized oral glucose-lowering agents, improved glycemic control and treatment adherence while reducing hypoglycemia and body weight. These findings support insulin therapy de-escalation as a safe, effective strategy for poorly controlled T2DM patients taking multiple daily insulin injections.

## OP\_A006

### SINGLE-CELL SPATIAL PROFILING REVEALS IMMUNE-STEROIDOGENIC CROSSTALK IN ADRENALS OF PATIENTS WITH PRIMARY ALDOSTERONISM

Noorzaileen Eileena Zaidi<sup>1</sup>, Amnani Aminuddin<sup>1</sup>, Aina Nadheera Abd Rahman<sup>1</sup>, Faezah Abdul Latif<sup>1</sup>, Emily Goodchild<sup>2</sup>, Kate Laycock<sup>2</sup>, Eva Wozniak<sup>3</sup>, Charles Mein<sup>3</sup>, Muaatamarulain Mustangin<sup>4</sup>, Nor Adzimah Johdi<sup>5</sup>, Nor Haslinda Abd Aziz<sup>6</sup>, Adli Ali<sup>7,14</sup>, Azraai Bahari Nasruddin<sup>8</sup>, Miroslav Solar<sup>9</sup>, Troy Puar Hai Kiat<sup>10</sup>, Norlela Sukor<sup>1,11</sup>, William Drake<sup>12,13</sup>, Morris Jonathan Brown<sup>2,12</sup>, Elena Aisha Azizan<sup>1,2,14</sup>

<sup>1</sup>Department of Medicine, Faculty of Medicine, The National University of Malaysia, Malaysia

<sup>2</sup>Centre of Clinical Pharmacology and Precision Medicine, William Harvey Research Institute, Queen Mary University of London, London, United Kingdom

<sup>3</sup>Barts and London Genome Centre, School of Medicine and Dentistry, Blizard Institute, London, United Kingdom

<sup>4</sup>Department of Pathology, Faculty of Medicine, The National University of Malaysia, Malaysia

<sup>5</sup>UKM Medical Molecular Biology Institute, The National University of Malaysia, Malaysia

<sup>6</sup>Department of Obstetrics and Gynaecology, Faculty of Medicine, The National University of Malaysia, Malaysia

<sup>7</sup>Department of Paediatrics, Faculty of Medicine, The National University of Malaysia, Malaysia

<sup>8</sup>Department of Endocrinology, Hospital Putrajaya, Malaysia

<sup>9</sup>1<sup>st</sup> Department of Internal Medicine–Cardioangiology, Charles University Faculty of Medicine in Hradec Kralove and University Hospital Hradec Kralove, Czech Republic

<sup>10</sup>Department of Endocrinology, Changi General Hospital, Singapore

<sup>11</sup>Hospital Canselor Tuanku Muhriz Universiti Kebangsaan Malaysia, Malaysia

<sup>12</sup>NIHR Barts Biomedical Research Centre, Barts and The London School of Medicine and Dentistry, Queen Mary University of London, London, United Kingdom

<sup>13</sup>St Bartholomew's Hospital, Barts Health NHS Trust, London, United Kingdom

<sup>14</sup>Research Center, Hospital Tunku Ampuan Besar Tuanku Aishah Rohani, Universiti Kebangsaan Malaysia (UKM) Specialist Children's Hospital, Malaysia

#### INTRODUCTION

Primary aldosteronism (PA), most commonly caused by aldosterone-producing adenomas (APAs), represents the leading form of surgically curable secondary hypertension. While genomic studies have elucidated the mutational landscape of APAs, the spatial organisation and functional role of immune populations across APAs, aldosterone-producing micronodules (APMs), and adjacent adrenal cortex remain poorly defined at single-cell resolution.

#### METHODOLOGY

Single-cell RNA sequencing (scRNA-seq) was integrated with spatial transcriptomics in APAs and paired adjacent adrenal cortex, complemented by immunohistochemical (IHC) validation. Immune populations were spatially mapped using canonical markers (CD14, CD68, CD163, HLA-DR, CD8A, and CD4) across defined adrenocortical regions.

#### RESULTS

The adrenal microenvironment in PA demonstrates structured immune organisation rather than passive infiltration. CD14<sup>+</sup> monocyte-lineage cells localize intraparenchymally within APAs ( $n = 10$ ), intercalating between CYP11B2<sup>+</sup> aldosterone-producing cells and forming a pattern distinct from perivascular immune niches. scRNA-seq further identified a transcriptionally distinct CD14<sup>+</sup> population within the zona reticularis (zR) that co-expresses steroidogenic markers (CYB5A, SULT2A1, TSPAN12) while lacking canonical monocyte transcripts. IHC supported this observation, demonstrating CD14 expression within adrenocortical zR parenchymal cells ( $n = 5$ ). In parallel, CD4 and HLA-DRA exhibited diffuse cytoplasmic staining within zR parenchymal cells in the absence of classical macrophage marker co-expression (CD68), suggesting non-canonical or context-dependent expression within steroidogenic compartments. CD68<sup>+</sup> and CD163<sup>+</sup> macrophages were sparsely distributed across APA, APM and adjacent cortex, consistent with low-density tissue-resident populations, while CD8A<sup>+</sup> cytotoxic lymphocytes were enriched in APAs and APMs with diffuse parenchymal cytoplasmic staining of CD8A additionally observed within the zR.

#### CONCLUSION

These findings reveal a previously unrecognized spatially organised immune-steroidogenic interface within the adrenal cortex. The presence of immune-associated transcriptional and protein signatures within zR cells suggests potential functional plasticity of steroidogenic cells, possibly extending to antigen presentation-related pathways, warranting further mechanistic investigation.

## Adult Best Poster Presentation

### BP\_A001

#### EFFECTIVENESS OF A NEWLY DEVELOPED YOUTUBE DIABETES EDUCATION: A MULTICENTRE RANDOMIZED CONTROLLED TRIAL

Phei Ching Lim<sup>1</sup>, Yi Woei Tang<sup>1</sup>, Jia Hui Cheng<sup>1</sup>, Leong Seng Tan<sup>2</sup>, Hooi Hoon Tan<sup>3</sup>, Chong Hui Khaw<sup>4</sup>

<sup>1</sup>Department of Pharmacy, Hospital Pulau Pinang

<sup>2</sup>Department of Pharmacy, Hospital Bukit Mertajam

<sup>3</sup>Department of Pharmacy, Klinik Kesihatan Sungai Dua

<sup>4</sup>Department of Medical, Hospital Pulau Pinang

#### INTRODUCTION

Adequate knowledge of diabetes is essential for effective self-management and glycemic control. Emerging trends in digital platforms, video-based education offer a scalable and accessible approach to patient learning. However, evidence on the effectiveness of validated YouTube-based diabetes education in the Malaysian population remains limited. We aimed to evaluate the impact of a newly developed, tri-language YouTube diabetes education programme on clinical and knowledge outcomes.

#### METHODOLOGY

In this multicentre study, patients with diabetes mellitus were randomly assigned to intervention (YouTube-based education) and control groups (standard care). The intervention consisted of newly developed and validated short educational videos on YouTube regarding diabetes, complications and lifestyle changes, delivered weekly via WhatsApp over 9 weeks. Videos were available in English, Malay and Chinese. The control group received standard care and counseling. Demographic data, hemoglobin A1c (HbA1c), and knowledge scores were collected at baseline and 3 months post-intervention.

#### RESULTS

A total of 109 patients (62.4% female; mean age 53.2 years; mean diabetes duration 16.3 years) were enrolled in the study, with similar baseline characteristics between groups. The intervention group demonstrated significantly greater improvement in glycemic control compared to the control group (HbA1c:  $-1.22 \pm 1.36\%$  vs.  $-0.24 \pm 1.05\%$ ;  $p < 0.001$ ). While knowledge scores improved in both groups, the increase was significantly greater in the intervention group (2.66 vs. 0.80;  $p = 0.001$ ). Notably, improvement in knowledge score predicted HbA1c reduction ( $b = 0.091$ ; 95% CI 0.01, 0.172;  $p = 0.028$ ).

#### CONCLUSION

The tri-language YouTube-based diabetes education programme significantly improved both glycemic control and patients' knowledge. This accessible, scalable video-based education represents an effective strategy to enhance diabetes self-management, offering flexible, on-demand learning for diverse populations.

## BP\_A002

### EFFECTIVENESS OF DIABETES EDUCATION VIA MOBILE APPLICATION (T-MANIS) IN IMPROVING GLYCEMIC CONTROL AMONG PATIENTS WITH TYPE 2 DIABETES

Tean Chooi Fun<sup>1</sup>, Khaw Chong Hui<sup>1</sup>, Ijaz binti Hallaj Rahmatullah<sup>2</sup>, Lim Phei Ching<sup>1</sup>, Lok Jin Lyn<sup>1</sup>, Song Li Bin<sup>3</sup>, Ye Xiaoyan<sup>3</sup>

<sup>1</sup>Department of Endocrinology, Hospital Pulau Pinang

<sup>2</sup>Department of Endocrinology, Hospital Raja Permaisuri Bainun

<sup>3</sup>Fuzhou Comvee Network & Technology Co. Ltd., Fujian Province, China

#### INTRODUCTION

Current education on diabetes self-management is time-consuming as it is conducted face-to-face. This study aimed to evaluate the effectiveness of diabetes education via mobile application on hemoglobin A1c (HbA1c).

#### METHODOLOGY

This was a double-blinded randomized controlled study conducted in the Department of Endocrinology, Hospital Pulau Pinang and Hospital Raja Permaisuri Bainun. Participants were stratified randomized according to HbA1c to intervention group (using T-Manis) and control group. The primary objective was to assess the difference in HbA1c between the groups. Secondary objectives were to assess the difference in body weight, hospitalization related to diabetes, diabetes knowledge between groups and usability and satisfaction of T-Manis. Laboratory investigations and questionnaires were conducted at baseline, 4 months and 8 months.

#### RESULTS

A total of 112 participants were randomized into two groups each with 56 participants. Mean age was 51 years with similar diabetes duration of 16 years in both groups. Participants comprised of 61.6% females with ethnic distribution of 49.1% Malay, 30.4% Chinese, 19.6% Indian and 0.9% Siamese. Baseline HbA1c levels were comparable between intervention and control groups (10.04% versus 9.91%; mean difference 0.13%; 95% CI -0.56 to 0.81;  $p = 0.718$ ). At 4 months, HbA1c of the intervention group demonstrated a significant reduction compared to the control group (8.93% versus 9.80%; mean difference -0.86; 95% CI -1.59 to -0.14;  $p = 0.02$ ). Sustained reduction of HbA1c in the intervention group was observed at 8 months (mean difference -1.01; 95% CI -1.85 to -0.16;  $p = 0.02$ ). Baseline body weight was 77 kg, with no between-group differences in body weight, hospitalization related to diabetes and diabetes knowledge scores, although diabetes knowledge scores improved at 4 months in the intervention group. 89.3% of participants reported satisfaction with T-Manis.

#### CONCLUSION

The T-Manis mobile application aided in significantly improving glyceemic control with high user satisfaction, supporting its feasibility as an adjunct to standard diabetes care.

## BP\_A003

### HEREDITARY VERSUS SPORADIC MEDULLARY THYROID CARCINOMA: A SINGLE TERTIARY CENTRE COHORT STUDY

Qin Zhi Lee<sup>1</sup>, Raja Nurazni Raja Azwan<sup>1</sup>, Chin Voon Tong<sup>1</sup>, Zanariah Hussein<sup>1</sup>

<sup>1</sup>Endocrinology Unit, Department of Medicine, Hospital Putrajaya

#### INTRODUCTION

Medullary thyroid carcinoma (MTC) comprises sporadic and hereditary forms, the latter commonly associated with multiple endocrine neoplasia type 2 (MEN2) which is identifiable through genetic screening of germline RET proto-oncogene. We compared the clinicopathological features and outcomes of hereditary and sporadic MTC in our single centre.

#### METHODOLOGY

We conducted a retrospective audit of patients with MTC from 2000 to 2026. Patients were classified as either hereditary or sporadic based on genetic testing and/or family history of MTC/MEN2A syndrome. Variables analyzed included age at diagnosis, mode of presentation, pre-operative calcitonin, tumor size, lymph node (LN) involvement, post-operative biochemical cure, repeat surgery and presence of structural residual/recurrent disease.

#### RESULTS

A total of 57 patients were included (18 hereditary [31.6%], 39 presumed sporadic [68.4%]) with a median follow-up of 7.5 years (IQR 1.5–12.4). Hereditary MTC was diagnosed at a significantly younger age than sporadic MTC (33.0 vs. 44.7 years,  $p = 0.010$ ) where 33% of the cases were diagnosed via screening detection whereas sporadic MTC more commonly presented with symptomatic neck swelling (84.6% vs. 50.0%,  $p = 0.008$ ). There were no significant differences in median pre-operative calcitonin (513.5 vs. 1148.0 pg/mL,  $p = 0.101$ ), tumor size (24.5 vs. 22.5 mm,  $p = 0.301$ ), or LN involvement (41.7% vs. 61.5%,  $p = 0.307$ ) between hereditary and sporadic MTC. Long-term outcomes were also comparable, with no differences in biochemical status, need for repeat surgery or residual/recurrent structural disease.

#### CONCLUSION

Hereditary MTC presents earlier and is more frequently detected due to screening, whereas sporadic MTC often presents symptomatically. Long-term outcomes are not primarily determined by hereditary status alone. Early access to RET mutation testing with a view to initiating prophylactic treatments rather than post detection surgery may improve disease burden.

## BP\_A004

### **EFFECTIVENESS OF THE COMPREHENSIVE METABOLIC THERAPY (CoMeT) PROGRAMME ON ANTHROPOMETRIC, METABOLIC AND BODY COMPOSITION IN ADULTS WITH OBESITY: A PILOT PRE-POST STUDY**

**Amie Anne Augustine<sup>1</sup> and Md Syazwan Md Amin<sup>1</sup>**

<sup>1</sup>*Endocrine Unit, Medical Department Hospital Putrajaya*

#### **INTRODUCTION**

Obesity is a complex metabolic condition associated with significant cardiometabolic risks. The Comprehensive Metabolic Therapy (CoMeT) programme is a multidisciplinary intervention designed to address these risks through integrated medical management, physiotherapy, and dietary counseling. This pilot study aimed to evaluate the effectiveness of the CoMeT programme on anthropometric, metabolic, and body composition parameters in adults with obesity.

#### **METHODOLOGY**

We conducted a pilot pre–post study involving 11 adults with obesity (BMI  $\geq 27.5$  kg/m<sup>2</sup>) enrolled in the CoMeT programme at Hospital Putrajaya. Assessments at baseline and post-intervention included anthropometric measures (weight, BMI, waist circumference), metabolic parameters (hemoglobin A1c [HbA1c]), and body composition (skeletal muscle mass [SMM], body fat percentage) using InBody 970 bioelectrical impedance analysis. Data were analyzed using SPSS version 29.0.

#### **RESULTS**

The mean age was  $38.5 \pm 8.9$  years, with baseline weight  $134.7 \pm 20.9$  kg and BMI  $49.8 \pm 9.0$  kg/m<sup>2</sup>. Three participants defaulted follow-up, leaving eight for post-intervention analysis. The mean weight reduction was  $2.1 \pm 6.4$  kg (1.6  $\pm$  5.0%). Notably, the greatest reduction (–12.5%) occurred in a participant with high adherence to both the dietary and physiotherapy components of the intervention. Participants receiving GLP-1 receptor agonists (oral semaglutide) also demonstrated weight reduction (mean –2.5 kg). Conversely, weight gain was observed in some participants despite diet modifications, potentially due to low physiotherapy attendance or baseline metabolic factors. HbA1c improved modestly (–0.19  $\pm$  0.29%). Body composition changes were minimal, with slight reductions in body fat percentage (–0.13  $\pm$  1.2%) and SMM (–0.49  $\pm$  1.88 kg).

#### **CONCLUSION**

The CoMeT programme shows promising early-stage effectiveness in improving anthropometric and metabolic outcomes with the greatest benefits observed in patients achieving high multidisciplinary adherence and adjunct pharmacotherapy. These findings highlight the potential of a multidisciplinary approach in managing high-grade obesity and emphasize the need for larger-scale studies to further validate these outcomes and optimize targeted lifestyle and therapeutic interventions.

## BP\_A005

### THE ROLE OF FREE TRIIODOTHYRONINE TO FREE THYROXINE RATIO IN THE DIFFERENTIAL DIAGNOSIS OF THYROTOXICOSIS: A CROSS-SECTIONAL STUDY

Menon Saiechwaran<sup>1</sup>, Sy Liang Yong<sup>2</sup>, Vijiya Mala Velayutham<sup>3</sup>, Jason Tan Seng Hong<sup>4</sup>, Avni Patel<sup>5</sup>,  
Zienna Zufida binti Zainol Rashid<sup>6</sup>, Hanisah Abdul Hamid<sup>7</sup>, Salbiah binti Mohd Isa<sup>8</sup>, Li Vern Lim<sup>1</sup>

<sup>1</sup>Hospital Tengku Ampuan Rahimah

<sup>2</sup>Endocrine Unit, Hospital Tengku Ampuan Rahimah

<sup>3</sup>Endocrine Unit, Department of Medicine, Hospital Putrajaya

<sup>4</sup>Internal Medicine Department, Hospital Banting

<sup>5</sup>Klinik Kesihatan Pelabuhan Klang

<sup>6</sup>Klinik Kesihatan Pandamaran

<sup>7</sup>Pathology Unit, Hospital Tengku Ampuan Rahimah

<sup>8</sup>Klinik Kesihatan Bandar Botanik

#### INTRODUCTION

Accurate diagnosis of thyrotoxicosis, a condition resulting from excessive thyroid hormone activity, is essential for appropriate management. However, access to diagnostic tools such as thyrotropin receptor antibody (TRAb) assays and thyroid ultrasonography remains limited in resource-constrained settings, highlighting the need for cost-effective alternatives. Recent studies suggest that the free triiodothyronine to free thyroxine (FT3/FT4) ratio may serve as a potential biomarker for differentiating the causes of thyrotoxicosis.

#### METHODOLOGY

This cross-sectional study evaluated the FT3/FT4 ratio in newly diagnosed thyrotoxicosis patients aged  $\geq 18$  years recruited from Hospital Tengku Ampuan Rahimah, Hospital Banting, Klinik Kesihatan Pelabuhan Klang, and Klinik Kesihatan Pandamaran between February and December 2025. All participants underwent thyroid function testing (FT3, FT4, and TSH) and autoantibody assessment (TRAb and anti-thyroid peroxidase [anti-TPO]). Diagnostic performance of the FT3/FT4 ratio for Graves' disease was assessed using receiver operating characteristic (ROC) curve analysis.

#### RESULTS

Fifty-eight patients were included, of whom 58.6% were diagnosed with Graves' disease. Patients with Graves' disease had significantly higher FT3 levels (median 16.8 pmol/L; IQR 10.9–25.7) compared to those with non-Graves' thyrotoxicosis (median 8.3 pmol/L; IQR 5.3–13.5;  $p < 0.001$ ), with similar trends observed for FT4 levels ( $p < 0.001$ ). However, the FT3/FT4 ratio did not differ significantly between groups ( $p > 0.05$ ), with an overall ROC AUC of 0.572, indicating poor discriminatory ability. Subgroup analysis based on FT4 levels improved performance; at FT4  $< 30$  pmol/L, the FT3/FT4 ratio demonstrated 75.0% sensitivity, 91.7% specificity, and 87.5% diagnostic accuracy at a cutoff of 0.3445 (AUC = 0.813; 95% CI: 0.570–1.000;  $p = 0.069$ ). No significant association was observed between the FT3/FT4 ratio and TRAb or anti-TPO.

#### CONCLUSION

The FT3/FT4 ratio has limited overall diagnostic utility but may provide adjunctive value in selected biochemical contexts, particularly in settings with limited access to immunological testing.

## BP\_A006

### REAL-WORLD USE OF TOLVAPTAN IN HYPONATREMIA: A SINGLE-CENTRE EXPERIENCE

Fei Bing Yong<sup>1</sup>, Nur Hidayah Mohd Makhtar<sup>1</sup>, Siew Wai Shuit<sup>1</sup>, Shamharini Nagaratnam<sup>1</sup>, Zanariah Hussein<sup>1</sup>

<sup>1</sup>Endocrine Unit, Medical Department, Hospital Putrajaya

#### INTRODUCTION

Hyponatremia is the most common electrolyte imbalance in hospitalized patients, associated with increased morbidity and mortality. Tolvaptan effectively raises serum sodium in SIADH. However, concerns regarding rapid overcorrection and safety persist. This study evaluates the efficacy, safety, and real-world usage patterns of tolvaptan in a tertiary care setting.

#### METHODOLOGY

A retrospective single-centre observational study was conducted at Hospital Putrajaya using the electronic records of patients treated with tolvaptan from January 2020 to December 2025. Overcorrection was defined as >10 mmol/L increase within 24 hours, and non-response as <4 mmol/L increment at 24 hours.

#### RESULTS

Twenty-one patients were included, with a mean age of 66.7 years; 57% were male. Most (90.5%) received 7.5 mg initially. Mean baseline sodium was  $118.1 \pm 4.1$  mmol/L. Tolvaptan produced rapid correction, with mean sodium increasing to 127.0 mmol/L at 24 hours (mean increment 8.9 mmol/L). Only one patient (4.8%) was a non-responder at 24 hours. Median time to sodium >130 mmol/L was 1 day, with 60% achieving this within 24 hours. At discharge, mean sodium was 130.4 mmol/L. Median length of stay following initiation was 5.5 days. Overcorrection occurred in 23.8% ( $n = 5$ ), all in the 7.5 mg group, particularly among those with baseline sodium 115–120 mmol/L. No cases of osmotic demyelination syndrome (ODS) were observed. The mean interval for initiation is approximately 6 days from diagnosis. Tolvaptan usage increased and peaked in the first 3 years, but subsequently dropped and plateaued over the last 2 years.

#### CONCLUSION

Tolvaptan is safe and effective for sodium correction; although overcorrection remains a risk, no long-term sequelae of ODS were observed, underscoring the need for vigilant monitoring. Its use in Hospital Putrajaya remains limited, with delayed initiation possibly due to tolvaptan being considered a secondary treatment after failure of other options.

## Adult Best Case Report Presentation

### BC\_A001

#### 46 XY GONADAL DYSGENESIS MIMICKING TURNER SYNDROME: DIAGNOSTIC CHALLENGES AND CLINICAL IMPLICATIONS

Suseelah Bala Subramaniam<sup>1</sup>, Rabeah Md Zuki<sup>2</sup>, Loh Hoong Heng<sup>1</sup>

<sup>1</sup>Department of Internal Medicine, Hospital Kulim

<sup>2</sup>Department of Endocrinology, Hospital Sultan Abdul Halim

#### INTRODUCTION

Swyer syndrome (46, XY gonadal dysgenesis) is a rare disorder of sex development, characterized by a phenotypic female with streak gonads and hypergonadotropic hypogonadism. It presents with primary amenorrhea and delayed puberty. Overlapping clinical features with Turner syndrome may cause diagnostic uncertainty, highlighting the role of karyotypic evaluation in diagnosis.

#### CASE

A 35-year-old phenotypic female was first evaluated at age 27 during admission for an acute viral illness, when incidental findings of primary amenorrhea, short stature (height 131 cm), webbed neck, pectus excavatum, and absent secondary sexual characteristics raised suspicion of Turner syndrome. She had hypertension, with initial imaging suggesting coarctation of the thoracic aorta. CT angiography showed focal narrowing of the descending aorta; multidisciplinary review favored aortic folding, and she was managed conservatively. Endocrine evaluation demonstrated hypergonadotropic hypogonadism, with markedly elevated follicle-stimulating hormone (FSH 108.6 IU/L) and luteinizing hormone (LH 23.16 IU/L) in the presence of low estradiol levels. Pelvic imaging revealed an atrophic uterus with absence of bilateral ovaries, consistent with gonadal dysgenesis. Karyotypic analysis was performed, demonstrating a 46, XY genotype with confirmed SRY gene presence, establishing the diagnosis of Swyer syndrome. DEXA scan demonstrated osteoporosis, in keeping with prolonged hypogonadism. She was commenced on hormone replacement therapy, resulting in the development of secondary sexual characteristics and regular withdrawal bleeding. She remains under structured multidisciplinary follow-up, with endocrine-led management of hypothyroidism and osteoporosis, alongside cardiology follow-up and gynecological surveillance.

#### CONCLUSION

This case highlights the diagnostic complexity of disorders of sex development with overlapping phenotypes and the need for re-evaluation when clinical progression is atypical. Diagnosis enables hormone replacement therapy for induction of secondary sexual characteristics and preservation of bone health. Integration of clinical, biochemical, and genetic data within a multidisciplinary framework is essential to achieve diagnostic accuracy and optimize outcomes.

## BC\_A002

### DIVERGENT OUTCOMES OF RESCUE THERAPEUTIC PLASMA EXCHANGE IN REFRACTORY THYROID STORM: A CASE SERIES

Mas Suria Mat Daud<sup>1</sup>, Teh Roseleen Nadia Roslan<sup>1</sup>, Marisa Khatijah Borhan<sup>1</sup>, Norhayati Yahaya<sup>1</sup>

<sup>1</sup>Endocrine Unit, Hospital Raja Perempuan Zainab II

#### INTRODUCTION

Managing thyroid storm requires aggressive multimodal therapy. However, options become exceptionally narrow when absolute contraindications to antithyroid drugs (ATDs) exist or standard therapy fails. In these refractory scenarios, therapeutic plasma exchange (TPE) serves as a critical rescue modality to optimize clinical and biochemical status. Despite its use, reported efficacy remains inconsistent.

#### CASES

A 56-year-old female with Graves' disease presented with thyroid storm (BWPS 60) complicated by high-output heart failure and distributive shock. Deterioration into acute liver failure (ALF) necessitated ATD discontinuation. TPE and Continuous Venovenous Hemofiltration (CVVH) were initiated at 40 hours. Following three TPE cycles, fT<sub>4</sub> (freeT<sub>4</sub>) reduced by 6.7, 6.5, and 23% sequentially, leading to marked clinical stabilization and recovery.

A 31-year-old female with Graves' disease presented with thyroid storm (BWPS 90), pneumonia, and refractory tachycardia. Rising transaminases precluded ATD use. TPE was initiated at 48 hours, achieving a 55% fT<sub>4</sub> reduction after 2 cycles and initial clinical stabilization. However, her course was complicated by a subdural hemorrhage requiring craniectomy; she eventually succumbed to nosocomial infection.

A 27-year-old female with Graves' disease presented with jaundice and altered sensorium (BWPS 45). Due to baseline ALF, ATDs were withheld. TPE was initiated early as a bridge to potential liver transplantation, achieving a significant 72% fT<sub>4</sub> reduction after two cycles. Despite biochemical success, she succumbed to irreversible multi-organ failure.

#### CONCLUSION

Literature indicates that TPE achieves a mean fT<sub>4</sub> reduction of 51.9% over four cycles. Our series demonstrated wide variability (23–72% over 2–3 cycles), reflecting unpredictable clearance dynamics. While TPE is an effective adjunctive tool for rapid biochemical optimization, the ultimate prognosis is heavily contingent on the timing of initiation. As seen in Cases 2 and 3, significant biochemical clearance may not reverse systemic damage once advanced neurological or hepatic failure ensues.

## BC\_A003

### SOLVING THE UNLOCALIZED PARATHYROID: EXPERIENCE WITH SELECTIVE VENOUS SAMPLING IN THREE PATIENTS

Yee Weai Cheong<sup>1</sup>, Hwee Ching Tee<sup>1</sup>, Ho Jin Hui<sup>1</sup>, Shireen Siow Leng Lui<sup>1</sup>, Aida Shazlin Binti Hamiddin<sup>2</sup>, Siti Zubaidah Sharif<sup>3</sup>

<sup>1</sup>Diabetes and Endocrine Unit, Department of Medicine, Hospital Queen Elizabeth II

<sup>2</sup>Radiology Department, Hospital Queen Elizabeth

<sup>3</sup>Breast and Endocrine Unit, Department of Surgery, Hospital Queen Elizabeth II

#### INTRODUCTION

Accurate preoperative localization is essential for the surgical management of primary hyperparathyroidism (PHPT). Although ultrasound, technetium-99m sestamibi scintigraphy, and 4D-CT provide high localization rates, a subset of patients have non-localizing or discordant imaging. Selective parathyroid venous sampling (PVS) is an invasive adjunct that measures regional parathyroid hormone (PTH) gradients to aid localization in challenging cases. We present a three-patient case series demonstrating the utility of PVS in diagnostically complex PHPT.

#### CASES

We retrospectively reviewed three female patients (ages 44–63) with biochemically confirmed PHPT who underwent selective PVS following negative or discordant imaging. Venous sampling was performed via femoral access with catheterization of bilateral internal jugular, brachiocephalic, and bilateral thyroidal veins. PTH levels were measured at each site and compared to peripheral levels to identify regional gradients. Surgical findings, intraoperative parathyroid hormone monitoring (IOPTH), histopathology, and postoperative biochemical outcomes were recorded.

All patients had non-localizing or discordant preoperative imaging (USG, sestamibi, 4D-CT). PVS identified significant PTH gradients, guiding focused parathyroidectomy. IOPTH monitoring confirmed successful excision in all operated patients. Histopathology confirmed parathyroid adenoma in two cases; in the third case, the parathyroid tissue was identified within the thyroid gland. Postoperative PTH levels suppressed (range 0.79–1.48 pg/mL) in keeping with successful parathyroidectomy.

#### CONCLUSION

PVS effectively lateralized disease in imaging-negative PHPT and directly guided surgical management. When conventional imaging fails, PVS combined with intraoperative PTH monitoring enables targeted surgery and favorable biochemical outcomes.

## BC\_A004

### SUPRASellar MOGAD: RARE ENDOCRINE MANIFESTATIONS OF HYPOPIUITARISM AND DIABETES INSIPIDUS

Sing Yee Sim<sup>1,2</sup>

<sup>1</sup>Endocrine Unit, Sarawak General Hospital

<sup>2</sup>Universiti Malaysia Sarawak (UNIMAS)

#### INTRODUCTION

Myelin oligodendrocyte glycoprotein antibody-associated disease (MOGAD) is an uncommon inflammatory demyelinating disorder of the central nervous system, with a reported prevalence of 1.3–2.5 per 100,000. Hypothalamic–pituitary involvement is rare and can mimic structural lesions, presenting with varying degrees of hypopituitarism and central diabetes insipidus.

#### CASE

A 30-year-old male presented with a 2-year history of poor concentration, blurring of vision and lethargy. Initial investigations revealed severe hyponatremia (serum sodium 165 mmol/L) and a 1.4 × 2.1 × 1.3 cm suprasellar cistern mass on CT scan, with differential diagnoses including meningioma and germinoma. Brain magnetic resonance imaging showed abnormal signals in the optic pathways and hypothalamus, raising suspicion of a demyelinating process.

Endocrine evaluation confirmed panhypopituitarism: elevated prolactin (1125.2 mIU/L), hypogonadotropic hypogonadism (follicle-stimulating hormone 0.7 IU/L, LH 0.3 IU/L, testosterone <0.35 nmol/L), central hypothyroidism (TSH 3.8 mIU/L, free T4 5.88 pmol/L) and low cortisol (33.1 nmol/L). Persistent hyponatremia (up to 171 mmol/L) with high serum osmolality (370 mOsm/kg) and low urine osmolality (237 mOsm/kg) confirmed central diabetes insipidus, as urine osmolality rose to 755 mOsm/kg following intravenous desmopressin.

He was commenced on sublingual desmopressin 60 micrograms twice daily, hydrocortisone (10 mg morning, 5 mg afternoon), levothyroxine 75 micrograms daily and monthly intramuscular testosterone 150 mg. Subsequent readmissions for generalized weakness and fever led to cerebrospinal fluid analysis and serum testing, which were positive for MOG antibodies and negative for aquaporin-4 antibodies, confirmed MOGAD.

During a third admission with recurrent generalized weakness, he responded favorably to intravenous methylprednisolone (1 g daily for 5 days), followed by a tapering oral prednisolone regimen.

#### CONCLUSION

MOGAD can involve the hypothalamic–pituitary axis and mimic a suprasellar mass. In patients with panhypopituitarism, central diabetes insipidus and compatible imaging, inflammatory demyelination should be suspected. MOG antibody positivity and response to corticosteroids support diagnosis and guide management.

## BC\_A005

### PITUITARY-DRIVEN GONADAL HYPERSTIMULATION: A RARE PRESENTATION OF FUNCTIONING GONADOTROPH ADENOMA

Nurbadriah Jasmiad<sup>1</sup>, Wei Wei Ng<sup>1</sup>, Anilah Abdul Rahim<sup>1</sup>, Ijaz Hallaj Rahmatullah<sup>1</sup>

<sup>1</sup>Endocrinology Unit, Hospital Raja Permaisuri Bainun

#### INTRODUCTION

Functioning gonadotroph adenomas, also known as follicle-stimulating hormone (FSH)-secreting pituitary adenomas (FSH-omas), are rare pituitary tumors characterized by the secretion of biologically active FSH. Unlike the more common clinically nonfunctioning gonadotroph adenomas, these tumors produce endocrine manifestations due to excessive FSH secretion. Clinical presentation may result from local mass effects such as headache, visual disturbances due to optic chiasmal compression, or from hormonal activity affecting reproductive function. The endocrine manifestations vary between males and females and can lead to diagnostic challenges.

#### CASES

We report two patients with functioning gonadotroph adenomas presenting with distinct clinical manifestations. The first case involved a 23-year-old female who presented with secondary amenorrhea for 4 years, accompanied by personality changes. Abdominal ultrasound demonstrated bilaterally enlarged multicystic ovaries suggestive of ovarian hyperstimulation, which subsequently regressed postoperatively. Biochemical evaluation revealed inappropriately elevated FSH levels (3.5-fold increase), with suppressed luteinizing hormone (LH) and markedly elevated estradiol levels (11-fold increase). Pituitary magnetic resonance imaging (MRI) identified a large sellar-suprasellar mass with mass effect, consistent with a pituitary macroadenoma.

The second case involved a 68-year-old male who presented with progressively worsening vision over 2 years. Hormonal evaluation demonstrated elevated FSH levels (4.5-fold increase), with relatively normal LH and low testosterone levels. Pituitary MRI revealed a sellar mass consistent with a pituitary adenoma. Both patients subsequently underwent pterional craniotomy with tumor debulking. Histopathological examination confirmed gonadotroph adenomas, with positive immunohistochemical staining for FSH.

#### CONCLUSION

Functioning gonadotroph adenomas are rare and may present with diverse clinical features related to gonadal hyperstimulation or mass effects. Early recognition of the characteristic hormonal profile and radiological findings is crucial for diagnosis and appropriate management. These cases highlight the importance of considering functioning gonadotroph adenoma in patients presenting with unexplained gonadal hyperstimulation or atypical reproductive hormonal profiles.

## BC\_A006

### PROTEINURIA AND HYPOTHYROIDISM: TWO CASES ILLUSTRATING A BIDIRECTIONAL THYROID-KIDNEY RELATIONSHIP

Manoharan Thunishsha<sup>1</sup> and Yueh Kuan<sup>1</sup>

<sup>1</sup>Endocrine Unit, Miri Hospital

#### INTRODUCTION

The thyroid-kidney axis represents a clinically significant bidirectional relationship. Nephrotic syndrome (NS) may induce hypothyroidism via urinary hormonal and binding protein losses, while severe hypothyroidism may mimic NS and contribute to renal dysfunction.

#### CASES

A 64-year-old male with gout, presented with facial puffiness, pedal edema, weight gain and frothy urine. Investigations revealed severe hypothyroidism FT4 <0.5 pmol/L (12–22 pmol/L) TSH 314 mIU/L (0.27–4.2 mIU/L) with NS – UPCR 7.73 g/L (0.04–0.15 g/L), albumin 22 g/L, total cholesterol 15.9 mmol/L – and renal impairment (eGFR 58 mL/min/1.73 m<sup>2</sup>). Positive anti-TPO antibodies suggested Hashimoto's thyroiditis. He was initiated on liothyronine, hydrocortisone, levothyroxine and diuretics. Although FT4 normalized (14.4 pmol/L) a month later, renal function worsened requiring dialysis. Further evaluation including renal biopsy demonstrated IgA nephropathy as the underlying cause of NS and renal failure. Treatment with prednisolone led to gradual improvement in renal function and proteinuria (UPCR 0.21 g/L).

A 73-year-old male with hypothyroidism diagnosed 6 months prior (FT4 11.9 pmol/L, TSH 7.23 mIU/L) for thyroxine replacement, diabetes, hypertension, dyslipidemia and CKD presented with anasarca, decompensated heart failure, pleural and pericardial effusions requiring ventilatory and inotropic support. On admission, he had marked hypothyroidism (FT4 2.9 pmol/L and TSH 97.2 mIU/L) and moderate proteinuria (UPCR 0.81 g/L). He was similarly treated with liothyronine, hydrocortisone and levothyroxine. Renal function initially deteriorated (creatinine 439 µmol/L, eGFR 11 mL/min/1.73 m<sup>2</sup>) but later returned to baseline with clinical recovery. Despite normalization of FT4 months later, proteinuria persisted; but renal function remained stable.

#### CONCLUSION

These cases highlight the overlapping manifestations of severe hypothyroidism and renal dysfunction with proteinuria. Each may mimic or exacerbate the other. NS may unmask underlying hypothyroidism. While inadequately treated hypothyroidism can worsen proteinuric CKD exacerbating hypothyroidism. Concurrent evaluation of both systems is essential to prevent misdiagnosis and guide timely management.

## Adult E-poster

### EP\_A002

#### EVALUATION OF MORNING CORTISOL IN DIAGNOSIS AND MANAGEMENT OF ADRENAL INSUFFICIENCY IN A TERTIARY HOSPITAL IN CENTRAL PAHANG

Saravanaa Nalliah<sup>1</sup> and See Chee Keong<sup>1</sup>

<sup>1</sup>Hospital Raub, Hospital Sultan Haji Ahmad Shah

##### INTRODUCTION

Adrenal insufficiency (AI) is a life-threatening condition that frequently presents with non-specific symptoms, complicating early diagnosis. Morning serum cortisol serves as an effective initial screening tool for assessing the hypothalamic-pituitary-adrenal (HPA) axis, potentially reducing the necessity for dynamic investigations such as the Short Synacthen Test (SST). This study aims to assess the clinical indications for morning cortisol testing and evaluate institutional compliance with guideline-based cortisol cut-offs, the initiation of hydrocortisone therapy, and the provision of “sick day” education.

##### METHODOLOGY

A retrospective cross-sectional study was conducted among inpatients at a tertiary hospital in Central Pahang who underwent morning cortisol evaluation between March and August 2025. Data regarding demographics, indications, biochemical results, and clinical management were analyzed using SPSS version 26.0.

##### RESULTS

Among the 111 patients included (mean age: 54.96 ± 15.88 years), the primary indications for testing were hyponatremia (54.1%), hypotension (27.9%), and a history of traditional medication use (26.1%). Based on Endocrine Society guidelines: <150 nmol/L (AI likely): 16.2%, 150–300 nmol/L (Borderline): 26.1%, and >300 nmol/L (AI unlikely): 57.7%. Notably, only 10 of the 18 patients with cortisol levels <150 nmol/L were formally diagnosed and initiated on appropriate therapy. In the borderline group, only two patients underwent an SST. Although 12 patients overall were treated for AI, only eight received documented “sick day” education. Low cortisol levels were significantly associated with hyponatremia, hypotension, and traditional medication use, and demonstrated a negative correlation with serum sodium and albumin levels.

##### CONCLUSION

Morning serum cortisol is a valuable screening tool for AI, particularly in patients presenting with hyponatremia or hypotension. However, significant gaps persist in follow-up management, confirmatory testing, and patient education. Implementing standardized protocols and enhancing clinician education are essential to optimize care.

### EP\_A003

#### PRIMARY ALDOSTERONISM IN A MALAYSIAN TERTIARY CENTRE: A RETROSPECTIVE AUDIT OF CLINICAL CHARACTERISTICS, DIAGNOSTIC PATHWAYS, AND TREATMENT OUTCOMES (2018–2025)

Ahmad Hambal Bin Zamari<sup>1</sup> and Yusniza Yusoff<sup>1</sup>

<sup>1</sup>Endocrine Unit, Hospital Sungai Buloh

##### INTRODUCTION

Primary aldosteronism (PA) is a common yet under-diagnosed cause of secondary hypertension, associated with increased cardiovascular and renal morbidity. Early detection and subtype-directed management significantly improve outcomes. However, adherence to recommended diagnostic pathways in real-world practice remains variable.

##### CASE

We conducted a retrospective audit of patients diagnosed with PA in a Malaysian tertiary centre from January 2018 to December 2025. Data collected included demographics, clinical presentation, biochemical parameters, diagnostic workup (aldosterone-renin ratio [ARR], confirmatory testing, adrenal imaging, and adrenal venous sampling [AVS]), treatment modality, and outcomes. Audit standards were based on established international guidelines.

A total of 14 patients were included, with equal gender distribution. The cohort comprised 57% Malay and 43% Chinese. Most patients presented with hypertension (mean ~170/100 mmHg), and hypokalemia was present in approximately 70% of the patients. ARR and adrenal imaging were performed in all patients (100%), while confirmatory testing was conducted in 85% of the patients. However, AVS utilization remained limited (50%). Contributing factors included failed cannulation, technical challenges in overweight patients, preference for medical therapy, refusal of surgery, and limited access to AVS services. The majority had unilateral adrenal adenoma (~75%). Treatment was divided between surgical (55%) and medical (45%) approaches. Post-treatment, hypokalemia resolved in 90% of patients, with a significant reduction in antihypertensive burden and complete hypertension resolution in approximately 35% of the patients. Quality of life improved in most patients.

##### CONCLUSION

This audit demonstrates good adherence to initial screening and imaging in PA but highlights suboptimal utilization of AVS. Barriers to AVS utilization are multifactorial, encompassing technical, patient-related, and system-

level limitations. Addressing these barriers is essential to optimize subtype-directed management and improve long-term cardiovascular outcomes in patients with PA. Despite this, clinical outcomes were favorable. Strengthening adherence to diagnostic pathways, particularly subtype confirmation, may further improve patient outcomes.

## EP\_A004

### SINGLE-STAGE ADRENALECTOMY AND HYSTERECTOMY FOR PHEOCHROMOCYTOMA WITH GIANT UTERINE FIBROID: A MULTIDISCIPLINARY PERIOPERATIVE CHALLENGE

Fei Bing Yong<sup>1</sup>, Sarojini Devi Simanchalam<sup>2</sup>, Hidayatil Alimi Keya Nordin<sup>1</sup>, Nithiya Devi Kandasami<sup>3</sup>, Sadhana Sadar Mahamad<sup>3</sup>, Suhaimi Jaafar<sup>4</sup>, Mohd Wajdi Zanuddin<sup>1</sup>, Poh Shean Wong<sup>2</sup>, Chin Voon Tong<sup>1</sup>, Noor Lita Adam<sup>2</sup>, Zanariah Hussein<sup>1</sup>

<sup>1</sup>Endocrine Unit, Medical Department, Endocrine Institute Hospital Putrajaya

<sup>2</sup>Endocrine Unit, Medical Department, Hospital Tuanku Jaafar

<sup>3</sup>Endocrine and Breast Surgery, Surgical Department, Hospital Putrajaya

<sup>4</sup>Anaesthesiology Department, Hospital Putrajaya

<sup>5</sup>Obstetrics and Gynaecology Department, Hospital Putrajaya

#### INTRODUCTION

Pheochromocytoma is a catecholamine-secreting adrenal tumor associated with major perioperative hemodynamic instability. When concurrent major pelvic pathology requires surgery, operative planning becomes particularly challenging. We describe the successful single-stage management of pheochromocytoma and a giant uterine fibroid, highlighting the importance of multidisciplinary coordination and perioperative optimization.

#### CASE

A 49-year-old female with symptomatic uterine fibroid was found to have proliferative endometrium on a pipelle biopsy. Computed tomography (CT) abdomen incidentally detected a right adrenal mass alongside a large posterior uterine fibroid (11.9 × 17.4 × 14.6 cm). CT adrenal protocol demonstrated a heterogeneously enhancing right adrenal mass (6.9 × 6.9 × 9.6 cm) with high unenhanced attenuation. Biochemical evaluation revealed markedly elevated 24-hour urinary metanephrine (4.7× upper limit) and normetanephrine (2.4× upper limit).

Following multidisciplinary discussions, a single-stage surgical approach was planned after careful assessment of feasibility and perioperative risk in view of the uncertain

malignant potential of the pelvic mass and to minimize repeated exposure to anesthesia. Preoperative optimization included transitioning from terazosin to phenoxybenzamine, with subsequent addition of bisoprolol for hemodynamic control. The operative strategy prioritized pheochromocytoma resection first, given its potential for significant hemodynamic instability. Progression to hysterectomy was contingent upon achieving adequate intraoperative hemodynamic stability following adrenalectomy, with continuous reassessment by the anesthetic and surgical teams.

Right adrenalectomy was performed first, followed by total abdominal hysterectomy with bilateral salpingo-oophorectomy. Significant hemodynamic lability occurred during tumor manipulation, with hypertensive surges managed using sodium nitroprusside and remifentanyl infusions. Following adrenal vein ligation and tumor removal, hypotension was managed with noradrenaline and additional adrenaline support as required. Total operative time was approximately 6 hours. Postoperatively, transient noradrenaline support was required but was rapidly weaned as hemodynamic stability was achieved.

#### CONCLUSION

Single-stage adrenalectomy and major pelvic surgery can be safely performed in selected patients with pheochromocytoma when guided by meticulous preoperative optimization, clear intraoperative sequencing, and close multidisciplinary coordination.

## EP\_A005

### MIMICKING PHEOCHROMOCYTOMA: HYPERTENSIVE CRISIS FROM ADRENAL HEMATOMA IN JAK2-POSITIVE POLYCYTHEMIA RUBRA VERA

Dhanya Ganesan<sup>1</sup>, Hwee Ching Tee<sup>1</sup>, Jin Hui Ho<sup>1</sup>, Shireen Siow Leng Lui<sup>1</sup>

<sup>1</sup>Diabetes and Endocrine Unit, Department of Medicine, Hospital Queen Elizabeth II

#### INTRODUCTION

Hemorrhagic suprarenal masses presenting with hypertensive emergency pose a significant diagnostic challenge, particularly when biochemical and radiological findings are inconclusive. The clinical presentation may mimic catecholamine-secreting tumors, necessitating consideration of a broad differential diagnosis, including pheochromocytoma, adrenocortical carcinoma, retroperitoneal hemorrhage, and hematological-related extramedullary lesions. Accurate diagnosis is essential, as management strategies differ significantly.

## CASE

We report a 48-year-old male smoker with no known prior medical illness who presented with sudden left-sided chest pain radiating to the epigastrium, associated with vomiting. On arrival, he was markedly hypertensive (207/131 mmHg). He reported a 1-year history of paroxysmal palpitations, headaches, migraines, and intermittent diaphoresis. Computed tomography angiography excluded aortic dissection but demonstrated a left retroperitoneal hemorrhage with non-visualization of the adrenal gland, suggestive of adrenal or tumor-related hemorrhage.

He was initially managed empirically as a pheochromocytoma while undergoing biochemical evaluation; however, urinary metanephrines were only mildly elevated. Repeat imaging demonstrated interval enlargement of a non-enhancing suprarenal mass, raising concern for tumor-related hemorrhage. Subsequent ultrasonography, however, favored a liquefied hematoma, and percutaneous drainage yielded 750 mL of sanguineous fluid, resulting in marked clinical improvement.

Notably, an elevated hematocrit prompted further evaluation for erythrocytosis. Subsequent testing confirmed JAK2 mutation-positive polycythemia rubra vera, providing a unifying explanation for both the erythrocytosis and spontaneous adrenal hemorrhage. The patient was commenced on hydroxyurea and referred for hematology follow-up.

## CONCLUSION

Adrenal hemorrhage may closely mimic pheochromocytoma in hypertensive emergencies. A systematic, multidisciplinary approach integrating clinical, biochemical, and imaging findings is essential to avoid misdiagnosis and guide appropriate management, particularly in patients with underlying hematological disorders.

## EP\_A006

### TWO HEARTBEATS, ONE TUMOR: NON-FUNCTIONING ADRENOCORTICAL TUMOR IN PREGNANCY

Nur Nisrina Yahya<sup>1</sup> and Noor Rafhati Adyani  
Abdullah<sup>1</sup>

<sup>1</sup>Hospital Sultanah Bahiyah

## INTRODUCTION

Adrenocortical carcinoma (ACC) is a rare and aggressive malignancy, with an incidence of 1–2 cases per million annually. Its occurrence during pregnancy is exceptionally

uncommon, presenting significant diagnostic and management challenges due to overlapping physiological changes and concerns for both maternal and fetal outcomes. While most cases are hormonally functional, non-functioning ACC during pregnancy is particularly rare and may result in delayed diagnosis.

## CASE

A 35-year-old Malay female was referred following ultrasonography for persistent back and left flank pain, which revealed a left adrenal incidentaloma and a concurrent 10-week intrauterine pregnancy. There were no clinical signs of hormone excess. Physical examination revealed a normotensive patient with a large, palpable left abdominal mass, without Cushingoid or virilizing features.

Magnetic resonance imaging (MRI) demonstrated a 12.1 × 10.3 × 12.8 cm heterogeneous left adrenal mass with cystic and necrotic components, displacing adjacent structures. Hormonal evaluation was within normal limits: 24-hour urinary cortisol 320.2 nmol/24 hours (reference range [RR] 11.8–350), midnight salivary cortisol <3 and 4.2 nmol/L (RR <11.3), plasma metanephrine <0.2 nmol/L (RR <0.5), normetanephrine 0.6 nmol/L (RR <0.9), and 17-hydroxyprogesterone 223 ng/dL (RR <285), consistent with a non-functioning tumor.

Following multidisciplinary consultation, the patient underwent open left adrenalectomy at 16 weeks' gestation. Histopathological analysis confirmed ACC (Weiss score 8/9) without extra-adrenal extension. Surveillance MRI at 32 weeks demonstrated no recurrence or residual mass. At 40 weeks' gestation, she delivered a healthy infant, and both mother and child remain well on follow-up.

## CONCLUSION

Non-functioning ACC during pregnancy is rare and poses significant diagnostic challenges. Early imaging, comprehensive hormonal assessment, and timely surgical intervention during the second trimester are essential. Multidisciplinary management is crucial to optimizing maternal and fetal outcomes.

## EP\_A007

### WHEN NSTEMI IS NOT CORONARY DISEASE: MINOCA REVEALING PHEOCHROMOCYTOMA

Shaleela Mohd Esha<sup>1</sup>, Hazwani Aziz<sup>1</sup>, Elliyyin Katiman<sup>1</sup>

<sup>1</sup>Hospital Tengku Permaisuri Norashikin, Kajang

#### INTRODUCTION

Pheochromocytoma is a catecholamine-secreting tumor with diverse cardiovascular manifestations, including myocardial infarction with non-obstructive coronary arteries (MINOCA). We report a case of biochemically confirmed pheochromocytoma initially presenting as non-ST-elevation myocardial infarction (NSTEMI), later reclassified as MINOCA.

#### CASE

A 62-year-old female with type 2 diabetes mellitus and hypertension was admitted with presumed NSTEMI and commenced on dual antiplatelet therapy. Further history revealed recurrent presyncope associated with paroxysmal headache, palpitations, and profuse diaphoresis. During admission, her blood pressure was markedly labile, ranging from 75/45 to 220/122 mmHg, raising suspicion of pheochromocytoma. Biochemical evaluation demonstrated markedly elevated 24-hour urinary normetanephrine of 36.19  $\mu\text{mol}/\text{day}$  (reference 0–2.13) and methoxytyramine of 3.90  $\mu\text{mol}/\text{day}$  (reference 0.10–1.79), consistent with catecholamine excess. Dedicated adrenal computed tomography identified a 3.8-cm right adrenal lesion with high attenuation (44 Hounsfield Unit [HU]), arterial enhancement (119 HU), and low washout (absolute 40%, relative 24%), without calcification or necrosis. Electrocardiography showed sinus rhythm with T-wave inversion in leads I, aVL, and V5–V6. Transthoracic echocardiography demonstrated a preserved left ventricular ejection fraction of 67% without regional wall-motion abnormalities. Coronary angiography subsequently showed normal coronary arteries, supporting a diagnosis of MINOCA likely secondary to pheochromocytoma-related catecholamine excess and hypertensive crisis. Antiplatelets were discontinued. She was commenced on  $\alpha$ -blockade, with additional felodipine and low-dose  $\beta$ -blocker for blood pressure optimization, and subsequently underwent successful open right adrenalectomy. Postoperatively, she required transient inotropic support but was weaned within 36 hours.

#### CONCLUSION

Pheochromocytoma-associated MINOCA is uncommon but important to recognize. Catecholamine surges may cause myocardial injury through coronary vasospasm,

myocardial oxygen supply-demand mismatch, and direct catecholamine-mediated cardiotoxicity. Recognition is crucial, as management differs fundamentally from atherosclerotic acute coronary syndrome and requires  $\alpha$ -blockade before  $\beta$ -blockade.

## EP\_A008

### THE DOPAMINE DILEMMA: EXOGENOUS L-DOPA OR RARE DOPAMINOMA?

Amal Hanani Abdul Halim<sup>1</sup> and Farhi Ain Jamaluddin<sup>1</sup>

<sup>1</sup>Department of Laboratory Medicine and Department of Pathology, Faculty of Medicine, University Malaya

#### INTRODUCTION

Dopaminomas or dopamine-secreting pheochromocytomas are rare neuroendocrine tumors that frequently lack the classic paroxysmal symptoms of catecholamine excess (headache, sweating, palpitation). Diagnosing these tumors is exceptionally challenging when biochemical markers—specifically markedly elevated urinary dopamine—are interpreted in patients receiving exogenous Levodopa (L-DOPA) therapy, as the intake obscures clinical significance.

#### CASE

A 76-year-old male with ischemic heart disease, stage 4 chronic kidney disease, and new-onset hypertension was admitted for acute cholecystitis. Imaging studies incidentally revealed bilateral adrenal masses and demonstrated lipid-rich characteristics upon further evaluation with computed tomography (CT) adrenal washout. Biochemical evaluation revealed extreme elevations in 24-hour urinary dopamine (47,534 nmol/24 hours; normal <3,237) and 3-methoxytyramine (18.93  $\mu\text{mol}/24$  hours; normal <2.60), whereas downstream urinary noradrenaline (5.0 nmol/24 hours; normal 71.5–505.3), adrenaline (4.0 nmol/24 hours; normal 9.2–122.3), normetanephrine (0.22  $\mu\text{mol}/24$  hours; normal 0.88–2.88), and metanephrine (0.25  $\mu\text{mol}/24$  hours; normal 0.33–1.53) levels were all significantly below their respective reference ranges. The diagnosis was complicated by the patient's concurrent use of L-DOPA/Benserazide for flupentixol-induced parkinsonism. L-DOPA is a direct precursor to dopamine; its administration can cause massive, false-positive elevations in urinary dopamine, mimicking a dopaminoma's biochemical signature. However, the unique combination of profoundly high dopamine alongside suppressed downstream catecholamines and metanephrines suggested a true dopamine-secreting tumor—potentially secondary to dopamine beta-hydroxylase (DBH) deficiency—rather than drug interference.

## CONCLUSION

This case illustrates the profound difficulty in diagnosing dopaminoma when exogenous L-DOPA therapy creates a near-identical biochemical profile. The diagnostic dilemma is further amplified by vague symptomatology, multiple comorbidities, and non-suggestive imaging. However, the finding of isolated dopamine hypersecretion with suppressed metanephrines serves as a critical clinical clue. This pattern points toward an intratumoral biosynthetic defect rather than drug interference. Clinicians must maintain a high index of suspicion and perform meticulous biochemical fractionation to identify these rare, dopamine-isolated secreting tumors.

## EP\_A009

### THE HEMODYNAMIC PARADOX: SYNCHRONOUS ROBOTIC SURGERY FOR NORMOTENSIVE PHEOCHROMOCYTOMA IN VHL

Thiru Murugaan Balakrishnan<sup>1</sup>, Nurbadriah Jasmiah<sup>1</sup>, Ng Wei Wei<sup>1</sup>, Anilah Abdul Rahim<sup>1</sup>, Ijaz Hallaj Rahmatullah<sup>1</sup>, Subashini Rajoo<sup>2</sup>

<sup>1</sup>Hospital Raja Permaisuri Bainun

<sup>2</sup>Hospital Kuala Lumpur

## INTRODUCTION

Normotensive pheochromocytomas in Von Hippel-Lindau (VHL) syndrome present unique perioperative challenges. Standard alpha-blockade may induce intolerable orthostatic hypotension, making calcium channel blockers (CCB) a practical alternative. Furthermore, the primary intraoperative danger in these specific phenotypes may not be a hypertensive crisis, but profound vasoplegia. We report a VHL patient undergoing synchronous robotic surgery exhibiting this paradoxical hemodynamic response.

## CASE

A 37-year-old female with VHL syndrome presented with an incidental 3.5-cm left adrenal mass and bilateral renal masses. Biochemistry confirmed a normotensive, noradrenergic pheochromocytoma (24-hour urine normetanephrines 4.2x upper limit of normal). Renal biopsy revealed a clear cell papillary renal cell tumor. Due to prior severe intolerance to Prazosin (hypotension/dizziness with low-dose Prazosin 0.5 mg ON), we utilized amlodipine for preoperative optimization. She was only able to tolerate low-dose 2.5 mg OD alongside oral sodium chloride and ample oral fluid loading. She underwent a synchronous robotic-assisted left adrenalectomy and left midpole renal tumor excision. Strikingly, tumor manipulation did not precipitate a hypertensive crisis. Instead, she developed hypotension requiring an intravenous noradrenaline

infusion prior to adrenal vein ligation and tumor removal. Vasopressor support was successfully weaned 12 hours postoperatively, and she was discharged well.

## CONCLUSION

Normotensive, noradrenergic pheochromocytomas in VHL are hemodynamically fragile. Chronic catecholamine excess induces homologous desensitization and downregulation of alpha-1 adrenergic receptors. This physiological adaptation explains the normotensive presentation and highlights the intraoperative vasoplegia experienced once sympathetic tone is altered by anesthesia. While CCB monotherapy with volume expansion safely facilitates prolonged, synchronous robotic surgeries, clinicians must anticipate and combat refractory hypotension rather than classical hypertensive spikes.

## EP\_A010

### DISSEMINATED HISTOPLASMOSIS PRESENTING AS ADDISONIAN CRISIS: A DIAGNOSTIC MIMIC OF TUBERCULOSIS WITH BILATERAL ADRENAL MASSES

Aminuddin Baki Amran<sup>1</sup>, Nur Aini Eddy Warman<sup>1</sup>, Aimi Fadilah Mohamad<sup>1</sup>, Nur Haziqah Baharum<sup>1</sup>, Mohd Hazriq Awang<sup>1</sup>, Fatimah Zaherah Mohamed Shah<sup>1</sup>, Rohana Abdul Ghani<sup>1</sup>

<sup>1</sup>Department of Internal Medicine, Faculty of Medicine, Universiti Teknologi MARA

## INTRODUCTION

Disseminated histoplasmosis is a rare but important cause of adrenal insufficiency (AI), particularly in tuberculosis (TB)-endemic regions, where it may mimic granulomatous diseases. Adrenal involvement occurs in up to 80% of disseminated cases, although overt AI is less common. Reported cases described bilateral adrenal masses mimicking malignancy or TB, even in immunocompetent individuals. Addisonian crisis may be the initial manifestation, especially when the diagnosis is delayed. In TB-endemic settings, fungal infections are often overlooked, leading to delayed diagnosis and inappropriate therapy.

## CASE

We reported a case of a 68-year-old male with underlying diabetes mellitus who presented with fever, cough, dysphagia, and weight loss for 1 month. He was empirically treated as smear-negative disseminated TB. On day 2 of therapy, he developed hypotension (80/50 mmHg), hypoglycemia (3.9 mmol/L), hyponatremia (Na 129 mmol/L), and hyperkalemia (K 5.1 mmol/L), suggestive of adrenal crisis, and was started on intravenous hydrocortisone. Serum cortisol prior to treatment was 61

nmol/L. Computed tomography (CT) imaging revealed bilateral lipid-poor adrenal lesions (right:  $3.6 \times 2.2 \times 4.9$  cm, Hounsfield Unit (HU) 36 and absolute washout 33%; left:  $3.5 \times 2.4 \times 5.4$  cm; HU 35 and absolute washout 17%), raising suspicion of infectious or malignant etiologies. Endoscopic ultrasound-guided biopsy demonstrated necrotizing granulomatous inflammation with budding fungal yeasts on Pituitary Apoplexy Score and GMS staining, consistent with *Histoplasma capsulatum*. TB and malignancy were excluded. He received amphotericin B for 14 days, followed by oral itraconazole for 1 year, and oral hydrocortisone replacement. At 1-year follow-up, adrenal lesions remained stable on CT images, and he continued to require hydrocortisone replacement.

#### CONCLUSION

This case highlights the importance of considering disseminated histoplasmosis as a differential diagnosis of bilateral adrenal masses with AI, especially with poor response to anti-TB therapy. Early tissue diagnosis is essential, as imaging findings are non-specific. Prompt recognition is critical to prevent life-threatening adrenal crisis and improve clinical outcomes.

### EP\_A011

#### LARGE “GROWING” ADRENAL MASS WITH AN UNEXPECTED HISTOLOGY

Ling Hui Kiu<sup>1</sup>, Ee Wen Loh<sup>1</sup>, Pei Lin Chan<sup>1</sup>, Florence Hui Sieng Tan<sup>1</sup>

<sup>1</sup>Endocrinology Unit, Department of Medicine, Sarawak General Hospital

#### INTRODUCTION

Large, rapidly enlarging adrenal masses typically mandate surgical intervention given the high probability of adrenocortical carcinoma (ACC). However, benign processes can mimic these aggressive growth kinetics, creating a diagnostic challenge for clinicians.

#### CASE

A 74-year-old male with hypertension, atrial fibrillation on rivaroxaban, and prostate cancer was referred for evaluation of a right adrenal incidentaloma detected on computed tomography imaging performed for prostate cancer staging. The well-defined mass measured  $8.9 \times 7.8 \times 7.5$  cm (AP  $\times$  W  $\times$  CC) with areas of calcification. Mean attenuation was +40 Hounsfield Unit, with no significant washout. Biochemical evaluation confirmed a non-functioning lesion (24-hour urine metanephrines 756 mcg/24 hours [N 246–753 mcg/24 hours]; serum cortisol 62 nmol/L post overnight dexamethasone suppression test). The patient

was otherwise asymptomatic and declined surgical intervention. Repeat imaging 4 months later demonstrated interval enlargement of the mass to  $9.8 \times 8.8 \times 10.7$  cm. Due to this rapid growth, which was highly concerning for ACC, the patient underwent laparoscopic right adrenalectomy. Histopathological examination unexpectedly revealed an adrenal hematoma without evidence of an underlying tumor or malignancy.

This case illustrates the difficulty in differentiating aggressive cortical tumors from atypical hemorrhagic events. Larger series on adrenal hemorrhage reported trauma and procedural complications as the leading causes, with a median size of 3–4 cm. Idiopathic large adrenal hematomas presenting as rapidly expanding “pseudo-tumors” are exceptionally rare, with fewer than 20 cases reported in which surgical resection was performed due to high preoperative suspicion of malignancy. Additionally, adrenal hemorrhage attributed to anticoagulant therapy often occurs bilaterally. Unilateral lesion, especially when large, can pose a diagnostic challenge as highlighted in this case.

#### CONCLUSION

In patients on anticoagulation, rapid interval growth of an adrenal mass does not always equate to malignancy. Recognizing this mimicry in the era of widespread Direct Oral Anticoagulant use is essential for refining treatment decision regarding surgical intervention, as most cases exhibited a self-limiting process with spontaneous resolution.

### EP\_A012

#### SILENT ADRENAL MASS WITH DIAGNOSTIC CHALLENGE: A CASE OF HUGE NON-FUNCTIONING ADRENAL LESION MIMICKING MALIGNANCY

Sarojini Devi Simanchalam<sup>1</sup>, Hamizah Hamzah<sup>1</sup>, Lee Qin Zhi<sup>2</sup>, Poh Shean Wong<sup>1</sup>, Chin Voon Tong<sup>2</sup>, Tiang Koi Ng<sup>3</sup>, Nor Afidah Karim<sup>1</sup>, Noor Lita Adam<sup>1</sup>

<sup>1</sup>Unit Endocrinology, Department of Medicine, Hospital Tuanku Jaafar

<sup>2</sup>Department of Endocrinology, Institute Endocrine, Hospital Putrajaya

<sup>3</sup>Unit Infectious Disease, Department of Medicine, Hospital Tuanku Jaafar

#### INTRODUCTION

Adrenal incidentalomas are increasingly detected with the widespread use of imaging, whereby the large or heterogeneous lesions often raise concern for adrenocortical carcinoma (ACC). However, certain rare benign

and infectious conditions may closely mimic malignant features, posing a diagnostic challenge.

#### CASE

A 64-year-old female with diabetes mellitus, hypertension, and dyslipidemia was noted to have progressively rising alkaline phosphatase during routine follow-up. She had non-specific gastrointestinal symptoms. A computed tomography abdomen pelvis showed a large, lobulated mass at the left flank, likely of adrenal origin. An adrenal protocol computed tomography revealed a large, heterogeneously enhancing left suprarenal mass measuring 10.7 × 10.3 × 10.7 cm, with a plain-phase attenuation of +81 Hounsfield Unit and absolute (28%) and relative (18%) washout. The right adrenal gland was normal, with no evidence of distant metastasis.

Hormonal evaluation showed normal 24-hour urinary metanephrines, excluding pheochromocytoma. The overnight dexamethasone suppression test demonstrated cortisol of 89 nmol/L, suggestive of mild autonomous cortisol secretion, without clinical features of overt hypercortisolism. DHEA was low (0.371 μmol/L), and adrenocorticotropic hormone was suppressed (1.26 pg/mL). Evaluation for primary aldosteronism was not done due to the absence of resistant hypertension or hypokalemia. The gonadotropin profile was consistent with post-menopausal status (follicle-stimulating hormone (89 IU/L) and luteinizing hormone (28.9 IU/L) with low estradiol.

The patient underwent open left adrenalectomy. Histopathology revealed an adrenal cavernous hemangioma with extensive hemorrhage and infarction, alongside necrotizing granulomatous inflammation with numerous intracellular fungal organisms and narrow-based budding yeast forms, highly suggestive of histoplasmosis, with no evidence of malignancy. She was subsequently co-managed with infectious disease team and commenced on intravenous amphotericin B.

#### CONCLUSION

This is a rare coexistence of an adrenal hemangioma and histoplasmosis, presenting as a large adrenal mass mimicking ACC. The limitations of imaging in differentiating benign from malignant adrenal lesions are revealed and emphasize the role of histopathological confirmation. Increased awareness of such entities can support the diagnosis and management.

## EP\_A013

### A DIAGNOSTIC TRAP: ECTOPIC ACTH CUSHING SYNDROME WITH INCIDENTAL PITUITARY MICROADENOMA

**Khai Seong Khor<sup>1</sup>, Ying Jie Tan<sup>1</sup>, Lay Ang Lim<sup>1</sup>**

<sup>1</sup>Endocrinology Unit, Department of Medicine, Hospital Seberang Jaya

#### INTRODUCTION

Ectopic adrenocorticotropic hormone (ACTH)-dependent Cushing syndrome is a rare but important cause of hypercortisolism and can be difficult to diagnose, particularly in the presence of incidental pituitary lesions.

#### CASE

A 21-year-old patient presented with recurrent severe hypokalemia, normotension, and rapid weight gain. The hypokalemia was persistent, requiring multiple hospital admissions and ongoing potassium supplementation.

Biochemical evaluation confirmed ACTH-dependent Cushing syndrome with elevated ACTH (27.4 pmol/L), elevated late-night salivary cortisol, and failure of suppression on low-dose dexamethasone suppression testing (cortisol 875 nmol/L). Pituitary magnetic resonance imaging demonstrated a 0.5 × 0.3 cm microadenoma, raising suspicion for a pituitary source. However, inferior petrosal sinus sampling (IPSS) showed no central-to-peripheral ACTH gradient, excluding Cushing disease. Computed tomography of the thorax revealed a 0.6 cm right middle lobe pulmonary nodule. Gallium-68 DOTATATE PET-CT demonstrated increased somatostatin receptor uptake, confirming the lesion as the likely ectopic ACTH source. The lesion was not amenable to bronchoscopic resection, and the patient was referred for cardiothoracic surgical excision.

During the course of illness, the patient developed resistant hypertension and worsening hypokalemia requiring high-dose potassium supplementation and multiple antihypertensive agents. Medical therapy with ketoconazole and metyrapone was initiated for cortisol control while awaiting definitive surgical resection.

#### CONCLUSION

This case highlights an aggressive and atypical presentation of ectopic ACTH syndrome in a young patient, initially presenting with isolated hypokalemia but rapidly progressing to severe hypercortisolism. It underscores the importance of early recognition, appropriate localization with IPSS, and timely initiation of medical therapy to control cortisol excess prior to definitive surgery.

## EP\_A014

### BILATERAL ADRENAL MASSES WITH RAPID DETERIORATION: A RARE CASE OF PRIMARY ADRENAL LYMPHOMA

Melody Tsen Shu Ling<sup>1</sup>, Cheong Yee Weai<sup>2</sup>, Hwee Ching Tee<sup>2</sup>, Jin Hui Ho<sup>2</sup>, Shireen Siow Leng Lui<sup>2</sup>

<sup>1</sup>Department of Medicine, Hospital Queen Elizabeth

<sup>2</sup>Diabetes & Endocrine Unit, Department of Medicine, Hospital Queen Elizabeth II

#### INTRODUCTION

Primary adrenal lymphoma (PAL) is a rare extranodal lymphoma, accounting for less than 1% of cases. It often presents with non-specific constitutional symptoms and features of adrenal insufficiency. The absence of pathognomonic findings frequently leads to delayed diagnosis, by which time the disease is often advanced, contributing to poor prognosis.

#### CASE

A 59-year-old male with type 2 diabetes mellitus and previously treated pulmonary tuberculosis presented with 1 month of lethargy, anorexia, weight loss, and abdominal pain. He was cachectic but hemodynamically stable (BP 120/81 mmHg; glucose 5.1 mmol/L), with otherwise unremarkable systemic examination. Laboratory evaluation revealed hyponatremia (120 mmol/L), hyperkalemia (6.0 mmol/L), and severe hypercalcemia (4.4 mmol/L). A short Synacthen test confirmed adrenal insufficiency.

Computed tomography demonstrated marked bilateral adrenal enlargement with bulky masses (8.9 × 8.7 × 8.7 cm right; 9.9 × 7.6 × 10.2 cm left), suggestive of malignant infiltration. Adrenal protocol imaging revealed indeterminate lesions with attenuation >40 Hounsfield Unit and relative washout <40%. Ultrasound-guided biopsy of the right adrenal gland was performed.

The patient was discharged on hydrocortisone replacement with plans for early follow-up. One week later, he presented again in adrenal crisis with severe hypoglycemia (1.1 mmol/L) and cardiovascular collapse. Despite resuscitative efforts, he succumbed. Histopathology subsequently confirmed diffuse large B-cell lymphoma, activated B-cell subtype, consistent with PAL.

#### CONCLUSION

This case highlights the diagnostic pitfalls of PAL, particularly when constitutional symptoms mimic chronic infections such as tuberculosis. It underscores the need for high clinical suspicion in patients with bilateral adrenal masses and adrenal insufficiency. Early recognition, adequate steroid replacement including mineralocorticoid

therapy, and prompt tissue diagnosis are critical to prevent rapid deterioration and improve outcomes.

## EP\_A015

### METASTATIC MALIGNANT PHEOCHROMOCYTOMA DRIVEN BY DNMT3A SOMATIC MUTATION

Vijayrama Rao Sambamoorthy<sup>1</sup>, Zanariah Hussein<sup>1</sup>, Anthony Louis Kindu<sup>2</sup>

<sup>1</sup>Endocrine Unit, Medical Department, Hospital Putrajaya

<sup>2</sup>Nuclear Medicine Department, Institut Kanser Negara

#### INTRODUCTION

Pheochromocytomas and paragangliomas (PPGL) are rare neuroendocrine tumors with high heritability. While most are benign, approximately 25% are malignant, defined by distant metastases. Molecular classification has identified three clusters, with Cluster 3 (Wnt-signaling) being exclusively somatic and associated with aggressive behavior. We report a rare case of metastatic malignant pheochromocytoma driven by a somatic DNMT3A mutation, highlighting its unique imaging characteristics and rapid clinical progression.

#### CASE

A 55-year-old female presented with paroxysmal hypertension, headache, and a 10-kg weight loss. Biochemical workup revealed markedly elevated 24-hour urine metanephrines (163 × ULN) and normetanephrines (47 × ULN). Imaging confirmed a 15-cm left adrenal mass with liver and widespread skeletal metastases. Functional imaging demonstrated a striking mixed avidity: liver metastases were predominantly fluorodeoxyglucose-avid (SUVmax 7.0), skeletal lesions showed high Ga-68 DOTATATE avidity (SUVmax 6.9), and the primary tumor exhibited the strongest avidity on 131 I-MIBG scan. Whole Exome Sequencing identified a rare pathogenic somatic variant in the DNMT3A gene (c.2645G>A) with no other germline or somatic mutations in known susceptibility genes. Despite adequate alpha-blockade and supportive care, the patient developed acute liver failure and coagulopathy, rendering her unfit for any form of invasive intervention and finally succumbing to the disease within 3 months of presentation.

#### CONCLUSION

This case underscores the aggressive nature of Cluster 3 PPGLs associated with DNMT3A mutations, which likely promote tumorigenesis via Wnt-pathway activation and epigenetic dysregulation. The discordant functional imaging reflects significant tumor heterogeneity, which may complicate diagnostic and therapeutic strategies.

Given the rarity of DNMT3A-mutated PPGL (<1% of cases), this case report emphasizes the necessity of comprehensive molecular profiling in advanced disease to refine risk stratification and guide the development of precision-based palliative management in rapidly progressive cases.

## EP\_A016

### CONGENITAL ADRENAL HYPERPLASIA WITH HYPOGONADISM IN A MAN: 3 $\beta$ -HYDROXYSTEROID DEHYDROGENASE DEFICIENCY VS. LIPOID HYPERPLASIA?

Marisa Masera Marzukie<sup>1</sup>, Quan Hziung Lim<sup>1</sup>,  
Shireene Ratna Vethakkan<sup>1</sup>, Jeyakantha Ratnasingam<sup>1</sup>  
<sup>1</sup>Universiti Malaya Medical Centre

#### INTRODUCTION

3 $\beta$ -Hydroxysteroid dehydrogenase (3 $\beta$ -HSD) deficiency and lipoid congenital adrenal hyperplasia (CAH) are rare disorders of steroidogenesis that result in impaired synthesis of all adrenal and gonadal hormones. Affected males typically present with ambiguous genitalia and concurrent mineralocorticoid and glucocorticoid deficiency. Distinguishing between these two conditions is crucial, as their management strategies differ.

#### CASE

We report a 24-year-old male, born to non-consanguineous parents, who was clinically diagnosed with 3 $\beta$ -HSD deficiency during infancy. He presented at day 40 of life with ambiguous genitalia, bilateral undescended testes, and generalized hyperpigmentation. His family history was significant for an elder brother with salt-losing CAH. Initial biochemical evaluation confirmed primary adrenal insufficiency and primary hypogonadism. Notably, his steroid precursors, dehydroepiandrosterone sulfate (DHEAS) and 17-hydroxyprogesterone, were suppressed. A karyotype confirmed 46,XY. In the absence of genetic testing at that time, a clinical diagnosis of 3 $\beta$ -HSD deficiency was made, and he was commenced on mineralocorticoid and suprphysiological glucocorticoid replacement. He underwent bilateral orchidopexy and hypospadias repair in childhood. Pubertal induction was required, followed by maintenance testosterone therapy. Upon transitioning to adult care, a review of his biochemical profile, particularly suppressed DHEAS, which is inconsistent with 3 $\beta$ -HSD deficiency, raised the suspicion of a more proximal defect, such as lipoid CAH. Differentiation is imperative, as lipoid CAH requires only physiological glucocorticoid replacement, whereas 3 $\beta$ -HSD deficiency often needs higher doses to suppress adrenocorticotrophic hormone and DHEAS. To resolve this diagnostic uncertainty and guide long-term therapy, the patient was referred for genetic studies.

#### CONCLUSION

Differentiating 3 $\beta$ -HSD deficiency from lipoid CAH is important, as both have similar clinical presentation. The absence of elevated steroid precursors, particularly DHEAS, should raise suspicion of a more proximal defect. Given the different aims of glucocorticoid therapy, establishing a precise diagnosis through genetic studies is essential to guide clinical management and minimize the morbidity associated with suprphysiological corticosteroid dosing.

## EP\_A017

### METASTASIS OR MIMIC? NAVIGATING THE WORKUP OF A LARGE ADRENAL INCIDENTALOMA IN THE SETTING OF LUNG CANCER

Mohd Firdaus Mohamad Kamil<sup>1</sup>, Masliza Hanuni  
Mohd Ali<sup>1</sup>, Wan Mohd Hafez Wan Hamzah<sup>1</sup>  
<sup>1</sup>Endocrinology Unit, Medical Department, Hospital Sultanah Nur Zahirah

#### INTRODUCTION

The identification of a significant adrenal mass in a patient without a biopsy-confirmed malignancy poses a diagnostic challenge: Is it a metastatic lesion or an underlying adrenal condition? Adrenal metastases are the second most common site of spread for lung adenocarcinoma; approximately 3–7% of adrenal masses represent benign adenomas. Diagnosis is even harder if there are signs of primary aldosteronism (PA).

#### CASE

We present a case of a 62-year-old Chinese female with a 10-year history of hypertension, managed on dual antihypertensive therapy, who presented for evaluation of suspected PA following the discovery of hypokalemia. Biochemical screening revealed an elevated aldosterone-renin ratio (ARR, 65). The overnight dexamethasone suppression test (20 nmol/L) and testosterone (0.79 nmol/L) were both within normal limits. Saline Suppression Test (SST) showed an indeterminate post-infusion aldosterone level (202.8 pmol/L). Cross-sectional imaging via computed tomography (CT) Adrenals identified a large, 6.4 × 5.4 × 6.2 cm heterogeneous left suprarenal mass with a low mean attenuation (8.6 Hounsfield Unit [HU]). Concurrently, an incidental left upper lobe pulmonary lesion was identified, and PET-CT was performed; the SUVmax of the lung was identical to that of the adrenal lesion. An ultrasound-guided biopsy of the pulmonary lesion confirmed estimated glomerular filtration rate-mutation-positive lung adenocarcinoma. The patient started on targeted therapy with dacomitinib. Follow-up CT imaging at 9 months demonstrated disease progression within the thorax,

marked by the appearance of a new pulmonary nodule. Notably, however, the adrenal mass remained stable in size and morphology.

#### CONCLUSION

The absence of mixed androgen/glucocorticoid hypersecretion, combined with the radiographically static nature of the mass, suggests a lower probability of adrenocortical carcinoma. This case highlights that while size is a major risk factor for adrenocortical carcinoma, it must be interpreted in conjunction with hormonal activity, HU, and growth patterns. Identifying these “mimics” helps avoid over-staging lung cancer and ensures patients receive targeted therapy instead of unnecessary adrenalectomies.

## EP\_A018

### A HIDDEN DIAGNOSIS: DISSEMINATED HISTOPLASMOSIS MIMICKING TUBERCULOSIS IN THE ELDERLY

Wan Muhamad Amir Wan Md Zin<sup>1</sup>, Moon Yan Yap<sup>1</sup>, Meroshini Sundaran<sup>1</sup>, Siti Nabilah ‘Atiqah Othman<sup>1</sup>, Siti Nabihah Mohamed Hatta<sup>1</sup>, Maz Anirah Abdul Azis<sup>1</sup>

<sup>1</sup>Department of Medicine, Hospital Sultan Abdul Aziz Shah, Universiti Putra Malaysia

#### INTRODUCTION

Histoplasmosis is a rare opportunistic, inhalation-acquired systemic mycosis caused by *Histoplasma capsulatum*, endemic to Southeast Asia, including Malaysia. Although classically seen in immunocompromised hosts, it is increasingly reported in immunocompetent individuals. Infection is associated with environmental exposures such as bat or bird droppings and soil disruption. Histoplasmosis is a progressive granulomatous disease that can closely mimic tuberculosis and malignancy, making diagnosis challenging.

#### CASE

An 87-year-old Malay male with a history of treated pulmonary tuberculosis presented with a 6-month history of intermittent fever, anorexia, weight loss, and hypotension. Initial computed tomography imaging demonstrated bilateral heterogeneous adrenal masses (right: 2.2 × 3.7 × 5.0 cm; left: 2.0 × 3.7 × 5.2 cm) with indeterminate washout characteristics. Biochemical adrenal evaluation, including a short Synacthen test, confirmed primary adrenal insufficiency. Extensive microbiological and malignancy workup, including bronchoscopy, cultures, and tumor markers, was non-diagnostic. In view of clinical deterioration and epidemiological risk, empirical anti-tuberculous therapy was initiated; however, no clinical improvement was observed after 2 months. PET-FDG

revealed intensely hypermetabolic bilateral adrenal masses (SUVmax right 16.7, left 13.2) with no other abnormal foci. Non-invasive fungal investigations were negative. Definitive diagnosis was established via computed tomography-guided adrenal biopsy, which demonstrated necrotizing granulomatous inflammation with intracellular yeasts, subsequently identified as *H. capsulatum*. The patient was treated with oral itraconazole and corticosteroid replacement, resulting in significant clinical improvement and planned interval radiological reassessment.

#### CONCLUSION

Disseminated histoplasmosis is a diagnostic challenge, particularly in frail elderly patients, where invasive procedures may be delayed. It can mimic tuberculosis and malignancy and may lack an identifiable exposure history. Non-invasive tests may be inconclusive, making tissue biopsy essential. Adrenal involvement may result in primary adrenal insufficiency, further complicating the clinical picture. Early consideration and timely confirmation are crucial for appropriate management.

## EP\_A019

### OVERWHELMING OPPORTUNISTIC INFECTIONS AS THE INITIAL PRESENTATION OF SEVERE CUSHING SYNDROME

Kirtthene Gopal<sup>1,2</sup>, Ooi Chuan Ng<sup>2</sup>, Yee Lin Lee<sup>2</sup>

<sup>1</sup>Hospital Sultan Abdul Aziz Shah

<sup>2</sup>Universiti Putra Malaysia

#### INTRODUCTION

Severe hypercortisolism is associated with profound impairment of both innate and adaptive immune responses, predisposing affected individuals to opportunistic infections. Excess glucocorticoids alter leukocyte trafficking, suppress pro-inflammatory cytokine production, and impair cellular immunity, increasing susceptibility to bacterial, viral, and fungal pathogens. In some cases, severe infections may precede the diagnosis of Cushing syndrome and represent the initial clinical manifestation. Early recognition is important as untreated hypercortisolism can lead to substantial morbidity and mortality.

#### CASE

A young adolescent male presented with progressive facial fullness and facial hyperpigmentation for 4 months, followed by 1 month of intermittent fever, cough, lower limb weakness, and hallucinations. On examination, he was tachypneic with cushingoid features including moon facies, pigmented acne over the face and chest, and nail bed hyperpigmentation. He was hypertensive and had severe hypokalemia with lymphopenia.

Radiological imaging demonstrated multiple cavitary lung lesions and intracranial tuberculomas. Bronchoalveolar lavage identified multiple opportunistic pathogens, including *Pneumocystis jirovecii*, *Aspergillus fumigatus*, and *Haemophilus influenzae*, while cerebrospinal fluid testing was positive for cytomegalovirus.

Given the unusual combination of infections, an underlying immunocompromised state was suspected. Endocrine evaluation revealed markedly elevated serum cortisol, with loss of diurnal rhythm and elevated adrenocorticotropic hormone (ACTH). Twenty-four-hour urinary cortisol was significantly increased, confirming severe ACTH-dependent Cushing syndrome. Magnetic resonance imaging of the pituitary gland and computed tomography imaging of the thorax, abdomen, and pelvis did not identify the source of ACTH secretion.

#### CONCLUSION

This case highlights that overwhelming opportunistic infections may be the first manifestation of severe Cushing syndrome in children. Excess cortisol disrupts host defenses by impairing neutrophil chemotaxis and macrophage phagocytosis, suppressing T-cell-mediated immunity, and reducing cytokine signaling necessary for pathogen clearance. These mechanisms contribute to susceptibility to simultaneous bacterial, fungal, and viral infections. Clinicians should therefore consider underlying hypercortisolism in patients presenting with multiple or unusual opportunistic infections to enable earlier diagnosis and appropriate multidisciplinary management.

## EP\_A020

### BEYOND HYPONATREMIA: UNMASKING ADDISON'S DISEASE

Aminath Naqsha<sup>1,2</sup>, Ilham Ismail<sup>2</sup>, Mahrunissa Mahadi<sup>2</sup>, Yik Hin Chin<sup>2,3</sup>, K.J. Lingeswary Krishnan<sup>2,3</sup>, Norlaila Mustafa<sup>1,2</sup>, Norasyikin A.Wahab<sup>1,2</sup>

<sup>1</sup>Department of Medicine, Faculty of Medicine, Universiti Kebangsaan Malaysia

<sup>2</sup>Department of Medicine, Hospital Canselor Tuanku Muhriz

<sup>3</sup>Ministry of Health Malaysia

#### INTRODUCTION

Primary adrenal insufficiency is rare and potentially life-threatening, with an estimated prevalence of five cases per million in Southeast Asia. Local data remain limited, and diagnosis is frequently delayed due to non-specific clinical manifestations. Widespread use of traditional medication in Malaysia may further undermine recognition, particularly when steroid exposure is concealed. We report a female

on prolonged use of traditional remedies presented with classic features of Addison's disease rather than cushingoid features, confirmed by biochemical results.

#### CASE

A 65-year-old female with underlying dyslipidemia and osteoarthritis presented with 4 days of giddiness, poor intake, nausea, and diarrhea. Further history revealed prolonged use of multiple traditional Chinese medicines, discontinued months prior, raising suspicion of prior steroid exposure. She claimed her skin has become darker over the past 2 months. She denied any infectious symptoms, contact with PTB patients, or exposure to birds. There was no family history of autoimmune disease. Clinically, she was dehydrated and hypotensive. Her blood pressure improved after fluid resuscitation. There was hyperpigmentation involving the face, extremities, tongue, and buccal mucosa.

Investigation results showed severe hyponatremia (119 mmol/L), hyperkalemia (4.93 mmol/L), with normal creatinine and negative infective markers. Hyponatremia persisted despite adequate hydration. Thyroid function test was normal (Free T4 12.28 pmol/L and thyroid-stimulating hormone 4.16  $\mu$ IU/mL). Morning cortisol was suppressed (37 nmol/L) with markedly elevated adrenocorticotropic hormone levels (1,134 pg/mL), confirming the diagnosis of primary adrenal insufficiency. Hence, hydrocortisone was commenced, and serum sodium was normalized 2 days later. The underlying etiology remains under evaluation, although autoimmune adrenalitis is the most likely cause.

#### CONCLUSION

Primary adrenal insufficiency should be considered in patients presenting with unexplained hyponatremia and hypotension. In a setting where traditional medication use is prevalent, unrecognized steroid exposure may further complicate diagnosis. A thorough clinical and appropriate biochemical assessment is crucial to differentiating primary from secondary adrenal insufficiency.

## EP\_A021

### WHEN TISSUE IS THE ISSUE: PRESUMPTIVE DIAGNOSIS AND TREATMENT OF BILATERAL ADRENAL TUBERCULOSIS

Norul Ain Mat Seman<sup>1</sup>, Maslina Hanuni Ma<sup>2</sup>,  
Wan Hafez Wan Hamzah<sup>2</sup>

<sup>1</sup>Department of Internal Medicine, Hospital Sultanah Nur Zahirah

<sup>2</sup>Endocrinology Unit, Hospital Sultanah Nur Zahirah

#### INTRODUCTION

Adrenal tuberculosis (TB) is a rare but important cause of adrenal insufficiency in TB-endemic regions, usually secondary to pulmonary or extrapulmonary disease, with primary involvement being uncommon. It typically affects both glands via hematogenous or lymphatic spread and presents late with nonspecific features after significant adrenal destruction, making diagnosis challenging. Diagnosis is more straightforward in the presence of extra-adrenal TB, where imaging may obviate the need for biopsy, but remains difficult in isolated adrenal involvement.

#### CASE

We report a 69-year-old Malay male with diabetes mellitus, hypertension, and hyperlipidemia who presented with a 2-week history of chronic cough and 4 months of constitutional symptoms, including weight loss and anorexia. Initial TB workup in September 2025 was negative. He was subsequently admitted twice in October 2025 for pneumonia, with persistent upper lobe consolidation on chest radiography despite antibiotics.

Contrast-enhanced computed tomography thorax, abdomen, and pelvis revealed bilateral mildly enhancing hypodense adrenal lesions (right 3.7 × 3.0 cm, left 2.5 × 2.6 cm), suggestive of adenoma, hyperplasia, or lymphoma. Bronchoscopy detected *Mycobacterium tuberculosis* via GeneXpert BAL, with no malignant cells on cytology. Adrenal biopsy was non-diagnostic.

Biochemical evaluation showed low morning cortisol with elevated adrenocorticotropic hormone and findings consistent with adrenal insufficiency. The patient was treated as smear-negative pulmonary TB with adrenal involvement and initiated on anti-TB therapy, currently in the maintenance phase. Hydrocortisone replacement 10 mg twice daily was also initiated.

#### CONCLUSION

This case highlights the diagnostic challenge of adrenal TB, particularly when tissue sampling is inconclusive. In

TB-endemic settings, a presumptive diagnosis based on clinical, radiological, and microbiological evidence is often necessary. Early empiric anti-TB therapy is essential to prevent adrenal crisis and preserve endocrine function.

## EP\_A022

### BEYOND MITOTANE IN A PATIENT WITH HIGHLY AGGRESSIVE ADRENOCORTICAL CARCINOMA

Muhammad Shukri Johar<sup>1</sup>, Siti Sanaa Wan Azman<sup>1</sup>,  
Dorothy Maria Anthony Bernard<sup>1</sup>, Foo Siew Hui

<sup>1</sup>Endocrine Unit, Medical Department, Hospital Selayang

#### INTRODUCTION

Adrenocortical carcinoma (ACC) is an aggressive malignancy with high rates of recurrence even after surgical resection. Surgery remains the mainstay of treatment, while adjuvant options are limited. Mitotane is the only approved systemic therapy. Current guidelines recommend stereotactic body radiotherapy (SBRT) alongside adjuvant mitotane therapy in R<sub>x</sub>, R<sub>1</sub>, R<sub>2</sub> resections and in locally advanced disease.

#### CASE

We present a case of a 40-year-old female who presented with abdominal pain and was found to have a large heterogeneous left adrenal mass measuring 8.2 × 8.5 × 9.5 cm (Hounsfield Unit 63) on computed tomography (CT) imaging. Clinically, she was obese with a body mass index of 33.7 kg/m<sup>2</sup>. No discriminatory feature of Cushing's was present. Hormonal evaluation demonstrated autonomous cortisol secretion with failure of suppression on both overnight and low-dose dexamethasone suppression tests at 301 nmol/L and 313.6 nmol/L, respectively. DHEA, testosterone, and urinary metanephrine were within range. Hemoglobin A1c was 6.6%. She underwent open left adrenalectomy. Intra-operatively, a 12 × 10 cm adrenal tumor was identified with multiple areas of tumor rupture and spillage during mobilization. HPE confirmed high-grade ACC with high Weiss score of 8, Ki-67 index 60–80%, and mitotic count 54/50 hpf (pT2Nx). Post-operative CT imaging demonstrated a residual soft tissue lesion in the left adrenal bed (largest diameter 3.8 cm) with fluorodeoxyglucose avidity. We commenced adjuvant mitotane therapy, titrated to 2 g TDS with supraphysiological hydrocortisone replacement. Mitotane level was within therapeutic range (16 mcg/mL). She was deemed unsuitable for repeat surgery due to the proximity of the residual mass to the adjacent vessel and was planned for SBRT therapy after a multi-disciplinary team discussion.

## CONCLUSION

High-risk ACC with suspected residual disease remains a therapeutic challenge. While mitotane remains the cornerstone of adjuvant therapy, SBRT may represent a promising adjunctive local treatment modality in carefully selected patients. Further studies are required to define its role in improving local control and outcomes in ACC.

## EP\_A023

### WHEN CORTISOL OVERWHELMS THE HEART: A FATAL CASE OF METASTATIC ADRENOCORTICAL CARCINOMA PRESENTING AS ACUTE HEART FAILURE

Tze Liang Lee<sup>1</sup>, Shaleni Nagappen<sup>1</sup>, Deviga Latchumanan<sup>1</sup>

<sup>1</sup>Department of Internal Medicine, Hospital Port Dickson

## INTRODUCTION

Cushing's syndrome is a multisystem disorder with significant cardiovascular morbidity, yet presentation as acute heart failure is uncommon. When driven by adrenocortical carcinoma (ACC), the clinical course is often aggressive and rapidly fatal, with particularly poor out-comes in resource-limited settings where access to therapy is constrained.

## CASE

A 39-year-old previously well female presented with acute decompensated heart failure, newly diagnosed hypertension, type 2 diabetes mellitus, and obesity, preceded by a 3-year history of secondary amenorrhea and progressive weight gain. On admission, she exhibited florid Cushingoid features. Biochemical evaluation confirmed severe adrenocorticotrophic hormone (ACTH)-independent hypercortisolism: morning serum cortisol 1,950 nmol/L, failure of suppression on overnight dexamethasone suppression test (post-ODST cortisol 2022.9 nmol/L), and elevated 24-hour urinary free cortisol (2,069 nmol/24 hours, 2.56 × upper limit of normal). Androgen excess was evident, with elevated dehydroepiandrosterone sulfate (DHEAS more than 27 µmol/L) and testosterone (9.91 nmol/L). ACTH was suppressed, supporting an adrenal source, while aldosterone was normal. Contrast-enhanced computed tomography demonstrated a large left adrenal mass (12 cm) with tumor thrombus extending into the inferior vena cava and renal veins, with extensive hepatic and pulmonary metastases, consistent with advanced ACC. Management was limited by disease severity and resource constraints. Ketoconazole was contraindicated due to transaminitis, and alternative steroidogenesis inhibitors were unavailable, leaving metyrapone as the only feasible option. Oncological therapy was deferred due to sepsis and clinical instability. Her course was fulminant, complicated by recurrent heart failure, sepsis, and metabolic derange-

ments, culminating in refractory cardiopulmonary failure. She died within 1 month of diagnosis, prior to definitive oncological intervention.

## CONCLUSION

Fulminant cortisol-secreting ACC may present catastrophically as acute heart failure and progress rapidly. Early recognition and timely access to multimodal cortisol-lowering therapy are critical, particularly in resource-limited settings. In fulminant hypercortisolism, the challenge is not diagnosis—but timing.

## EP\_A024

### SOLITARY PROGRESSION TO BONE: A RARE MANIFESTATION OF ADRENOCORTICAL CARCINOMA

Mohd Fyzal Bahrudin<sup>1</sup>, Jia Miao Tan<sup>1</sup>, Chin Voon Tong<sup>1</sup>

<sup>1</sup>Endocrine Unit, Department of Medicine, Hospital Putrajaya

## INTRODUCTION

Adrenocortical carcinoma (ACC) is a rare and aggressive malignancy with a predilection for metastasis to the liver, lungs, and lymph nodes. Bone involvement is less common and typically occurs alongside widespread disease. Isolated skeletal progression without visceral involvement is unusual and not well characterized.

## CASE

A 60-year-old female underwent left adrenalectomy in 2019 for an incidentally detected adrenal mass, which was reported as a benign adrenal cortical adenoma (Ki-67 <3%). In 2022, she presented with persistent low back pain. Imaging demonstrated fluorodeoxyglucose-avid lesions involving the T12 vertebra and right ilium, without evidence of local recurrence or visceral metastases. Histopathological evaluation of a bone biopsy initially suggested a neuroendocrine neoplasm based on synaptophysin positivity. Following multiple expert reviews and integration of clinical, radiological, and immunohistochemical findings, a consensus diagnosis of metastatic ACC was established.

She received palliative radiotherapy to symptomatic skeletal sites and subsequently completed six cycles of etoposide, doxorubicin, and cisplatin chemotherapy in 2023, achieving disease stabilization. Surveillance imaging in May 2025 demonstrated progression confined to the axial and appendicular skeleton, with no involvement of the adrenal bed or visceral organs. Mitotane therapy was initiated in December 2025. Ongoing management focuses on systemic disease control, symptom palliation, and multidisciplinary supportive care.

## CONCLUSION

This case illustrates an uncommon pattern of ACC progression characterized by bone-dominant metastases in the absence of visceral disease. It also highlights the importance of reconsidering the initial histopathological diagnosis when clinical behavior is discordant. Vigilance for atypical metastatic patterns is warranted, even years after resection of an adrenal lesion initially classified as benign.

## EP\_A025

### CONUNDRUM IN THE MANAGEMENT OF A RARE CAUSE OF CUSHING SYNDROME

Wee Mee Cheng<sup>1</sup>, Lit Sin Yong<sup>1</sup>, Poh Shean Wong<sup>1</sup>,  
Nor Afidah binti Karim<sup>1</sup>, Noor Lita Adam<sup>1</sup>

<sup>1</sup>Endocrinology Unit, Department of Internal Medicine, Hospital Tuanku Ja'afar Seremban

## INTRODUCTION

Primary bilateral macronodular adrenal hyperplasia (PBMAH), characterized by bilateral adrenal macronodules >1 cm, is a rare genetic disease contributing to <2% of Cushing syndrome.

## CASE

A 56-year-old male with underlying diabetes mellitus and hypertension presented with worsening proximal muscle weakness. Detailed neurological assessment was unremarkable. Re-assessment revealed more apparent cushingoid features, prompting referral to endocrinology. Basal cortisol was markedly elevated at 957 nmol/L (145.4–619.4 nmol/L). Unsuppressed cortisol after 1 mg overnight dexamethasone and low-dose dexamethasone test confirmed Cushing Syndrome. Suppressed adrenocorticotropic hormone (ACTH <0.33 pmol/L) suggested autonomous cortisol secretion from adrenal glands. Computed tomography adrenal reported massively enlarged hypodense multinodular adrenal glands of varying sizes. Oral ketoconazole, an adrenal steroidogenesis inhibitor, was initiated. Despite careful titration to keep serum cortisol 400–500 nmol/L, he experienced glucocorticoid withdrawal syndrome. Bilateral adrenalectomy was planned but deferred as he continued to lose weight despite persistent hypercortisolism. Extensive investigations were conducted for possible opportunistic infections or malignancy. His chest X-ray revealed a suspicious right lung cavity. Positive serum galactomannan and bronchial alveolar lavage galactomannan suggested pulmonary aspergillosis. Voriconazole was introduced, with drug-drug interaction judiciously addressed. He underwent bilateral adrenalectomy and required lifelong glucocorticoid and mineralocorticoid replacement. Histopathological report

confirms bilateral macronodular adrenocortical disease. A referral to a genetic clinic was made to explore the potential hereditary basis.

## CONCLUSION

PBMAH is a highly heterogeneous disease with variable presentation and a wide spectrum of hypercortisolism. Definitive management remained controversial and individualized. Multidisciplinary discussion is crucial, and genetic study is highly recommended for long-term prognostication and familial screening.

## EP\_A026

### SYNERGIZING ARTIFICIAL INTELLIGENCE WITH CLINICIANS' EXPERTISE: TOWARDS PERSONALIZED PROACTIVE DIABETES CARE IN MALAYSIAN PRIMARY HEALTH CLINICS

Sindeh Woweham<sup>1</sup>, Mohd Nazri Mohd Daud<sup>1</sup>,  
George George Mathew<sup>1</sup>, Hazwani Hanum Hashim<sup>1</sup>,  
Khairun'naim Khairuddin<sup>1</sup>

<sup>1</sup>Faculty of Medicine and Health Sciences, Universiti Malaysia Sabah

## INTRODUCTION

Diabetes affects 15.6% of Malaysian adults and remains a leading cause of complications and mortality. Although locally developed artificial intelligence (AI) tools have shown strong technical performance, their integration with clinicians' decision-making in primary care remains fragmented. This perspective proposes a synergistic AI-clinician framework to deliver truly personalized proactive diabetes care.

## METHODOLOGY

A multidisciplinary team designed a clinical workflow that integrates three validated Malaysian AI components: (1) LightGBM (LGBM) model trained on Malaysian National Diabetes Registry (MNDR) data for complication risk prediction, (2) DR.MATA AI retinopathy screening with automated triage, and (3) AI-enhanced mobile apps for real-time self-management. These layers feed into a single secure clinician dashboard. The framework was modelled using existing datasets (MNDR 2011–2021, NHMS 2023, DR.MATA validation cohort >14,000 images) and aligned with the National AI Roadmap 2021–2025 and the forthcoming National AI Action Plan 2026–2030.

## RESULTS

The LightGBM model achieved ROC-AUC values of 0.84 (mortality), 0.71 (retinopathy/nephropathy), 0.66 (ischemic heart disease), and 0.74 (stroke). DR.MATA demonstrated

93.3% accuracy with automated triage. When integrated, modelling suggests the framework could reduce major complications by approximately 20–30% and unnecessary referrals by up to 35%. The system runs automatically upon opening the patient record, requiring no extra clinician steps.

#### CONCLUSION

Synergizing AI with clinicians' expertise offers a scalable solution for Malaysian primary health clinics. A 12-month national pilot is recommended to generate real-world evidence and inform the National AI Action Plan 2026–2030.

### EP\_A027

#### PREVALENCE OF DIABETIC PERIPHERAL NEUROPATHY AND ITS ASSOCIATION WITH SERUM NEURON-SPECIFIC ENOLASE AMONG TYPE 2 DIABETES MELLITUS PATIENTS

Siti Kaamilah Mohd Zin<sup>1,2</sup>, Fatimah Zaherah Mohamed Shah<sup>2</sup>, Nor Amelia Mohd Fauzi<sup>3</sup>, Rohana Abdul Ghani<sup>2</sup>, Nur 'Aini Eddy Warman<sup>2</sup>

<sup>1</sup>Hospital Tawau

<sup>2</sup>Endocrine Unit, Department of Internal Medicine, Hospital Al-Sultan Abdullah, Universiti Teknologi MARA

<sup>3</sup>Neurology Unit, Department of Internal Medicine, Hospital Al-Sultan Abdullah, Universiti Teknologi MARA

#### INTRODUCTION

Diabetic peripheral neuropathy (DPN) is a common complication of type 2 diabetes mellitus (T2DM), with nerve conduction studies recognized as the diagnostic gold standard. Serum neuron-specific enolase (NSE) has been linked with DPN. This study aims to determine the prevalence of DPN among T2DM patients, evaluate clinical characteristics, and explore the relationship between NSE and DPN.

#### METHODOLOGY

A cross-sectional study was conducted at Universiti Teknologi MARA Specialist Centre Sungai Buloh and Hospital Al-Sultan Abdullah, involving patients aged 18–60 years, diagnosed with T2DM for more than 5 years ( $n = 132$ ). All participants underwent anthropometric measurement, completed the Michigan Neuropathy Screening Instrument evaluation, and biochemical parameters, including lipid profile, hemoglobin A1c, and serum creatine and NSE. The diagnosis of DPN was made based on positive NCS findings. Logistic regression was used to identify factors associated with DPN.

#### RESULTS

The study population had a mean age of  $60.16 \pm 10.28$  years and a mean duration of diabetes of  $14.82 \pm 6.66$  years. The prevalence of DPN was 51.5% ( $n = 68$ ). Serum NSE levels were significantly higher ( $p = 0.003$ ) and independently associated with the presence of DPN (adjusted odds ratio [OR] 1.033, 95% confidence interval [CI] 1.009–1.058,  $p = 0.006$ ). Participants with DPN were also more likely to be on insulin therapy ( $p = 0.040$ ). In addition, retinopathy (adjusted OR 3.567, 95% CI 1.528–8.329,  $p = 0.013$ ) and elevated Urine Albumin-to-Creatinine Ratio levels indicating albuminuria (adjusted OR 1.031, 95% CI 1.002–1.061,  $p = 0.037$ ) were significantly associated with DPN.

#### CONCLUSION

More than half of the study population had DPN, which was significantly associated with both retinopathy and nephropathy, as well as with elevated serum NSE. This emphasizes the importance of early screening and highlights the role of NSE as a surrogate marker for neuropathy in diabetes.

### EP\_A028

#### RECURRENT DIABETIC KETOACIDOSIS: PREDICTORS AND CLINICAL OUTCOMES IN A 24-YEAR RETROSPECTIVE COHORT

Liang Wei Wong<sup>1</sup>, Lisa Mohamed Nor<sup>2</sup>, Raja Nurazni binti Raja Azwan<sup>1</sup>, Adilah Zulaikha binti Abd Latif<sup>1</sup>, Hidayatil Alimi bin Keya Nordin<sup>1</sup>, Qin Zhi Lee<sup>1</sup>, Kean Heng Lim<sup>1</sup>, Jia Ling Low<sup>1</sup>, Mohd Fyzal bin Bahrudin<sup>1</sup>, Syaza binti Izhar Hisham<sup>1</sup>, Jia Whey Jacelyn Ong<sup>2</sup>, Chin Voon Tong<sup>1</sup>

<sup>1</sup>Endocrine Unit, Medical Department, Hospital Putrajaya

<sup>2</sup>Clinical Research Centre, Hospital Putrajaya

#### INTRODUCTION

Diabetic ketoacidosis (DKA) is a life-threatening complication associated with significant morbidity and healthcare burden. Despite advances in diabetes care, recurrent DKA remains common, often reflecting gaps in treatment adherence and patient education. Identifying predictors of recurrence is crucial for risk stratification and targeted intervention.

#### METHODOLOGY

We conducted a retrospective observational study of all adult DKA admissions to a tertiary centre between 2001 and 2025. Electronic medical records were reviewed for demographic data, biochemical parameters, precipitating factors, and clinical outcomes. DKA was defined using standard biochemical criteria. Recurrent DKA was defined as

≥2 admissions during the study period. Factors associated with recurrent DKA admissions were analyzed. Patients under the age of 18 years and those with missing vital information were excluded.

## RESULTS

A total of 667 DKA admissions, comprising 566 patients, were identified, of which 101 admissions (15.1%) were recurrent, involving 65 patients. Among recurrent DKA episodes, the most common precipitating factors were infection (64.4%) and insulin omission (62.4%). After multivariate analyses, patients with type 1 diabetes mellitus (T1DM) were more likely to develop recurrent DKA compared to those with type 2 diabetes mellitus (aOR 4.16; 95% confidence interval [CI] 2.58–6.70;  $p < 0.001$ ). Insulin omission was strongly associated with recurrent DKA (aOR 2.29; 95% CI 1.46–3.60;  $p < 0.001$ ). In contrast, baseline glycosylated hemoglobin and chronic kidney disease were not significantly associated with recurrence. Diabetic counseling during the first DKA admission did not reduce recurrent DKA. There were no significant differences in mortality (3.9% vs 6.2%,  $p = 0.524$ ) or critical care admission rates (40.6% vs 38.7%,  $p = 0.718$ ) between recurrent and first DKA episodes.

## CONCLUSION

Recurrent DKA accounts for a substantial proportion of DKA admissions and is strongly associated with insulin omission and T1DM. Our findings suggest that recurrent DKA is driven predominantly by behavioral and adherence-related factors, indicating the need for multidisciplinary interventions beyond standard inpatient counseling.

## EP\_A029

### CLINICAL UTILITY OF MODIFIED ASIAN FINDRISC AND RANDOM CAPILLARY BLOOD GLUCOSE FOR THE DETECTION OF DYSGLYCEMIA IN THE ADULT POPULATION

Jie En Tan<sup>1</sup>, Nor Shaffinaz Yusoff Azmi Merican<sup>2</sup>,  
Florence Hui Sieng Tan<sup>1</sup>

<sup>1</sup>Sarawak General Hospital

<sup>2</sup>Sultanah Bahiyah Hospital

## INTRODUCTION

Type 2 diabetes mellitus is a major healthcare problem worldwide, yet high percentage of patients are undiagnosed. There is a dire need for effective screening strategies. We examine the use of modified Asian FINDRISC (M-FINDRISC) and POCT random capillary blood glucose (rCBG) for the detection of dysglycemia.

## METHODOLOGY

This cross-sectional, observational study included 151 adults aged ≥30 years without a prior history of diabetes in healthcare and community settings. Hemoglobin A1c of ≥6.3% was used for the diagnosis of diabetes, and 5.7–6.2% for prediabetes. Areas under the receiver operating curve (ROC-AUC) for M-FINDRISC were analyzed. The sensitivity and specificity of the combined use of M-FINDRISC and rCBG for the detection of dysglycemia were evaluated.

## RESULTS

The mean age of the participants was  $44.6 \pm 11.0$  years. They had high body mass index ( $27.8 \pm 4.9$  kg/m<sup>2</sup>). Most were sedentary (only 25.2% reported physical activities of ≥30 min/day). A total of 52.3% had first-degree relatives with diabetes, but less than 12% were taking antihypertensive medication. Out of 151 participants, 3.3% ( $n = 5$ ) were diagnosed with diabetes mellitus and 37.7% ( $n = 57$ ) with prediabetes, giving an overall prevalence of 41.1% for dysglycemia. The mean age of participants with dysglycemia was significantly older (47.9 vs. 42.3 years,  $p$ -value 0.002). Other parameters were not statistically different for the two groups. Mean M-FINDRISC score was  $9.7 \pm 3.9$  in the normal and  $10.8 \pm 4.0$  in the dysglycemic group, while rCBG was  $6.4 \pm 1.1$  mmol/L and  $7.1 \pm 3.1$  mmol/L, respectively. ROC-AUC of M-FINDRISC for dysglycemia was 0.561. A combined screening strategy (M-FINDRISC score ≥7.5 and CBG ≥7.8 mmol/L) yielded high specificity (89.9%) but low sensitivity (17.7%) for dysglycemia.

## CONCLUSION

While the combined screening strategy utilizing M-FINDRISC and POCT random CBG improves specificity, M-FINDRISC showed limited predictive value for dysglycemia in this specific cohort, making it a less ideal tool for screening.

## EP\_A030

### UNDERSTANDING DIABETES LITERACY IN SEREMBAN: PREDICTIVE FACTORS AND CLINICAL IMPLICATIONS

Wee Mee Cheng<sup>1</sup>, Nadiah Aminah Azizan<sup>2</sup>, Wan Farahiyah Wan Muhammad<sup>3</sup>, Aun Aun Chua<sup>3</sup>, Poh Shean Wong<sup>1</sup>, Lit Sin Yong<sup>1</sup>, Nor Afidah Karim<sup>1</sup>, Noor Lita Adam<sup>1</sup>

<sup>1</sup>Endocrinology Unit, Department of Internal Medicine, Hospital Tuanku Ja'afar Seremban

<sup>2</sup>Klinik Kesihatan Seremban

<sup>3</sup>Clinical Research Centre, Hospital Tuanku Jaafar Seremban

#### INTRODUCTION

Diabetes literacy represents personal knowledge and competencies related to diabetes mellitus (DM) among people living with DM (PLWD). It is a crucial component for optimizing care and empowering effective self-management.

#### METHODOLOGY

A cross-sectional study was conducted at Hospital Tuanku Ja'afar Seremban (HTJS) and Klinik Kesihatan Seremban (KKS) using a validated simplified Diabetes Knowledge Test (DKT). DKT assessed understanding in six domains, namely, awareness, lifestyle modification, diet and monitoring, general knowledge, preventive screening, and insulin. A score of >75% was classified as adequate diabetes literacy. Significant predictive factors identified from univariate Pearson Chi Square were further analyzed using multivariate logistic regression.

#### RESULTS

A total of 250 PLWDs, with equal contribution from each centre, were recruited with a mean (SD) age of 50.3 (13.6) years, 58.4% female, and 43.2% Malays. A total of 21.2% demonstrated adequate diabetes literacy. The results demonstrated the highest proficiency in the preventive screening domain (92.6%) and the lowest in the awareness domain (50.2%). Unemployed PLWDs had significantly lower odds of adequate diabetes literacy (odds ratio [OR] = 0.20,  $p = 0.010$ ). Similarly, PLWDs with hemoglobin A1c levels >10% exhibited approximately 2.6-fold lower odds of adequate diabetes literacy. In contrast, PLWDs who reported healthcare personnel as their primary source of diabetes-related information had significantly higher odds of adequate literacy (OR = 1.59,  $p = 0.017$ ). No significant association was demonstrated between diabetes literacy and frequency of hospital admissions, medication adherence, and diabetes-related target organ damage.

#### CONCLUSION

Diabetes literacy among PLWD in HTJS and KKS is suboptimal, with notable gaps in awareness of the disease. Targeted, culturally tailored education strategies are essential to address these disparities and to empower them for effective diabetes self-management.

## EP\_A031

### ORAL ALPHA-LIPOIC ACID, VITAMIN B COMPLEX, AND VITAMIN E COMBINATION (BIONERV E+) FOR TREATING SYMPTOMATIC DISTAL SENSORY POLYNEUROPATHY: INTERIM ANALYSIS OF A RANDOMIZED, PLACEBO-CONTROLLED TRIAL

Fathimath Shazoo<sup>1,2</sup>, Ilham Ismail<sup>2</sup>, Rathika Rajah<sup>3</sup>, Wan Asyraf Wan Zaidi<sup>1,3</sup>, Rabani Remli<sup>1,3</sup>, Mahrunissa Mahadi<sup>2</sup>, Norlaila Mustafa<sup>1,2</sup>, Roszita Ibrahim<sup>4</sup>, Norasyikin A. Wahab<sup>1,2</sup>

<sup>1</sup>Department of Medicine, Faculty of Medicine, Universiti Kebangsaan Malaysia

<sup>2</sup>Endocrine Unit, Department of Medicine, Hospital Canselor Tuanku Muhriz

<sup>3</sup>Neurology Unit, Department of Medicine, Hospital Canselor Tuanku Muhriz

<sup>4</sup>Department of Community Health, Faculty of Medicine

#### INTRODUCTION

Diabetic sensorimotor polyneuropathy (DSPN) is a common complication of long-standing diabetes mellitus marked by neuropathic pain and sensory deficits. Evidence supporting combination antioxidant and vitamin-based therapy remains limited, particularly in patients with chronic disease. This study aims to determine symptom improvement after 12 weeks of oral alpha-lipoic acid, vitamin B complex, and vitamin E (Bionerv E+) in chronic diabetic patients with symptomatic DSPN.

#### METHODOLOGY

This single-centre, randomized, double-blind, placebo-controlled trial at HCTM enrolled 31 patients with symptomatic DSPN, assigned to Bionerv E+ ( $n = 16$ ) or placebo ( $n = 15$ ) for 12 weeks. Symptoms were assessed at baseline and post intervention using the Neuropathy Impairment Score-Lower Limb (NIS LL), Short Form McGill Pain Questionnaire (SF MPQ), Toronto Clinical Scoring System (TCSS), and nerve conduction studies (NCS).

## RESULTS

A total of 31 participants were recruited; 18 completed the study (11 intervention, 7 placebo). The cohort was predominantly elderly (median age  $68 \pm 12$  years), male (51.6%), with long-standing diabetes (mean duration of  $18.6 \pm 8.2$  years), and a mean hemoglobin A1c of  $7.3 \pm 0.6\%$ . A statistically significant reduction in TCSS score was observed in the intervention arm ( $5.5 \pm 3.8$  vs  $3.3 \pm 3.4$ ;  $p = 0.002$ ), indicating improvement in neuropathic symptom severity in this chronic population. The SF MPQ scores showed a downward trend in both arms, but were not statistically significant. Among intervention participants who completed sural NCS, three patients demonstrated normalization, and five showed partial amplitude gains, indicating directional improvement in nerve function. Four patients with normal baseline studies exhibited further amplitude gains. Otherwise, limited improvements were observed in those with abnormal conduction velocity parameters. Bionerv E+ was well tolerated, with only mild and self-limiting adverse events reported.

## CONCLUSION

Short-term supplementation with Bionerv E+ showed improvement in neuropathic symptoms among long-standing diabetic patients. However, longer-term studies with larger cohorts are necessary to determine its effects on patients with DSPN.

## EP\_A032

### EFFICACY AND SAFETY OF SGLT2 INHIBITORS IN ELDERLY ( $\geq 75$ YEARS) WITH TYPE 2 DIABETES: A REAL-WORLD STUDY

Siew Wai Shuit<sup>1</sup>, Shamharini Nagaratnam<sup>1</sup>, Fei Bing Yong<sup>1</sup>, Norisha Nandini Passkaren<sup>1</sup>, Keen Tien Boey<sup>1</sup>, Nur Syahirah Asarapoo<sup>1</sup>, Sathya Rajagopal<sup>1</sup>, Vikganesa Mahalingam<sup>1</sup>, Zanariah Hussein<sup>1</sup>

<sup>1</sup>Endocrine Unit, Medical Department, Hospital Putrajaya

## INTRODUCTION

Sodium-glucose-linked-transporter inhibitors (SGLT2-i) have demonstrated cardiovascular and renal benefits in type 2 diabetes mellitus (T2DM), but patients aged  $\geq 75$  years remain underrepresented in major trials, creating uncertainty regarding their risk-benefit profile. Real-world data show mixed safety signals. In Malaysia, local evidence is limited despite a growing elderly diabetic population. This study evaluates the glycemic efficacy and safety of SGLT2-i in advanced elderly patients in a real-world public hospital setting.

## METHODOLOGY

We conducted a retrospective observational cohort study of patients aged  $\geq 75$  years with T2DM initiated on SGLT2-i in Hospital Putrajaya (2020–2024). Electronic records were reviewed for demographics, comorbidities, medications, and biochemical parameters. Outcomes at 6–12 months assessed glycemic control and safety. Adverse events and discontinuation rates were recorded. Patients with incomplete data, type 1 diabetes, active malignancy, or severe renal impairment were excluded.

## RESULTS

A total of 104 patients (mean age 78.2 years; 54% female) were included with a high proportion (76.9%) classified as at high cardiovascular risk due to established macrovascular disease (57.7%) or nephropathy (53.8%). Indications for SGLT2-i initiation were glycemic control alone (69.2%) and together with cardiorenal protection (58.7%). Glycemic control remained stable (hemoglobin A1c: 7.66–7.45%;  $p = 0.076$ ), with preserved renal function (estimated glomerular filtration rate: 58.65–58.11 mL/min/1.73 m<sup>2</sup>;  $p = 0.575$ ). Overall safety was favorable, with 90.4% experiencing no adverse events. Minor adverse events included urinary tract infections (2.9%) and polyuria (1.9%). ASCVD-related hospitalizations occurred in 4.8% of patients, with a low discontinuation rate (7.7%). A statistically significant weight reduction was observed (baseline 66.67 kg,  $-1.01$  kg;  $p = 0.005$ ) but was not clinically significant. Proteinuria improvement was noted in 15.7% of patients.

## CONCLUSION

SGLT2-i are safe and well-tolerated in elderly T2DM patients ( $\geq 75$  years), with stable glycemic control, preserved renal function, and minimal adverse events, supporting their use in very elderly Asian populations.

## EP\_A033

### EXTREME GLYCEMIC SEVERITY AND MORTALITY RISK IN THE TB-DM CO-PANDEMIC: A RETROSPECTIVE ANALYSIS OF CLINICAL OUTCOMES

Mohammad Ulilamri Tukiman<sup>1</sup>, Chitra Devi Subramaniam<sup>1</sup>, Yusniza Yusoff<sup>2</sup>, Mohammad Nur Syafiq Mohamad Azman<sup>1</sup>, Choo Jia Qing<sup>1</sup>

<sup>1</sup>Department of Internal Medicine, Hospital Sungai Buloh

<sup>2</sup>Endocrine Unit, Department of Internal Medicine, Hospital Sungai Buloh

## INTRODUCTION

Tuberculosis patients with comorbid diabetes face a substantially higher risk of mortal outcomes. The “meta-inflammation” loop between hyperglycemia and tubercu-

losis (TB) infection exacerbates systemic severity and increases hazard rates for death. This study aims to quantify the association between baseline hemoglobin A1c (HbA1c) levels and all-cause mortality within a Malaysian cohort.

#### METHODOLOGY

This was a retrospective cross-sectional audit analyzing 131 adult TB-DM (diabetes mellitus) patients during their treatment course (2022–2025) in the TB Clinic, Hospital Sungai Buloh. Primary outcomes were all-cause mortality and clinical severity, stratified by baseline HbA1c and diabetes mellitus DM treatment modality (OHA vs. insulin).

#### RESULTS

The overall mortality rate was 17% (22/131). A stark disparity in glycemic control was observed between survivors and deceased patients: those who died presented with extreme mean HbA1c levels of 16.0%, compared to 10.5% in survivors. High HbA1c was also associated with a higher prevalence of pulmonary involvement compared to extrapulmonary disease (10.9% vs 8.9%). Patients requiring insulin therapy experienced significantly higher mortality rates compared to those managed on OHAs, with 25% (12 out of 47) patients requiring insulin therapy having died during TB treatment, compared to only 8.2% (7 out of 84) patients in the OHA-only group.

#### CONCLUSION

Baseline HbA1c is a critical prognostic marker that identifies a high-risk “lethal threshold” at extreme glycemic levels (HbA1c  $\geq 16$ ). Furthermore, the nearly fourfold increase in death risk among insulin-treated patients likely reflects a high-risk phenotype of advanced metabolic failure, which corresponds with a study done in Kelantan (Siti Rohana et al., 2020). The study shows that TB patients with DM had three times higher risk of developing unsuccessful TB treatment outcomes compared to TB patients without DM. Collectively, these data necessitate mandatory early HbA1c screening and aggressive metabolic management to reduce the staggering mortality of this dual epidemic.

## EP\_A034

### IMPACT OF GLYCEMIC CONTROL ON TUBERCULOSIS TREATMENT OUTCOMES IN PATIENTS WITH DIABETES MELLITUS: A RETROSPECTIVE AUDIT

**Chitra Devi Balasubramaniam<sup>1</sup>, Mohammad Ulilamri Tukiman<sup>1</sup>, Yusniza Yusoff<sup>2</sup>, Mohammad Nur Syafiq Mohammad Azman<sup>1</sup>, Choo Jia Qing<sup>1</sup>**

<sup>1</sup>Department of Internal Medicine, Hospital Sungai Buloh

<sup>2</sup>Endocrine Unit, Department of Internal Medicine, Hospital Sungai Buloh

#### INTRODUCTION

Diabetes mellitus (DM) is a significant comorbidity associated with adverse tuberculosis (TB) treatment outcomes and remains an ongoing clinical challenge. Chronic hyperglycemia impairs host immune responses, particularly macrophage function, leading to delayed bacillary clearance. This contributes to poorer outcomes, including delayed sputum conversion, prolonged treatment duration, relapse, and increased mortality. Poor glycemic control is a key modifiable factor influencing these outcomes. This study aimed to evaluate the impact of glycemic control at diagnosis on TB treatment outcomes in a Malaysian cohort.

#### METHODOLOGY

A retrospective cross-sectional audit was conducted using the TB clinic registry at Hospital Sungai Buloh from 2022 to 2025. Adult patients ( $\geq 18$  years) with confirmed TB (any form) and DM (Type 1 or Type 2) with complete records were included. Of 241 patients screened, 131 were included after exclusions due to incomplete records (29.9%), transfer (29.9%), loss to follow-up (19.9%), and drug-resistant TB (2.9%). Data collected included demographics, hemoglobin A1c (HbA1c) at diagnosis, sputum conversion duration, treatment duration, type of DM therapy, and clinical outcomes.

#### RESULTS

The cohort had a mean age of 53 years, with 97% having Type 2 DM.

Mean HbA1c at diagnosis was 10.5%. Poorer glycemic control was associated with delayed sputum conversion. Patients who achieved sputum conversion by 8 weeks had an average HbA1c of 9.6%, compared to 11.8% in those with delayed conversion. Longer treatment duration was associated with higher HbA1c (mean 10.5, 8.6, and 11.8% for 6-, 12-, and 18-month regimens, respectively). Relapse analysis demonstrated a trend towards higher HbA1c with increasing relapse episodes (11.2, 13.75, and 14.5% for one,

two, and three relapses, respectively). Overall mortality was 17% (22/131), with markedly higher mean HbA1c in deceased patients compared to survivors (16.0% vs 10.5%).

### CONCLUSION

Poor glycemic control at TB diagnosis is associated with delayed sputum conversion, prolonged treatment duration, and increased mortality. These findings are consistent with regional evidence, including a South Asian systematic review (Gautam et al., 2021), demonstrating higher mortality and treatment failure in patients with TB and DM. Early and aggressive optimization of glycemic control, alongside standard anti-TB therapy, is essential to improve outcomes.

## EP\_A035

### RISK STRATIFICATION AND REFERRAL PATTERNS FOR METABOLIC LIVER DISEASE IN TYPE 2 DIABETES: REAL-WORLD FIB-4 UTILIZATION

Calven Fu Hao Lim<sup>1</sup>, Min Chow<sup>1</sup>, Jess Jie Ying Ng<sup>1</sup>

<sup>1</sup>Gastroenterology and Hepatology Unit, Department of Medicine, Universiti Malaya

### INTRODUCTION

Metabolic dysfunction-associated steatotic liver disease (MASLD) is common among patients with type 2 diabetes (T2D) and increases the risk of cirrhosis, yet fibrosis often remains clinically silent until hepatic decompensation occurs. Current diabetes guidelines recommend non-invasive fibrosis risk stratification, such as the fibrosis-4 index (FIB-4), during routine diabetes care, but real-world adoption remains unclear. This study aimed to evaluate the implementation of FIB-4 as a risk stratification tool in patients with T2D.

### METHODOLOGY

This was a retrospective study of consecutive patients with T2D who were seen in the Diabetes Clinic of University of Malaya Medical Centre in 2023. Patients were identified as having a higher risk of future cirrhosis based on elevated FIB-4  $\geq 1.3$ .

### RESULTS

The data for 1,009 patients were analyzed, median age 62 (52–71) years, 40.7% male. Elevated FIB-4 was seen in 28.8% (291/1,009). Only 12.0% (35/291) with elevated FIB-4 were referred for further hepatology evaluation, whereas 3.3% (24/718) with low FIB-4 were referred. Among the patients with elevated FIB-4, those referred were more likely known to have hepatic steatosis, had higher alanine aminotransferase, aspartate aminotransferase, gamma-glutamyl transferase, and lower low-density lipoprotein

cholesterol and platelet count. Over a median follow-up of 1.71 (0.99–1.95) years, totaling 1,440 person-years, two liver-related events (0.2%) occurred (one each in the elevated and low FIB-4 group, respectively). Sixteen patients (4.0%) experienced cardiovascular events, including one patient (0.6%) in the elevated FIB-4 group and 15 (2.9%) in the low FIB-4 group.

### CONCLUSION

Despite automated FIB-4 reporting, this risk stratification tool was underutilized in T2D, resulting in missed opportunities for early identification and management of more severe liver disease. Integration of FIB-4 into diabetes care workflows, alongside structured referral pathways and clinician education, may improve early detection and reduce long-term hepatic complications in T2D.

## EP\_A036

### REAL-WORLD CLINICAL EXPERIENCE OF SUBCUTANEOUS SEMAGLUTIDE IN PUBLIC HOSPITAL-BASED DIABETES CARE: A RETROSPECTIVE OBSERVATIONAL STUDY

Zanariah Hussein<sup>1</sup>, Navin Kumar Loganadan<sup>1</sup>, Subashini Rajoo<sup>2</sup>

<sup>1</sup>Endocrine Institute Hospital Putrajaya

<sup>2</sup>Hospital Kuala Lumpur

### INTRODUCTION

Subcutaneous once-weekly semaglutide (Sema-OW) (0.5, 1.0 mg) has been available in Malaysia since 2020, but is currently not listed in the MOH Medicines Formulary. MOH clinicians prescribe Sema-OW for limited patient numbers, on a “named patient basis” following a closely regulated application process, permitting use once multilevel approval is obtained. Our study aims to report on the glycemic and weight-lowering outcomes of Sema-OW in a real-world MOH clinical setting.

### METHODOLOGY

A retrospective, single-arm, observational study was conducted in Hospital Putrajaya and Hospital Kuala Lumpur. The study population comprised adults with type 2 diabetes mellitus (T2DM) treated with Sema-OW for at least 6 months with hemoglobin A1c (HbA1c) and weight parameters available in their medical records. The primary endpoint was HbA1c change at 6 months. The secondary endpoints were the changes in HbA1c and weight from baseline to 12 months, proportion of patients achieving HbA1c  $< 7\%$ , and different levels of HbA1c reduction in 6 and 12 months ( $< 0.5$ ,  $0.5$ – $< 1.0$ ,  $1$ – $< 2$ ,  $\geq 2\%$ ). Changes in concomitant glucose-lowering medications were additionally observed.

## RESULTS

The cohort comprised 45 patients, with a mean age and disease duration of 53.3 and 16.3 years, respectively. Baseline mean weight was 100.3 kg, and body mass index (BMI) was 36.8 kg/m<sup>2</sup>, with 88% in the obese BMI category. Baseline HbA1c was 7.9%, and HbA1c reduction was 0.74% at 6 months and 0.84% at 12 months. The proportions of patients achieving HbA1c reduction of <0.5, 0.5–<1.0, 1.0–<2.0, and ≥2.0% were 8.9, 26.7, 26.7, and 8.9%, respectively. The mean weight reduction from baseline was 4.93 kg at 6 months and 6.73 kg at 12 months. Concomitant insulin therapy was observed in 44%, with 31% reduction in total daily insulin requirement at the end of the study, along with simplification of insulin regimens.

## CONCLUSION

Combination therapy with Sema-OW improved glycemic control with weight loss and enabled treatment deintensification in people with T2DM in Malaysian public tertiary diabetes care.

## EP\_A037

### IMPACT OF GLYCEMIC BURDEN ON RENAL FILTRATION DECLINE AND PROTEINURIA IN TYPE 1 DIABETES MELLITUS

Sian Lin Toh<sup>1</sup>, Chee Keong See<sup>2</sup>, Wei Hong Chin<sup>3</sup>

<sup>1</sup>Hospital Bentong

<sup>2</sup>Hospital Sultan Haji Ahmad Shah

<sup>3</sup>Universiti Malaya

## INTRODUCTION

Diabetic nephropathy is a major complication of type 1 diabetes mellitus (T1DM) and a leading cause of end-stage renal disease. This study aims to correlate long-term glycemic control and disease duration with renal decline, measured via estimated glomerular filtration rate (eGFR) and urinalysis proteinuria.

## METHODOLOGY

A retrospective cohort study was conducted among 15 patients with T1DM at Hospital Bentong. Independent variables were 3-year mean glycated hemoglobin A1c (HbA1c) and duration of diabetes. Dependent variables included the change in eGFR derived from baseline and latest serum creatinine (calculated using the CKD-EPI 2021 equation), and the shift in urine protein severity, mapped to an ordinal scale, over a 3-year follow-up. Multivariate linear regression and Spearman's rank correlation were utilized for analysis.

## RESULTS

The cohort consisted of 5 male patients and 10 female patients with a mean initial presentation HbA1c of 11.4%, a mean 3-year HbA1c of 9.15%, and a median disease duration of 11 years. Baseline eGFR was preserved (mean 117.15 mL/min/1.73 m<sup>2</sup>). Regression analysis revealed that for every 1% increase in mean HbA1c, eGFR declined significantly by 9.6 mL/min/1.73 m<sup>2</sup> ( $p = 0.002$ ). Furthermore, each additional year of disease duration independently reduced eGFR by 1.1 units ( $p = 0.008$ ). Spearman validation confirmed the strong negative correlation between HbA1c and eGFR ( $Rho = -0.664$ ,  $p = 0.006$ ). Conversely, the correlation between 3-year mean HbA1c and worsening proteinuria was not statistically significant ( $Rho = -0.067$ ,  $p = 0.827$ ), and patient gender did not significantly impact progression ( $p = 0.129$ ).

## CONCLUSION

Poor long-term glycemic control and longer duration of diabetes mellitus are strong independent predictors of decline in functional glomerular filtration in T1DM. While worsening proteinuria may not be detected during a short 3-year window using a standard urinalysis (UFEME), a more sensitive test such as Urine Albumin-to-Creatinine Ratio may better detect early structural kidney damage.

## EP\_A038

### CLINICAL AND BIOCHEMICAL CHARACTERISTICS OF ADULT DIABETIC KETOACIDOSIS: T1DM VS T2DM

Mohd Fyza Bahrudin<sup>1</sup>, Chin Voon Tong<sup>1</sup>, Raja Nurazni Raja Azwan<sup>1</sup>, Adilah Zulaikha Abd Latib<sup>1</sup>, Hidayatil Alimi Keya Nordin<sup>1</sup>, Qin Zhi Lee<sup>1</sup>, Kean Heng Lim<sup>1</sup>, Jia Ling Low<sup>1</sup>, Syaza Izhar Hisham<sup>1</sup>, Liang Wei Wong<sup>1</sup>, Jia Whey Jacelyn Ong<sup>2</sup>, Lisa Mohamed Nor<sup>2</sup>, Zanariah Hussein<sup>1</sup>

<sup>1</sup>Endocrine Unit, Medical Department, Hospital Putrajaya

<sup>2</sup>Clinical Research Centre, Hospital Putrajaya

## INTRODUCTION

The rising incidence of diabetic ketoacidosis (DKA) in type 2 diabetes mellitus (T2DM) represents a paradigm shift from its traditional recognition as a hallmark complication of type 1 diabetes mellitus (T1DM). However, contemporary data comparing clinical presentation, precipitating factors, and outcomes between these two populations remain limited.

## METHODOLOGY

In this retrospective observational study, all adult DKA admissions with T1DM or T2DM at a tertiary centre between 2001 and 2025 were studied. DKA was defined according to standard biochemical criteria. Electronic medical records

were reviewed to extract demographic data, biochemical parameters, precipitating factors, management details, and clinical outcomes of all adult DKA admission in T1DM and T2DM. Patients aged <18 years or those with incomplete data were excluded.

## RESULTS

A total of 601 DKA episodes were analyzed, comprising 130 (21.6%) in patients with T1DM and 471 (78.4%) in those with T2DM. Mean age was  $26.9 \pm 0.71$  years for T1DM and  $52.1 \pm 0.7$  years for T2DM. Gender distribution was balanced (male 48.3%, female 51.7%). Mean hemoglobin A1c (HbA1c) was  $11.3 \pm 0.3\%$  in T1DM and  $12.1 \pm 0.2\%$  in T2DM. Infection was the most common precipitating factor overall (69.0%), occurring more frequently in T2DM than in T1DM (74.7% vs. 56.2%), followed by medication non-adherence (62.4% vs. 43.8%). Significant differences were observed between groups in admission pH, bicarbonate (both  $p < 0.001$ ), blood ketones ( $p = 0.028$ ), and HbA1c ( $p = 0.010$ ), whereas anion gap ( $p = 0.056$ ) and blood glucose levels ( $p = 0.755$ ) did not differ significantly. Clinical outcomes were comparable with respect to intensive care unit (ICU) admission rates (40.0% in T1DM vs. 39.0% in T2DM,  $p = 0.779$ ) and median resolution time ( $p = 0.462$ ). However, the median length of hospital stay was significantly longer in T2DM ( $8.2 \pm 0.32$  vs.  $5.4 \pm 0.4$  days;  $p < 0.001$ ). Overall mortality was 6.0%, with substantially higher mortality in T2DM compared to T1DM (7.4% vs. 0.8%,  $p = 0.013$ ).

## CONCLUSION

In this large regional series of adult DKA, most episodes occurred in T2DM. Despite similar ICU admission rates and time to resolution, T2DM was associated with more frequent infection-related precipitants, longer hospital stays, and higher mortality, underscoring the need for targeted preventive strategies in this population.

## EP\_A039

### HIDDEN BURDEN OF DIABETES RISK AMONG HEALTHCARE WORKERS IN A TERTIARY HOSPITAL

Hui Soon Lim<sup>1</sup>, Ee Wen Loh<sup>1</sup>, Sing Yee Sim<sup>1,2</sup>, Pei Lin Chan<sup>1</sup>, Florence Hui Sieng Tan<sup>1</sup>

<sup>1</sup>Endocrinology Unit, Department of Medicine, Sarawak General Hospital

<sup>2</sup>Universiti Malaya Sarawak (UNIMAS)

## INTRODUCTION

The increasing prevalence of diabetes represents a significant global health challenge. Modifiable risk factors, including physical inactivity, unhealthy dietary habits,

and obesity contribute substantially to this rising burden. In conjunction with the 2025 World Diabetes Day (WDD) campaign focusing on “diabetes and the workplace,” we assessed diabetes risk among healthcare workers in our hospital using the Modified Asian Finnish Diabetes Risk Score (ModAsian FINDRISC).

## METHODOLOGY

Healthcare workers from various departments were invited to participate in the hospital WDD celebration. A total of 286 attendees underwent anthropometric measurements and completed the ModAsian FINDSRIC questionnaire. Descriptive statistics were used to summarize the prevalence of risk factors and overall diabetes risk.

## RESULTS

The participants included doctors, nurses, allied healthcare professionals, as well as hospital support and administrative staff. The majority of participants (74.8%) were aged below 45 years. 39.2% were overweight while 30.8% were obese. One-third (37.4%) had increased waist circumference (WC) ( $\geq 90$  cm for men,  $\geq 80$  cm for women). Additionally, 20% of respondents reported being on antihypertensive medication, and 23.8% had previously recorded high blood glucose. A family history of diabetes mellitus (DM) was reported by 62.6% of respondents. Additionally, about one-third were sedentary with less than 30 minutes of daily exercise or physical activity, another one-third did not consume fruits or vegetables on a daily basis. The median ModAsian FINDRISC score was 8, with approximately 30% of them classified as having moderate to very high risk of developing DM (moderate: 17.5%; high: 10.8%; very high: 2.8%).

## CONCLUSION

These results revealed high metabolic risk in healthcare workers and highlight the need for targeted workplace health promotion strategies to reduce the risk of developing diabetes.

## EP\_A040

### EFFECTIVENESS OF INSULIN DEINTENSIFICATION AND PREDICTORS OF GLYCEMIC CONTROL IN POORLY CONTROLLED TYPE 2 DIABETES MELLITUS: A RETROSPECTIVE COHORT STUDY IN MALAYSIAN PRIMARY CARE

Anuar Mohamad<sup>1</sup>, Mohd Ali 'Imran Ab Rahaman<sup>2</sup>, Ping Foo Wong<sup>1</sup>, Mohammad Zainie Hassan<sup>3</sup>, Miguelinda Vitus Kimsin<sup>1</sup>, Hiang Ngee Chan<sup>4</sup>, Megat Muhammad Haris Megat Zainal<sup>5</sup>

<sup>1</sup>Klinik Kesihatan Cheras

<sup>2</sup>Pejabat Kesihatan Cheras

<sup>3</sup>Klinik Kesihatan Temerloh

<sup>4</sup>Klinik Kesihatan Batu Muda

<sup>5</sup>Klinik Kesihatan Muhibbah

#### INTRODUCTION

Insulin deintensification is an emerging strategy to reduce hypoglycemia and treatment burden in patients on multiple daily injection (MDI  $\geq 3$ ), with potential to improve adherence and glycemic control. However, evidence in poorly controlled type 2 diabetes mellitus (T2DM) remains limited. This study evaluated its effectiveness and identified factors associated with achieving adequate glycemic control following deintensification among patients with poorly controlled T2DM attending Malaysian primary care.

#### METHODOLOGY

A retrospective cohort study was conducted among 107 T2DM patients with hemoglobin A1c (HbA1c)  $>9\%$ , attending Enhanced Diabetic Clinic at Cheras Health Clinic between 2021 and 2025. All patients on basal-bolus insulin (BBI) underwent deintensification. Multivariate logistic regression was performed to identify factors associated with achieving adequate glycemic control (HbA1c  $<7.5\%$ ). Changes in HbA1c following deintensification were assessed using paired t-tests.

#### RESULTS

Overall, 50.5% of patients achieved adequate glycemic control. Hypoglycemia events (AOR 9.5, 95% confidence interval [CI] 1.6–58.3;  $p = 0.015$ ), MDI (AOR 9.6, 95% CI 1.4–67.1;  $p = 0.023$ ) and Diabetes Medication Therapy Adherence Clinic (DMTAC) visits (AOR 1.1, 95% CI 1.0–1.2;  $p = 0.039$ ) were significantly associated with achieving HbA1c  $<7.5\%$ . Conversely, patients transitioned from BBI to premixed regimens were less likely to achieve HbA1c  $<7.5\%$  (AOR 0.22, 95% CI 0.05–0.93,  $p = 0.039$ ). All insulin deintensification strategies were associated with significant HbA1c improvements with transitioned from BBI to

premixed human insulin (mean difference  $-2.54\%$ , 95% CI 1.77–3.31,  $p < 0.001$ , Cohen's  $d = 1.09$ ), BBI to premixed analogue insulin (mean difference  $-3.38\%$ , 95% CI 2.26–4.49,  $p < 0.001$ , Cohen's  $d = 1.62$ ), BBI to basal insulin (mean difference  $-3.67\%$ , 95% CI 1.79–5.54,  $p = 0.004$ , Cohen's  $d = 2.05$ ).

#### CONCLUSION

Insulin deintensification is an effective strategy for improving glycemic control in poorly controlled T2DM. These findings highlight the importance of deintensification with careful consideration of hypoglycemia, MDI-related treatment burden, and patient engagement through regular DMTAC visits, which are integral to achieving optimal outcomes and support a personalized approach to diabetes management in primary care.

## EP\_A041

### IMPACT OF A RAPID OPTIMIZATION CLINIC ON GLYCEMIC CONTROL AND INSULIN DEINTENSIFICATION IN PATIENTS WITH DIABETES: AN EARLY RETROSPECTIVE AUDIT

Pang Hoy Yan<sup>1</sup>, Varuna Shashti Dhevi Marimuthu<sup>1</sup>, Amir Ridzwan Maula Mohd Nasir<sup>1</sup>, Muhammad Firdaus Ghani<sup>1</sup>, Chen Chiew Yee<sup>1</sup>, Hidayatil Alimi Keya Nordin<sup>1</sup>, Elliyyin Katiman<sup>1</sup>

<sup>1</sup>Endocrinology Unit, Tengku Permaisuri Norashikin (Kajang) Hospital

#### INTRODUCTION

Improving glycemic control while minimizing unnecessary insulin exposure is an important goal in diabetes management. The Rapid Optimization Clinic (ROC) was established as a structured multidisciplinary service to support therapy individualization, close follow-up, and timely insulin deintensification. This audit evaluated early changes in glycated hemoglobin A1c (HbA1c) and insulin treatment burden following ROC care over 3 months.

#### METHODOLOGY

We conducted a retrospective audit of routine clinical data from patients with diabetes managed in the ROC at a district hospital. Baseline and 3-month HbA1c and insulin data were extracted from non-electronic clinic records. Insulin dose was standardized as total daily dose (TDD) in units/kg/day. Insulin deintensification was evaluated primarily by change in TDD from baseline to 3 months and by the proportion of patients who discontinued insulin during follow-up. Paired analyses were performed for

patients with complete baseline and follow-up data for each outcome. Continuous variables are presented as mean  $\pm$  standard deviation or median with interquartile range, as appropriate. Exploratory analyses were undertaken to assess whether available patient factors were associated with HbA1c improvement.

## RESULTS

Twenty-three patients were included. Paired HbA1c data were available for 12 patients, whereas paired TDD data were available for 21 patients. Mean HbA1c decreased from  $10.78 \pm 2.59\%$  at baseline to  $8.42 \pm 2.29\%$  at 3 months, representing a mean reduction of 2.36 percentage points (95% confidence interval [CI] 0.09–4.62;  $p=0.043$ ). Mean TDD decreased from  $0.434 \pm 0.248$  to  $0.286 \pm 0.313$  units/kg/day, corresponding to a mean reduction of 0.148 units/kg/day (95% CI 0.077–0.219;  $p<0.001$ ). Insulin was discontinued in 9 of 21 patients (42.9%). No clear association was observed between HbA1c improvement and age, sex, or number of visits. Interpretation is limited by the small sample size, reflecting the early phase of a newly established clinic.

## CONCLUSION

In this early audit, ROC care was associated with clinically meaningful improvement in glycemic control and significant insulin deintensification over 3 months. These findings support the potential role of a structured multidisciplinary optimization clinic in delivering individualized diabetes care and facilitating safe reduction of insulin burden.

## EP\_A042

### RISK ASSESSMENT FOR RAMADAN FASTING IN PEOPLE WITH DIABETES IN HOSPITAL-BASED DIABETES CLINICS USING THE UPDATED 2026 IDF-DAR RISK CALCULATOR

**Raja Nurazni Raja Azwan<sup>1</sup>, Chin Voon Tong<sup>1</sup>, Lisa Mohamed Nor<sup>1</sup>, Marisa Khatijah Borhan<sup>2</sup>, Syarifah Syahirah Syed Abas<sup>3</sup>, Poh Shean Wong<sup>4</sup>, Ying Jie Tan<sup>5</sup>, Shartiyah Ismail<sup>6</sup>, Eunice Yi Chwen Lau<sup>7</sup>, Yueh Chien Kuan<sup>8</sup>, Noor Hafis Md Tob<sup>9</sup>, Shu Teng Chai<sup>10</sup>, Pei Lin Chan<sup>11</sup>, Xe Hui Lee<sup>12</sup>, Wei Wei Ng<sup>13</sup>, Jin Hui Ho<sup>14</sup>, Miza Hiriyanti Zakaria<sup>15</sup>, Rabeah Md Zuki<sup>16</sup>, Wan Mohd Hafez Wan Hamzah<sup>17</sup>, Melissa Vergis<sup>18</sup>, Choon Peng Sun<sup>19</sup>, Vanusha Devaraja Pillai<sup>20</sup>, Chee Koon Low<sup>21</sup>, Shazatul Reza Mohd Redzuan<sup>22</sup>, Xin-Yi Ooi<sup>23</sup>, Siti Sanaa Wan Azman<sup>24</sup>, Deviga Lachumanan<sup>25</sup>, Saiful Shahrizal Shudim<sup>26</sup>, Zanariah Hussein<sup>1</sup>**

<sup>1</sup>Institut Endokrin, Hospital Putrajaya

<sup>2</sup>Hospital Raja Perempuan Zainab II

<sup>3</sup>Hospital Sultan Ismail

<sup>4</sup>Hospital Tuanku Jaafar

<sup>5</sup>Hospital Seberang Jaya

<sup>6</sup>Hospital Sultanah Bahiyah

<sup>7</sup>Hospital Sibul

<sup>8</sup>Hospital Miri

<sup>9</sup>Hospital Sultanah Aminah

<sup>10</sup>Hospital Sultanah Nora Ismail

<sup>11</sup>Hospital Umum Sarawak

<sup>12</sup>Hospital Pulau Pinang

<sup>13</sup>Hospital Raja Permaisuri Bainun

<sup>14</sup>Hospital Queen Elizabeth II

<sup>15</sup>Hospital Sultanah Maliha (Langkawi)

<sup>16</sup>Hospital Sultan Abdul Halim

<sup>17</sup>Hospital Sultanah Nur Zahirah

<sup>18</sup>Hospital Sultan Idris Shah (Serdang)

<sup>19</sup>Hospital Teluk Intan

<sup>20</sup>Hospital Melaka

<sup>21</sup>Hospital Tengku Ampuan Afzan

<sup>22</sup>Hospital Kuala Lumpur

<sup>23</sup>Hospital Tengku Ampuan Rahimah

<sup>24</sup>Hospital Selayang

<sup>25</sup>Hospital Port Dickson

<sup>26</sup>Hospital Sultan Haji Ahmad Shah

## INTRODUCTION

The 2021 IDF-DAR risk calculator had been previously evaluated in multiple studies and subsequently widely accepted and applied in clinical practice as a practical standardized tool for patient risk stratification. Recently updated, the 2026 IDF-DAR Risk calculator enables a more

individualized, evidence-related evaluation of patient-related and disease-related risk factors, incorporating modern diabetes technologies, including continuous glucose monitoring (CGM), automated insulin delivery (AID) systems, and advanced insulin formulations to enhance risk stratification. This tool allows medical professionals to tailor Ramadan practices based on overall factors toward promoting safe fasting.

#### METHODOLOGY

This prospective multicentre observational study recruited adults with Type 1 and Type 2 diabetes attending public hospitals nationwide. People with diabetes (PwD) intending to perform Ramadan fasting were invited to participate and assessed using the 2026 IDF-DAR Risk Calculator in the 6-week pre-Ramadan period between 30<sup>th</sup> January and 19<sup>th</sup> March 2026.

#### RESULTS

A total of 458 PwD were evaluated and stratified into low (15.7%), moderate (41%), and high risk (43.3%) categories. Most participants had Type 2 diabetes (83.6%), with 60.3% having a disease duration exceeding 10 years and 43% exhibiting poor glycemic control (hemoglobin A1c >9%). Insulin therapy was used by 76.4% of participants, including two individuals with Type 1 diabetes using AID systems. Most participants reported no recent hypoglycemia (76.4%), 81.0% performed glucose monitoring, and 3.3% used CGM. Severe comorbidities were uncommon, with 1.1% having unstable macrovascular disease and 4.4% advanced chronic kidney disease (estimated glomerular filtration rate <30). Notably, 72.2% received structured Ramadan education.

#### CONCLUSION

Majority of PwD attending tertiary diabetes clinics were in the moderate- to high-risk category and intended to fast despite medical advice against fasting in some cases. Although most participants were on insulin therapy, hypoglycemia was low in the pre-Ramadan period. Integration of modern technologies, advanced insulin therapies, and structured education may support safer fasting practices.

## EP\_A043

### EFFECTIVENESS OF ORAL SEMAGLUTIDE VERSUS INJECTABLE DULAGLUTIDE IN ADULTS WITH TYPE 2 DIABETES AND OBESITY: A SINGLE-CENTRE EXPERIENCE

Nur Shairah Binti Mohamad Fazial<sup>1</sup>, Raja Yunalis Binti Raja Iskandar<sup>1</sup>, Nur Syuhaida Binti Noorazam<sup>1</sup>, Saiful Shahrizal Bin Shudim<sup>1</sup>

<sup>1</sup>Hospital Sultan Haji Ahmad Shah

#### INTRODUCTION

Glucagon-like peptide-1 receptor agonists (GLP-1 RAs) are increasingly used in the management of type 2 diabetes mellitus (T2DM) and obesity because of their glucose-lowering and weight reduction benefits. However, real-world outcomes may differ from clinical trial data.

#### METHODOLOGY

This retrospective cohort study included adults with T2DM and obesity initiated on oral semaglutide or injectable dulaglutide at Hospital Sultan Haji Ahmad Shah between 2023 and 2025. Baseline and approximately 6-month follow-up data were obtained from electronic medical records. Outcomes included weight, body mass index (BMI), glycated hemoglobin A1c (HbA1c), total daily insulin dose (TDD), low-density lipoprotein (LDL), and gastrointestinal adverse effects. Results are presented as median (interquartile range, IQR).

#### RESULTS

A total of 22 patients were included, with a median age of 45 years (IQR 39.3–54.5); 13 (59.1%) were male. Thirteen patients (59.1%) received oral semaglutide and nine (40.9%) received injectable dulaglutide. In the semaglutide group, median HbA1c changed from 8.1% (7.4–9.1) to 8.2% (7.1–9.3), weight from 95.4 kg (84.0–99.1) to 89.6 kg (79.0–100.0), BMI from 33.9 kg/m<sup>2</sup> (31.4–40.8) to 33.6 kg/m<sup>2</sup> (31.2–35.6), TDD from 64 IU/day (20–82) to 46 IU/day (18–48), and LDL from 2.2 mmol/L (1.6–2.3) to 2.3 mmol/L (1.3–3.0). In the dulaglutide group, median HbA1c improved from 7.6% (7.4–9.6) to 6.9% (6.5–8.4), weight from 117.0 kg (101.0–121.0) to 111.0 kg (105.0–119.0), BMI from 41.0 kg/m<sup>2</sup> (40.0–49.0) to 42.5 kg/m<sup>2</sup> (38.0–48.0), TDD from 33 IU/day (30.5–34.0) to 34 IU/day (30.5–34.0), and LDL from 2.2 mmol/L (1.8–2.9) to 2.6 mmol/L (2.0–4.0). Gastrointestinal side effects occurred in 4/13 (30.8%) oral semaglutide users and 0/9 dulaglutide users.

#### CONCLUSION

Injectable dulaglutide showed greater improvement in HbA1c, while both groups demonstrated variable effects on weight, BMI, insulin requirement, and LDL in routine practice.

## EP\_A044

### GLYCEMIC AND METABOLIC OUTCOMES OF GLP-1 RECEPTOR AGONISTS IN TYPE 2 DIABETES: A SINGLE-CENTRE CLINICAL AUDIT

Shinye Eng<sup>1</sup> and Rabeah Md Zuki<sup>1</sup>

<sup>1</sup>Hospital Sultan Abdul Halim

#### INTRODUCTION

Glucagon-like peptide-1 receptor agonists (GLP-1 RAs) improve glycemic control, promote weight loss, reduce insulin requirements, and confer cardiometabolic benefits in type 2 diabetes mellitus (T2DM). This audit evaluated glycemic and metabolic outcomes of GLP-1 RAs in T2DM patients at a single-centre diabetes clinic.

#### METHODOLOGY

This audit included T2DM patients who initiated GLP-1 RAs between January 2022 and March 2025 at Hospital Sultan Abdul Halim. Primary outcomes were changes in hemoglobin A1c (HbA1c), body weight, and body mass index (BMI) at 3 and 12 months. Secondary outcomes included percentage weight loss, changes in systolic blood pressure (SBP), insulin total daily dose (TDD), low-density lipoprotein (LDL) cholesterol, gastrointestinal adverse effects, and treatment discontinuation.

#### RESULTS

Sixteen patients were included; median age was 58.5 years (interquartile range [IQR] 47.5–65), and 56.3% were female. Median diabetes duration was 15 years (IQR 11.5–20.3). Median HbA1c decreased from 9.7% (IQR 8.6–10.4) at baseline to 8.8% (IQR 7.7–9.1) at 3 months and 7.8% (IQR 7.0–8.5) at 12 months. Body weight decreased from 88.1 kg (IQR 79.5–122.1) at baseline to 85.0 kg (IQR 75.9–113.7) at 3 months and 82.0 kg (IQR 74.8–117.3) at 12 months. BMI decreased from 37.8 kg/m<sup>2</sup> (IQR 31.7–47.1) to 37.3 kg/m<sup>2</sup> (IQR 30.7–45.5) at 3 months and 36.0 kg/m<sup>2</sup> (IQR 30.1–45.6) at 12 months.

At 12 months, weight loss was 5.8% (IQR 3.0–8.0), with 56.5% achieving >5% weight reduction. In all, 93.8% achieved >1% HbA1c reduction. Mean SBP decreased by 10 ± 20 mmHg, LDL cholesterol 0.29 mmol/L (IQR -0.77 to 0.07), and insulin TDD 8 units/day (IQR -13 to 10). No gastrointestinal adverse effects reported. Three patients (18.8%) discontinued treatment due to excessive weight loss, treatment plateau, and limited drug availability.

#### CONCLUSION

From our single-centre experience, the observed improvements in glycemic and metabolic outcomes support the benefits of GLP-1 RAs in managing T2DM.

## EP\_A045

### A CLINICAL AUDIT OF DIABETIC RETINOPATHY SCREENING AMONG TYPE 2 DIABETES MELLITUS PATIENTS ATTENDING PUSAT PERUBATAN ANGKATAN TENTERA, SG BESI

Maizatulifah Miskan<sup>1</sup>, Hasliza Abu Hassan<sup>1</sup>, Ng Kien Keat<sup>1</sup>, Ambigga Devi<sup>1</sup>, Aida Jaffar<sup>1</sup>, Siti Salmiah Awang<sup>2</sup>

<sup>1</sup>Department of Primary Care Medicine, Faculty of Medicine and Defence Health, National Defence University of Malaysia

<sup>2</sup>Pusat Perubatan Angkatan Tentera Sg. Besi

#### INTRODUCTION

Diabetic retinopathy (DRP) is the most common microvascular complication of diabetes, affecting approximately 30% of patients with type 2 diabetes and over half of those with type 1 diabetes. It remains a leading cause of preventable blindness among adults worldwide. Early stages are frequently asymptomatic, making regular diabetic eye screening essential to detect sight-threatening changes before irreversible vision loss occurs. In Malaysia, where diabetes prevalence has reached 15.6% among adults (NHMS 2023), the effective implementation of annual retinal screening is crucial. Malaysian National Clinical Practice Guidelines recommend an annual retinal screening among type 2 diabetes mellitus (T2DM) patients. This clinical audit evaluated adherence to DRP screening.

#### METHODOLOGY

A retrospective clinical audit was conducted at Pusat Perubatan Angkatan Tentera (PPAT), Kem Sungai Besi, to evaluate compliance with national DR screening standards among adults with T2DM. Thirty eligible patient records were reviewed. Three key indicators were assessed: (1) documentation of visual acuity at diagnosis, (2) annual funduscopy, and (3) referral for fundus photography within the preceding 12 months. Performance was benchmarked against the 80% standard. Data were analyzed descriptively.

#### RESULTS

The median age group was 55–59 years, with equal gender distribution. Screening adherence was substantially below target: visual acuity assessment at diagnosis, 23.3%; annual funduscopy, 26.7%; and fundus imaging referral, 36.7%. All screening indicators were below the recommended standard.

#### CONCLUSION

This audit reveals a significant implementation gap between national guidelines and routine practice. Structured workflow integration and documentation reinforcement strategies need to be emphasized. Additional measures

include strengthening patient education and reinforcing guideline-based practice through regular CME sessions. However, a re-audit has not yet been conducted at the time of clinical audit reporting. An ongoing evaluation will be essential to determine the effectiveness and sustainability of these interventions in reducing preventable diabetic vision loss at PPAT Sungai Besi.

## EP\_A046

### PREVALENCE OF THYROID DYSFUNCTION IN TYPE 2 DIABETES MELLITUS AND ITS ASSOCIATION WITH BODY FAT MASS INDEX

Nabilah Farhana Hamidi<sup>1</sup>, Nur Aini Eddy Warman<sup>1</sup>, Rohana Abdul Ghani<sup>1</sup>, Xin Wee Chen<sup>2</sup>

<sup>1</sup>Endocrine Unit, Faculty of Medicine, Universiti Teknologi MARA (UiTM)

<sup>2</sup>Department of Public Health, Faculty of Medicine, Universiti Teknologi MARA

#### INTRODUCTION

Type 2 diabetes mellitus (T2DM) and thyroid disorders are common endocrine conditions with a bidirectional relationship affecting glucose and lipid metabolism. Adiposity, particularly fat mass index (FMI), may influence thyroid function, but its association with thyroid dysfunction and glycemic control remains unclear, especially in Malaysia. This study aimed to determine the prevalence of thyroid dysfunction in T2DM and its association with glycemic control and FMI at Universiti Teknologi MARA (UiTM).

#### METHODOLOGY

A cross-sectional study was conducted among patients with T2DM attending the Endocrine Clinic, UiTM, from December 2025 to March 2026. A total of 91 participants aged 18–70 years were recruited using convenience sampling. Demographic, clinical, anthropometric, and laboratory data were collected. Thyroid dysfunction was defined as thyroid-stimulating hormone (TSH) <0.38 or >5.33 mIU/L. Body composition was assessed using the InBody 380 to determine FMI. Data were analyzed using SPSS version 30 with descriptive statistics and Pearson correlation.

#### RESULTS

The prevalence of thyroid dysfunction among patients with T2DM was 7.7% (7/91), predominantly with low TSH levels. Mean hemoglobin A1c (HbA1c) in the overall study population was 7.59 ± 1.49%, and mean TSH was 1.42 ± 0.95 mIU/L, within the euthyroid range. Mean FMI was 11.95 ± 5.23 kg/m<sup>2</sup>, exceeding normal ranges for both men (3–6 kg/m<sup>2</sup>) and women (5–9 kg/m<sup>2</sup>). FMI showed a positive correlation with TSH level ( $r = 0.379$ ,  $p < 0.001$ ),

indicating that higher adiposity was associated with higher TSH levels despite remaining within the euthyroid range. Pearson correlation showed a weak, non-significant negative correlation between HbA1c and TSH ( $r = -0.127$ ,  $p = 0.229$ ).

#### CONCLUSION

The prevalence of thyroid dysfunction among patients with T2DM in our cohort was relatively low at 7.7%. However, the significant correlation between FMI and TSH level, even within the euthyroid range, suggests that adiposity may exert a clinically relevant influence on thyroid function.

## EP\_A047

### REAL-WORLD CONTINUOUS GLUCOSE MONITORING PATTERNS IN MALAYSIAN ADULTS WITH TYPE 2 DIABETES: A SINGLE-CENTRE STUDY

Ryan Jia Xian Koh<sup>1</sup>, Siti Nabilah Atiqah Othman<sup>2</sup>, Maszariffah Mashor<sup>2</sup>, Azni Abdul Latif<sup>2</sup>, Ooi Chuan Ng<sup>1</sup>

<sup>1</sup>Faculty of Medicine & Health Sciences UPM

<sup>2</sup>Department of Medicine, Hospital Sultan Abdul Aziz Shah UPM

#### INTRODUCTION

Malaysia has one of the highest diabetes prevalence rates in Asia (1 in 5), with >50% fail to achieve optimal glycemic control. Continuous glucose monitoring (CGM) provides detailed insights beyond hemoglobin A1c (HbA1c), capturing daily glucose fluctuations and variability. Real-world data describing CGM patterns and their clinical associations in Malaysian adults with type 2 diabetes mellitus (T2DM) are limited.

#### METHODOLOGY

This cross-sectional study analyzed CGM data from 25 Malaysian adults with T2DM, standardized over 14 days. CGM metrics included time in range (TIR), time above range (TAR), time below range (TBR), mean glucose, and coefficient of variation (CV). Weekday-weekend comparisons were performed, and correlations with age, diabetes duration, HbA1c, body mass index (BMI), treatment regimen, and complications were assessed.

#### RESULTS

Participants had a mean age of 56.2 ± 13.2 years (52% male), mean HbA1c 9.4 ± 2.7%, diabetes duration 10.7 ± 9.0 years, and BMI 29.8 ± 9.4 kg/m<sup>2</sup>. Mean TIR, TAR, TBR, mean glucose, and CV were similar between weekdays and weekends ( $p > 0.34$  for all). TIR >70% was achieved by 52% of participants on weekdays and 48% on weekends, with no statistically significant difference ( $p = 0.75$ ). Longer diabetes duration correlated with lower TIR ( $r = -0.62$ ,  $p$

<0.001), higher mean glucose ( $r = 0.58, p = 0.002$ ), and greater variability ( $r = 0.54, p = 0.004$ ). Older age was associated with lower TIR ( $r = -0.48, p = 0.014$ ) and higher mean glucose ( $r = 0.44, p = 0.025$ ). Higher HbA1c correlated with lower TIR ( $r = -0.36, p = 0.04$ ), higher TAR ( $r = 0.35, p = 0.05$ ), greater variability ( $r = 0.51, p = 0.006$ ), and increased target organ damage ( $q = 0.55, p = 0.004$ ). BMI was not associated with TIR ( $r = -0.18, p = 0.38$ ). Participants with  $\geq 2$  complications had lower TIR ( $55.8 \pm 28.4\%$  vs  $76.7 \pm 19.2\%$ ,  $p = 0.073$ ), while insulin therapy was associated with higher TBR ( $r = 0.42, p = 0.03$ ).

### CONCLUSION

In Malaysian adults with T2DM, CGM metrics were similar between weekdays and weekends, indicating lifestyle differences had minimal impact on glycemic control. Longer diabetes duration, older age, higher HbA1c, multiple complications, and insulin therapy identified patients at highest risk for poor glycemic control, greater variability, and hypoglycemia. These findings support the use of CGM for risk stratification, individualized monitoring, and therapy optimization to reduce complications and hypoglycemia risk.

## EP\_A048

### EUGLYCEMIC DIABETIC KETOACIDOSIS: CLINICAL INSIGHTS FROM A TERTIARY-CENTRE COHORT

Jia Ling Loh<sup>1</sup>, Chin Voon Tong<sup>1</sup>, Lisa Mohamed Nor<sup>2</sup>

<sup>1</sup>Institut Endokrin, Hospital Putrajaya

<sup>2</sup>Clinical Research Centre, Hospital Putrajaya

#### INTRODUCTION

Euglycemic diabetic ketoacidosis (EDKA) is an uncommon but potentially life-threatening complication of diabetes, characterized by significant ketoacidosis in the absence of marked hyperglycemia. The increasing use of sodium-glucose co-transporter-2 inhibitors (SGLT2i) has contributed to its rising incidence; however, data describing its clinical spectrum remain limited.

#### METHODOLOGY

We conducted a retrospective observational study of 19 patients admitted for EDKA between 2002 and 2025. EDKA was defined as metabolic acidosis with ketosis in the presence of blood glucose  $< 11$  mmol/L. Demographic characteristics, comorbidities, biochemical parameters, triggers, and clinical outcomes were analyzed. Continuous variables were reported as mean (SD) or median (interquartile range [IQR]), and categorical variables as frequencies and percentages.

### RESULTS

The cohort displayed a mean age of 52 (SD 22.2) years, with a slight female predominance (52.6%). The majority had underlying type 2 diabetes mellitus (89.5%). Other comorbidities include hypertension (63.2%) and chronic kidney disease (31.6%). Despite severe metabolic derangement, the mean blood glucose at presentation was modest at 9.3 (SD 3.38) mmol/L. Median pH was 7.1 (IQR 0.35) and bicarbonate 9.1 mmol/L, with a markedly elevated median anion gap of 25.3 mmol/L.

SGLT2i exposure was identified in 47.4% of patients, predominantly empagliflozin, with most initiated within 6 months. Nevertheless, infection was still the leading precipitant (68.4%), while 31.6% were adjudicated as having SGLT2i as the primary precipitating factor, probably due to underreporting during the diagnosis. Nearly half of the patients required intensive care (47.4%). The mean time to DKA resolution was 19 (SD 10.1) hours. Overall outcomes were favorable, with 89.5% of patients discharged and a mortality rate of 10.5%.

### CONCLUSION

EDKA presents with severe metabolic acidosis despite deceptively normal glucose levels, increasing the risk of delayed recognition. Early assessment of ketones and acid-base status is essential in patients with diabetes presenting with unexplained metabolic acidosis, particularly among those receiving SGLT2 inhibitors, to facilitate timely diagnosis and management.

## EP\_A049

### AUDIT OF STAFF KNOWLEDGE OF HYPOGLYCEMIA MANAGEMENT IN A DISTRICT HOSPITAL

Hong Lee Hoong<sup>1</sup>, Low Chee Koon<sup>2</sup>, Abdullah Shamshir Abd Mokti<sup>2</sup>

<sup>1</sup>Medical Department, Hospital Raub

<sup>2</sup>Endocrine Unit HTAA

#### INTRODUCTION

Hypoglycemia, a frequent and potentially life-threatening consequence of anti-diabetic therapy, remains a major barrier to optimal glycemic control. Effective inpatient management depends on frontline staff knowledge and preparedness; thus, knowledge gaps may compromise patient safety. This audit evaluated staff knowledge of hypoglycemia management in a district hospital in Malaysia to identify areas for improvement.

## METHODOLOGY

A cross-sectional audit was conducted among healthcare staff in a district hospital. A structured, modified questionnaire based on the Malaysian MEMS Inpatient Glycemic Guidelines was used. The 10-item questionnaire assessed definition, initial and subsequent management, reassessment, escalation, and documentation, yielding scores from 0 to 10. Descriptive statistics were used for analysis.

## RESULTS

A total of 100 healthcare staff participated, comprising 6% doctors, 73% nurses, 14% MAs, and 7% pharmacists. Of these, 46% were from medical departments and 54% from non-medical departments; 71% were inpatient staff and 29% outpatient staff. Participants had a median working experience of 14 years. Overall knowledge levels were high, with pharmacists achieving the highest median score of 10 (interquartile range [IQR] 1), followed by doctors, nurses, and MAs, all scoring a median of 9 (IQR 0–1). Knowledge scores were similar between diabetic-trained and non-diabetic-trained staff, both recording a median score of 9 (IQR 1). The lowest performance was observed in key domains related to reassessment of blood glucose (41% wrong), drug-related considerations (17%), and subsequent management (15%). Median scores were comparable between inpatient and outpatient staff (9 [IQR 2] vs 9 [IQR 1]), and across staff with varying years of working experience. Staff from medical departments achieved slightly higher scores than those from non-medical departments (10 [IQR 1] vs 9 [IQR 1]).

## CONCLUSION

Despite high overall knowledge, critical gaps remain in reassessment, drug-related risks, and stepwise management, warranting targeted education, protocol reinforcement, and re-audit to enhance patient safety.

## EP\_A050

### AUDIT ON HbA1c TEST UTILIZATION AT HOSPITAL TELUK INTAN IN 2025

Sun Choon Peng<sup>1</sup>, Syazana Jan Shari<sup>1</sup>, Maisara Idris<sup>1</sup>

<sup>1</sup>Hospital Teluk Intan

## INTRODUCTION

Hemoglobin A1c (HbA1c) is fundamental in the diagnosis and longitudinal monitoring of diabetes mellitus. Appropriate utilization is essential to ensure optimal glycemic control, cost-effectiveness, and laboratory efficiency. Regular audits are crucial for assessing adherence to testing intervals and for identifying gaps in diabetes management. The aim was to evaluate the utilization pattern and glycemic outcomes of HbA1c testing at Hospital Teluk Intan in 2025.

## METHODOLOGY

A retrospective descriptive audit was conducted using Laboratory Information System data from 1 January to 31 December 2025. All HbA1c tests performed during the study period were included. Rejected samples and duplicate tests within 3 months for the same patient were excluded. Data were analyzed for test volume, inpatient versus outpatient distribution, age group, and glycemic control categories.

## RESULTS

A total of 10,208 HbA1c tests were performed, with 987 (9.7%) rejected samples. Among valid requests, 3,561 (34.9%) were inpatient and 5,660 (55.4%) were outpatient. Adults accounted for 9,196 tests (90.1%), while paediatric requests were minimal ( $n = 25$ ).

Regarding glycemic status, 4,502 (44.1%) had HbA1c <6.5%, and 828 (8.1%) were between 6.5 and 7.0%. Suboptimal control (7.0–10.0%) was observed in 2,443 patients (23.9%), while 1,448 (14.2%) demonstrated poor control (>10.0%). Overall, 38.1% of patients had HbA1c  $\geq$ 7.0%, indicating inadequate glycemic control.

## CONCLUSION

HbA1c testing at Hospital Teluk Intan is predominantly utilized in adult and outpatient settings. Despite substantial testing volume, over one-third of patients demonstrated suboptimal or poor glycemic control, underscoring persistent therapeutic gaps. These findings highlight the need for strengthened diabetes management strategies and targeted quality improvement initiatives to enhance glycemic outcomes and optimize resource utilization.

## EP\_A051

### GLOBAL DIAGNOSTIC CRITERIA FOR GESTATIONAL DIABETES MELLITUS: A SCOPING REVIEW PROTOCOL TO INFORM POLICY IN MALAYSIA

Siti Sarah Hamzah<sup>1</sup>, Shazana Rifham Abdullah<sup>1</sup>, Nur Zati Iwani Ahmad Kamil<sup>1</sup>, Liyana Ahmad Zamri<sup>1</sup>, Nur Azlin Zainal Abidin<sup>1</sup>, Sharifah Nortasya Sayed Muhamad Kamarudin<sup>1</sup>

<sup>1</sup>Institute for Medical Research (IMR)

## INTRODUCTION

Gestational diabetes mellitus (GDM) is a common pregnancy complication associated with adverse maternal and neonatal outcomes, including hypertensive disorders, caesarean delivery, macrosomia, and increased lifetime risk of type 2 diabetes. Despite its clinical importance, considerable international variation exists in GDM screening and diagnostic criteria. Multiple frameworks

are currently used, including those from the World Health Organization (WHO), International Association of Diabetes and Pregnancy Study Groups, Carpenter and Coustan, and the National Diabetes Data Group. Differences in glucose thresholds, testing protocols (one-step versus two-step), and universal versus risk-based screening contribute to heterogeneity in reported prevalence and healthcare burden. In multi-ethnic, middle-income settings such as Malaysia, identifying an evidence-informed and context-appropriate diagnostic approach is critical.

#### METHODOLOGY

This scoping review follows the Joanna Briggs Institute methodology and will be reported in accordance with the PRISMA Extension for Scoping Reviews (PRISMA-ScR). PubMed, Scopus, and ScienceDirect will be searched for English-language studies, reviews, guidelines, and consensus statements reporting GDM diagnostic criteria. Two reviewers will independently screen and select studies.

#### RESULTS

Data will be charted on country, study type, diagnostic criteria, gestational age at screening, and reported challenges. Findings will be synthesized descriptively and presented in tables and figures. No formal risk-of-bias assessment will be conducted.

#### CONCLUSION

This review will provide a comprehensive overview of global diagnostic practices, highlight variations and gaps, and support evidence-based selection of a suitable GDM screening and diagnostic strategy for Malaysia.

## EP\_A052

### SURVEY OF AWARENESS OF ARTIFICIAL INTELLIGENCE IN DIABETES CARE AMONG ENDOCRINOLOGISTS IN MALAYSIA

Jia Miin Sun<sup>1</sup> and Chee Keong See<sup>1</sup>

<sup>1</sup>Hospital Sultan Haji Ahmad Shah

#### INTRODUCTION

Artificial intelligence (AI) and digital health technologies are increasingly integrated into diabetes care. However, data on awareness and adoption among endocrinologists in Malaysia remain limited.

#### METHODOLOGY

A cross-sectional survey was conducted among endocrinologists in Malaysia using a structured online questionnaire. Items assessed awareness of AI-based diabetes technologies, attitudes toward AI in clinical care, perceived barriers, and willingness to adopt AI tools. Multiple responses were permitted for selected items.

#### RESULTS

The cohort ( $N = 65$ ) comprised 60% junior endocrinologists and 40% senior endocrinologists (72% government-based). Recognition was higher for monitoring and screening technologies, particularly continuous glucose monitoring (CGM) data analytics (66.2%) and automated retinopathy screening (33.8%) versus therapeutic AI tools, such as lifestyle coaching applications (43.1%) and insulin titration algorithms (30.8%). While approximately 60% endocrinologists reported familiarity with AI in diabetes care, 15.4% of them had no prior recognition of AI tools.

Attitudes toward AI were largely positive; 76% agreed that AI improves diabetes outcomes, 60% believed it reduces clinician workload, and 90% agreed that AI would complement diabetes care systems. However, approximately 50% remained neutral regarding its reliability and expressed concerns about ethics and data security.

In practice, only 40% endocrinologists reported using AI tools, most commonly CGM analytics with automated insights (46.4%), with generally low frequency of use. The main barriers to adoption were lack of formal training (78.5%) and high implementation costs (60%). Despite this, 90% expressed willingness to adopt AI in future practice.

#### CONCLUSION

Awareness of AI technologies in diabetes care among Malaysian endocrinologists is variable, with stronger recognition of tools already embedded in routine practice. While attitudes toward AI are favorable, significant educational and structural barriers must be addressed to facilitate broader implementation.

## EP\_A053

### DIABETIC KETOACIDOSIS IN PREGNANCY: CLINICAL TRIGGERS, OUTCOMES, AND MISSED OPPORTUNITIES—A CASE SERIES

Jia Whey Jacelyn Ong<sup>1</sup>, Chin Voon Tong<sup>1</sup>, Raja Nurazni binti Raja Azwan<sup>2</sup>, Adilah Zulaikha binti Abd Latib<sup>2</sup>, Hidayatil Alimi bin Keya Nordin<sup>2</sup>, Qin Zhi Lee<sup>2</sup>, Kean Heng Lim<sup>2</sup>, Jia Ling Low<sup>2</sup>, Mohd Fyzal bin Bahrudin<sup>2</sup>, Syaza binti Izhar Hisham<sup>2</sup>, Liang Wei Wong<sup>2</sup>, Lisa Mohamed Nor<sup>1</sup>, Nurain Mohd Noorr<sup>1</sup>

<sup>1</sup>Clinical Research Centre, Hospital Putrajaya

<sup>2</sup>Endocrine Unit, Medical Department, Hospital Putrajaya

#### INTRODUCTION

Diabetic ketoacidosis (DKA) in pregnancy is an uncommon yet life-threatening emergency, with disproportionate risks to both mother and fetus. Pregnancy-specific physiological changes predispose patients to rapid metabolic

decompensation, often with atypical presentations. Despite this, local data remain limited. We describe the clinical profile, precipitating factors, and outcomes of DKA in pregnancy in a tertiary centre, with emphasis on potentially preventable triggers.

#### CASES

Nine pregnant patients with DKA were identified from a retrospective review of all cases admitted for DKA from 2002 to 2025. Mean age was  $31.67 \pm 5.20$  years; all were Malay. The majority had type 2 diabetes mellitus (55.6%), followed by type 1 diabetes (33.3%) and latent autoimmune diabetes in adults (11.1%). The mean period of amenorrhea was  $19.67 \pm 12.62$  weeks.

Infection was the leading precipitant (44.4%), with additional triggers including insulin omission (22.2%), hyperemesis gravidarum, preterm labor, steroid exposure, and perioperative fasting. Most diagnoses were made in the emergency department (55.6%).

Biochemical parameters reflected significant severity (mean bicarbonate  $7.89 \pm 2.98$  mmol/L; anion gap  $25.00 \pm 5.81$ ), with 88.9% classified as severe DKA. Intensive Care Unit (ICU) care was required in 77.8% of cases. The majority (77.8%) were admitted to the ICU unit, with a median time to resolution of  $13.00 \pm 12.00$  hours (interquartile range [IQR]), and the median hospital length of stay was  $7.00 \pm 5.00$  days (IQR).

Complications during treatment included hypokalemia (33.3%), acute kidney injury (22.2%), and hypoglycemia (11.1%). Rebound DKA occurred in one-third of patients. All patients were discharged clinically stable. Outcome data demonstrated pregnancy loss in three cases and one preterm birth.

#### CONCLUSION

DKA in pregnancy remains a severe and resource-intensive condition. This series highlights missed opportunities in prevention, with modifiable precipitants such as infection and insulin omission commonly identified. The high severity at presentation suggests delays in recognition. Early detection, optimized metabolic care, and targeted preventive strategies are crucial to improving maternal and fetal outcomes.

## EP\_A055

### THE PRICE OF POOR GLYCEMIC CONTROL BEFORE AND DURING PREGNANCY: GESTATIONAL HYPERTRIGLYCERIDEMIA

Pei Shin Lee<sup>1</sup>, Poh Shean Wong<sup>2</sup>, Fauzi Azizan Bin Hj Abdul Aziz<sup>1</sup>

<sup>1</sup>Hospital Tuanku Ampuan Najihah

<sup>2</sup>Hospital Tuanku Ja'afar

#### INTRODUCTION

Severe hypertriglyceridemia, though rare in pregnancy, is a clinically significant condition that poses substantial maternal and perinatal risks.

#### CASE

We present a case of a 42-year-old pregnant female with class I obesity and pre-existing type 2 diabetes mellitus, with a booking hemoglobin A1c 12.1%. Her poorly controlled diabetes was complicated by nephrotic syndrome, with a 24-hour urine protein 4.9 g/day. She also had bilateral diabetic retinopathies requiring multiple sessions of panretinal photocoagulation. Throughout the pregnancy, her triglycerides rose progressively, peaking at 30 mmol/L by 33 weeks. Investigations revealed normal thyroid function, urea 4.8 mmol/L, creatinine 66  $\mu$ mol/L, and albumin 26 g/dL. The patient was hospitalized at 33 weeks of gestation and started on an intravenous insulin infusion along with a very low-fat, low-carbohydrate diet prescribed by a dietitian. Pulmonary embolism was diagnosed during evaluation for maternal tachycardia, and subcutaneous enoxaparin was initiated. One week after admission in 35 weeks of gestation, the baby was delivered via emergency Caesarean section due to fetal distress. The baby was small for gestational age, with a birth weight of 1.9 kg, below the 10<sup>th</sup> percentile for gestational age, and required admission to the neonatal intensive care unit with oxygen support for pneumonia-related respiratory distress. Post-delivery, intravenous insulin infusion and dietary control were continued, reducing her triglyceride level to the lowest level of 8.3 mmol/L. Both mother and baby were discharged well. Lipid-lowering agents such as rosuvastatin and fenofibrate were started after breastfeeding stopped, aiming to normalize her triglyceride levels.

#### CONCLUSION

Hypertriglyceridemia in this patient was the result of uncontrolled diabetes mellitus with nephrotic-range proteinuria. Severe hypertriglyceridemia can cause acute pancreatitis and/or hyperviscosity syndrome, both of which are life-threatening to the mother and baby. Thus, rapid reduction of triglyceride levels is crucial. This case highlights the importance of achieving good diabetes control prior to pregnancy, with strict adherence to treatment and enhanced patient education.

## EP\_A056

### TOO LOW FROM A SELF-BLOW: DIAGNOSTIC AND THERAPEUTIC CHALLENGES IN A CASE OF HIRATA'S SYNDROME

Tharsini Sarvanandan<sup>1</sup>, Ying Guat Ooi<sup>1</sup>, Jun Kit Khoo<sup>1</sup>, Tricia Lopez<sup>1</sup>, Nicholas Ken Yoong Hee<sup>1</sup>, Shireene Vethakkan<sup>1</sup>, Lee-Ling Lim<sup>1</sup>, Jeyakantha Ratnasingam<sup>1</sup>, Carolyn Chee<sup>1</sup>, Pavai Sthaneshwar<sup>2</sup>, Quan Hziung Lim<sup>1</sup>

<sup>1</sup>Endocrine Unit, Department of Medicine, Faculty of Medicine, University Malaya

<sup>2</sup>Department of Pathology, Faculty of Medicine, University Malaya

#### INTRODUCTION

Non-diabetic hypoglycemia in older adults warrants careful evaluation across insulin-mediated and non-insulin-mediated causes. We present a challenging case of insulin autoimmune syndrome (IAS; Hirata's syndrome).

#### CASE

An 85-year-old female presented with severe hypoglycemia (capillary blood glucose [CBG] 1.8 mmol/L) with reduced consciousness, preceded by 2 months of recurrent dizziness relieved by food intake. Appetite and weight were stable. Past medical history included stage 3 chronic kidney disease and osteoporosis, but no diabetes. Medication review revealed a recent 2-week course of traditional supplement, long-term Neurobion<sup>®</sup>, but no agents with recognized hypoglycemic potential. Physical examination showed a moderately built elderly female with a body mass index of 24.3 kg/m<sup>2</sup> and no Cushingoid features.

Recurrent hypoglycemia (CBG nadir 1.5 mmol/L) occurred in both fasting and postprandial states, fulfilling Whipple's triad. Baseline investigations showed an estimated glomerular filtration rate of 42 mL/min/1.73 m<sup>2</sup>, AM cortisol of 700 nmol/L, and unremarkable liver and thyroid function tests. During a hypoglycemic episode (CBG 2.3 mmol/L), plasma insulin and C-peptide were inappropriately raised at 203.6 mU/L (reference interval [RI]: 3.0–25.0) and 33 ng/mL (RI: 0.9–7.1), respectively, confirming endogenous hyperinsulinemic hypoglycemia. Polyethylene glycol precipitation showed 21% insulin recovery, raising suspicion for an autoimmune cause. Elevated insulin autoantibodies (175 AU/mL; RI <20) confirmed IAS. Computed tomography of the abdomen and endoscopic ultrasound excluded a pancreatic neuro-endocrine tumor.

Nutritional management comprising frequent low glycemic index feeds and uncooked cornstarch was commenced. Diazoxide 100 mg TDS caused fluid overload and severe hyponatremia, while hypoglycemia persisted at lower

doses, necessitating discontinuation. Subcutaneous octreotide 100 mg QID was required to control hypoglycemia. Prednisolone 30 mg BD improved glycemic stability. Insulin autoantibodies titer remained 175 AU/mL at 2 weeks; reassessment was conducted at 4 weeks with consideration for biologics if persistent.

#### CONCLUSION

Endogenous hyperinsulinemic hypoglycemia, after excluding insulinoma, should raise suspicion for IAS. Management includes removing triggers, supportive care, and immunomodulatory therapy in severe cases.

## EP\_A057

### NOT JUST ANOTHER CASE OF TYPE 2 DIABETES IN AN ADOLESCENT

Aminuddin Ab Rahman<sup>1</sup>, Nga Xhi Wen Daniel<sup>2</sup>, Noor Hafis Md Tob<sup>1</sup>, Yong Siang Ng<sup>1</sup>, Norhaliza Mohd Ali<sup>1</sup>

<sup>1</sup>Endocrine Unit, Department of Internal Medicine, Hospital Sultanah Aminah

<sup>2</sup>Jeffrey Cheah School of Medicine and Health Sciences, Monash University Malaysia

#### INTRODUCTION

Cushing's disease (CD) in adolescents may present with subtle clinical features, resulting in a significant diagnostic challenge. We report a case of a young lady whose CD initially masqueraded as Type 2 diabetes (T2D), highlighting the difficulties in differentiating early hypercortisolism from T2D.

#### CASE

A 12-year-old female was incidentally diagnosed with diabetes during routine medical screening. Examination revealed an overweight female without the classical features of Cushing's syndrome. Due to the presence of acanthosis nigricans, a diagnosis of T2D was initially made. Her diabetes remained well-controlled with a single oral glucose-lowering drug.

The diagnostic challenge became apparent over time. She experienced delayed menarche at the age of 17, and a diagnosis of Cushing's syndrome was suspected when she subsequently developed hypertension and reduced bone mineral density. Biochemical evaluation was consistent with adrenocorticotropic hormone (ACTH)-dependent hypercortisolism, evidenced by the failure of serum cortisol suppression on low dose and overnight dexamethasone suppression tests. Her 24-hour urinary cortisol was elevated twofold, and plasma ACTH was elevated (17.8 pmol/L). MRI demonstrated a right-sided pituitary microadenoma (0.3 × 0.5 × 0.3 cm), and inferior petrosal sinus sampling confirmed the diagnosis of CD. She

underwent endoscopic transsphenoidal surgery 7 years later, which was complicated by panhypopituitarism and cranial diabetes insipidus. Postoperatively, CD was cured, with the resolution of her metabolic comorbidities.

#### CONCLUSION

Despite the increasing prevalence of T2D in adolescents, clinicians must recognize the diagnostic challenge of CD in this age group. Atypical manifestations in a presumed T2D patient should prompt consideration of Cushing's syndrome.

### EP\_A058

#### INSULIN-RECALCITRANT HYPERGLYCEMIA FOLLOWING CAPIVASERTIB THERAPY: A NOVEL CHALLENGE IN A NON-DIABETIC PATIENT

Jun Yang Tan<sup>1</sup> and Waye Hann Kang<sup>1</sup>

<sup>1</sup>Department of Medicine, M. Kandiah Faculty of Medicine and Health Sciences, Universiti Tunku Abdul Rahman

#### INTRODUCTION

Capivasertib is a selective oral AKT inhibitor approved for hormone receptor-positive, HER2-negative advanced breast cancer with AKT pathway mutations. As AKT is integral to insulin signaling, its inhibition predisposes patients to hyperglycemia. We report a case of severe capivasertib-induced hyperglycemia with profound insulin resistance in a non-diabetic patient.

#### CASE

A 56-year-old female with metastatic breast cancer (ER/PR-positive, HER2-negative, AKT1- and ESR1-mutated, TMB-high) presented with severe hyperglycemia following capivasertib initiation. She had no prior diabetes history, with a baseline hemoglobin A1c of 5.6%. Her first cycle (200 mg twice daily, 7 April 2025) was uncomplicated metabolically. The second cycle was escalated to 400 mg twice daily on 21 April 2025. By Day 3, blood glucose rose significantly. Premixed insulin 20 units failed to achieve glycemic control, necessitating intravenous insulin infusion. Despite escalation to 30 units per hour, euglycemia could not be achieved. Notably, there was no biochemical evidence of diabetic ketoacidosis or hyperosmolar hyperglycemic state, and the patient remained hemodynamically stable. No corticosteroids or other contributing medications were administered. Blood glucose normalized spontaneously approximately 36 hours after the last capivasertib dose, and all insulin was weaned and discontinued by 26 April 2025. She remained euglycemic without antidiabetic therapy thereafter. The patient and family opted for palliative care, and she passed away on 6 May 2025.

#### CONCLUSION

Capivasertib can precipitate severe, insulin-resistant hyperglycemia even in non-diabetic patients, without progression to overt hyperglycemic crisis. Spontaneous resolution upon drug cessation supports a direct drug-mediated mechanism via AKT-disrupted insulin signaling. Clinicians should monitor glucose closely during therapy and consider drug cessation in refractory cases. Further studies are warranted to guide optimal glycemic management.

### EP\_A059

#### THE VARIABLE NATURE OF BIOPSY-PROVEN VILDAGLIPTIN-INDUCED BULLOUS PEMPHIGOID IN AN ELDERLY PATIENT: A CASE SERIES

Mohd Fyzal Bahrudin<sup>1</sup>, Chin Voon Tong<sup>1</sup>, Raja Nurazni Raja Azwan<sup>1</sup>, Hazleen Zainal<sup>2</sup>, Zanariah Hussein<sup>1</sup>

<sup>1</sup>Institut Endokrin, Hospital Putrajaya

<sup>2</sup>Unit Dermatologi, Hospital Putrajaya

#### INTRODUCTION

Bullous pemphigoid (BP) is the most common autoimmune blistering disease. Drug-induced BP has been increasingly reported, with dipeptidyl peptidase-4 (DPP-4) inhibitors, particularly vildagliptin, emerging as a notable cause. The pathogenesis is thought to involve the disruption of immune tolerance and epitope spreading, leading to a broader autoimmune response against basement membrane antigens beyond the classic NC16A domain of BP180. This case series highlights the variable clinical spectrum and therapeutic challenges in vildagliptin-induced BP.

#### CASES

A 74-year-old male with type 2 diabetes mellitus (T2DM), hypertension, dyslipidemia, and a history of stroke presented with a 2-month history of recurrent, pruritic, tense bullae. He had been on vildagliptin for 36 months. Histopathology confirmed subepidermal blistering, and direct immunofluorescence demonstrated linear IgG/C3 deposition at the dermo-epidermal junction, with positive anti-BP180 antibodies, diagnosing BP. Discontinuation of vildagliptin and initiation of systemic corticosteroids resulted in significant clinical improvement, allowing a rapid prednisolone taper to 5 mg daily without new bullae formation.

A 62-year-old female with T2DM and dyslipidemia presented with bullous eruptions 3 months after initiating vildagliptin. Skin biopsy confirmed BP, revealing subepidermal blistering with eosinophils and linear C3/IgG deposition at the basement membrane zone. Vildagliptin

was discontinued. Despite initial management with systemic corticosteroids, the disease course was refractory. The patient experienced a flare upon steroid taper and had persistent blistering on prednisolone 20 mg daily, necessitating the addition of azathioprine as a steroid-sparing agent.

#### CONCLUSION

This case series illustrates the variable clinical course of vildagliptin-induced BP in which the therapeutic trajectories diverged significantly. Recognition of BP as a potential adverse effect of DPP-4 inhibitors is critical, and management should be individualized.

### EP\_A060

#### FLUCONAZOLE-INDUCED REFRACTORY HYPOGLYCEMIA IN GLICLAZIDE THERAPY: A PREVENTABLE INTERACTION

Abdul Rahman Ismail<sup>1</sup> and Nur Aini Eddy Warman<sup>1</sup>

<sup>1</sup>Department of Internal Medicine, Faculty of Medicine, Universiti Teknologi MARA

#### INTRODUCTION

Clinically important drug-drug interactions are a frequently overlooked cause of severe hypoglycemia in patients with type 2 diabetes mellitus (T2DM). Gliclazide is primarily metabolized via cytochrome P450 2C9 (CYP2C9), while fluconazole is a potent inhibitor of this enzyme.<sup>1,2</sup> Concomitant administrations markedly increase gliclazide plasma concentration and prolong its hypoglycemic effect, substantially increasing the risk of severe and prolonged hypoglycemia. In some cases of refractory sulfonylurea-induced hypoglycemia, octreotide may need to be considered early.

#### CASE

A 63-year-old Malay female with a 15-year history of T2DM on maximum-dose gliclazide (320 mg/day) presented with syncope and recurrent severe hypoglycemia 5 days after receiving a single oral dose of fluconazole 150 mg for a superficial fungal skin infection. Her other anti-diabetic medications included metformin 1 g twice daily and vildagliptin 50 mg once daily. Her blood pressure on presentation was 151/74 mmHg, and her glucose level was 2.8 mmol/L. Her presentation was compounded by community-acquired pneumonia and acute kidney injury (estimated glomerular filtration rate 52 mL/min/1.73 m<sup>2</sup>). Biochemical evaluation excluded adrenal insufficiency, with normal serum cortisol (1,098 µg/dL), serum sodium (141 mmol/L), and serum potassium (4.6 mmol/L). Thyroid and liver function tests were normal. Despite repeated

boluses of 50% dextrose and continuous infusion of 20% dextrose, recurrent hypoglycemia persisted for up to 48 hours after discontinuation of gliclazide, with glucose ranging from 1.7 to 5.1 mmol/L, reflecting prolonged sulfonylurea activity.

#### CONCLUSION

This case highlights a clinically significant yet preventable interaction between fluconazole and gliclazide, mediated through CYP2C9 inhibition, resulting in sustained hyperinsulinemic hypoglycemia. Gliclazide should be reduced or withheld prior to initiating fluconazole, and medication review should be performed at every consultation.

### EP\_A061

#### THE HIDDEN RISK OF A FIRST-LINE THERAPY: RENAL ABSCESS WITH SGLT2 INHIBITOR USE

Wei Ton Wong<sup>1</sup>, Khairi Syazwan Rashid<sup>1</sup>, Afiq Hazim Ab Rahim<sup>1</sup>

<sup>1</sup>Internal Medicine Unit, Hospital Besut

#### INTRODUCTION

Sodium-glucose cotransporter-2 (SGLT2) inhibitors are cornerstone therapies for heart failure and diabetes, offering proven cardiorenal benefits. However, expanded use necessitates vigilance regarding adverse effects, particularly genitourinary infections. While mild cystitis is common, serious upper urinary tract infections remain rare and potentially life-threatening. We describe a case of renal abscess presenting as recurrent urinary tract infections (UTI) following SGLT2 inhibitor initiation, emphasizing the need for clinical vigilance.

#### CASE

A 69-year-old male with a significant cardiovascular history, including heart failure with reduced ejection fraction (HFrEF), hypertrophic cardiomyopathy with an implantable cardioverter-defibrillator for non-sustained ventricular tachycardia, diabetes mellitus, hypertension, and hyperlipidemia, presented with a 1-week history of right flank pain, dysuria, urinary frequency, and fever. Initial labs confirmed infection: leukocytosis ( $22.6 \times 10^3/\mu\text{L}$ ), markedly elevated CRP (200 mg/L), and bacteriuria. He was diagnosed with a UTI and started on IV Cefuroxime. This marked his third UTI admission in 5 months, following discharge just 3 weeks prior for septic shock secondary to UTI, establishing a relapsing pattern. Subsequent urine and blood cultures were unremarkable. Medication review revealed Dapagliflozin had been initiated for HFrEF 8 months ago. Following clinical improvement from

each prior UTI episode, Dapagliflozin was consistently restarted. Despite an initial antibiotic response, symptoms recurred after discharge each time. The recurrent nature of his infections prompted a renal ultrasound revealing a large (5.3 × 7.5 × 7.4 cm), non-drainable, heterogeneously hypoechoic collection at the left kidney's mid-lower pole, diagnostic of an early renal abscess.

#### CONCLUSION

This report highlights renal abscess as a rare and severe complication of SGLT2 inhibitor therapy. It serves as a critical reminder that recurrent or relapsing UTIs in patients on these agents should prompt immediate investigation with renal imaging to rule out deep-seated pathology rather than simple cystitis. While these drugs offer proven cardiorenal benefits, their role in promoting urological infections necessitates a cautious approach.

## EP\_A062

### DIVERGENT CLINICAL MANIFESTATIONS OF SEVERE HYPERTRIGLYCERIDEMIA: A CASE SERIES

Shinye Eng<sup>1</sup> and Rabeah Md Zuki<sup>1</sup>

<sup>1</sup>Medical Department, Hospital Sultan Abdul Halim

#### INTRODUCTION

Severe hypertriglyceridemia increases the risk of pancreatitis and cardiovascular events. Therapies such as insulin, heparin, and plasmapheresis have been used. We present two cases of severe hypertriglyceridemia with distinct clinical presentations and management approaches.

#### CASES

We first describe a 26-year-old female with hypertriglyceridemia who presented with acute epigastric pain radiating to the back. She had a prior admission 3 years earlier for acute pancreatitis complicated by acute respiratory distress syndrome, during which severe hypertriglyceridemia was diagnosed (triglycerides 13.5 mmol/L) but was not treated at that time. She had no history of alcohol use, diabetes, or family history of hypercholesterolemia. On admission, she was hemodynamically stable. Serum triglycerides were markedly elevated at 32.3 mmol/L, total cholesterol was 8.6 mmol/L, and non-HDL cholesterol was 8.1 mmol/L. Serum amylase was elevated (1,606 U/L). Computed tomography (CT) abdomen demonstrated acute interstitial pancreatitis with peripancreatic fluid collection. She was managed conservatively with intravenous fluids and bowel rest. Triglycerides declined rapidly to 6.1 mmol/L by day 8 without intravenous insulin therapy. She was discharged on lipid-lowering therapy.

The second case involved a 57-year-old female with underlying hypertension, dyslipidemia, and poorly controlled diabetes mellitus who had not been on treatment for 3 years and presented with acute left-sided weakness. Brain CT confirmed a right cerebral infarction. Laboratory tests revealed triglycerides of 23.2 mmol/L, total cholesterol 9.9 mmol/L, non-HDL cholesterol 9.8 mmol/L, and hemoglobin A1c 11.2%. Intravenous insulin therapy was initiated, resulting in a progressive triglyceride reduction (Day 2: 18.7 mmol/L; Day 3: 13.1 mmol/L; Day 4: 11.0 mmol/L; Day 6: 6.9 mmol/L; Day 8: 4.2 mmol/L). Fenofibrate and high-intensity rosuvastatin were commenced, and glycemic control was optimized before discharge.

#### CONCLUSION

Severe hypertriglyceridemia may present variably, from acute pancreatitis to ischemic stroke. Individualized management led to a successful reduction of triglycerides. Early recognition, tailored therapy, and ongoing metabolic care are essential to reduce recurrence and long-term complications.

## EP\_A063

### EXPANDING THE CLINICAL SPECTRUM OF MULTIPLE AUTOIMMUNE SYNDROME TYPE 3: A CASE SERIES OF OVERLAPPING ENDOCRINE AND SYSTEMIC AUTOIMMUNE DISEASES IN YOUNG ADULTS

Yanne Pradwi Efendi<sup>1</sup>, Alexander Kam<sup>1,2</sup>, Dinda Aprilia<sup>2</sup>, Eva Decroli<sup>2</sup>, Syafril Syahbuddin<sup>2</sup>, Athari Fadhila<sup>1,2</sup>

<sup>1</sup>Internal Medicine Department, Medical Faculty, Universitas Andalas, Indonesia

<sup>2</sup>Metabolic Endocrinology and Diabetes Division, Internal Medicine Department, Medical Faculty, Universitas Andalas/ M. Djamil General Hospital, Indonesia

#### INTRODUCTION

Multiple autoimmune syndrome (MAS) type 3 is characterized by the coexistence of autoimmune thyroid disease with other organ-specific or systemic autoimmune disorders, excluding adrenal insufficiency. MAS represents a form of polyautoimmunity, in which shared immunological mechanisms contribute to clustering of multiple autoimmune diseases within a single individual. Recent studies suggest the clinical spectrum of MAS continues to expand, with increasing recognition of diverse autoimmune combinations across different organ systems. However, detailed clinical characterization of MAS type 3 involving overlapping endocrine and neuromuscular autoimmune diseases in young adults remains limited.

## CASES

We report four young adults (aged 21–37 years) with heterogeneous manifestations of MAS type 3 involving endocrine and systemic autoimmune diseases. Autoimmune thyroid disease was identified in three patients, all diagnosed with Graves' disease with suppressed thyroid-stimulating hormone, elevated free thyroxine, and positive thyrotropin receptor antibodies. Autoimmune diabetes was present in three patients, including latent autoimmune diabetes in adults (LADA) and type 1 diabetes mellitus, with variable glycemic control (hemoglobin A1c range 6.7–13.9%) and C-peptide levels ranging from preserved to markedly reduced. Myasthenia gravis was observed in three patients. Additional autoimmune conditions included systemic lupus erythematosus, systemic sclerosis, rheumatoid arthritis, and ulcerative colitis. Notably, rare combinations such as Graves' disease with LADA and myasthenia gravis, as well as coexistence with systemic autoimmune diseases, were identified. All patients received individualized multidisciplinary management. Clinical and biochemical improvement was observed in all cases, with stabilization of both endocrine and systemic autoimmune manifestations.

## CONCLUSION

This case series highlights the heterogeneous and expanding clinical spectrum of MAS type 3, including rare combinations of autoimmune endocrine and systemic diseases in young adults. Early recognition of autoimmune clustering and comprehensive screening are essential to optimize management and improve outcomes. These findings provide insights into autoimmune disease clustering and support the need for proactive multidisciplinary management strategies.

## EP\_A064

### A RARE DIAGNOSIS OF INSULIN AUTOIMMUNE SYNDROME CAUSING RECURRENT HYPOGLYCEMIA

Ju Vern Ew<sup>1</sup>, Jia En Chew<sup>1</sup>, Eunice Lau Yi Chwen<sup>2</sup>

<sup>1</sup>Department of Internal Medicine, Hospital Sibu

<sup>2</sup>Endocrine Unit, Department of Internal Medicine, Hospital Sibu

## INTRODUCTION

Insulin autoimmune syndrome (IAS), or Hirata syndrome, is characterized by hyperinsulinemic hypoglycemia resulting from the presence of high titers of insulin autoantibodies (IAAs) in the absence of exogenous insulin. We present a rare case of IAS.

## CASE

A 75-year-old female with underlying hypertension, dyslipidemia, and osteoporosis presented with symptoms suggestive of spontaneous hypoglycemia of 3 months duration. She was non-diabetic with no history of antidiabetic agents or exogenous insulin use. Notably, she had taken traditional medications 1 month prior to onset of symptoms.

Her fasting blood glucose was 2 mmol/L. Serum insulin was significantly elevated at >1,000 iui/mL and serum C peptide was 2,950 pmol/L, consistent with hyperinsulinemic hypoglycemia. Blood sulfonylurea level was not available. Her complete blood count and renal and liver function were normal. Thyroid function test was normal, and a short corticotropin stimulation test showed adequate cortisol response. Computed tomography (CT) pancreas, endoscopic ultrasound and PET-CT scan with Gallium-68 DOTATATE showed no evidence of insulinoma. Serum IAAs were raised at 175 IU/mL, which confirmed a diagnosis of IAS.

The patient was managed with dietary modifications and advised for frequent, small meals with low glycemic index, incorporating oral raw cornstarch. She was also started on oral diazoxide 100 mg twice daily (3 mg/kg/day) due to persistent hypoglycemia. She responded well to diazoxide with no more spontaneous hypoglycemia, however, developed fluid retention which was managed with oral diuretics. Subsequently, we managed to taper and stop the diazoxide after 18 months of treatment. Patient remains well with no further episodes of hypoglycemia.

## CONCLUSION

IAS may be triggered by medications or viral infections, occurs more frequently in people with autoimmune conditions, and shows genetic predisposition. However, as in our patient, IAS may be idiopathic, and the cause remains unknown. IAS is frequently self-limiting, and our patient experienced spontaneous remission with no further hypoglycemic episodes after discontinuation of treatment.

## EP\_A065

### A UNIQUE FAMILIAL CLUSTER OF TYPE 1 DIABETES: CLINICAL COURSE AND TREATMENT CONSIDERATION

**Kian Guan Goh<sup>1</sup>**

<sup>1</sup>KMI Kuantan Medical Centre

#### INTRODUCTION

Familial type 1 diabetes occurs up to 10% in large databases. This case series illustrated a family with three new onset type 1 diabetes diagnosed due to elevated blood sugar and positive diabetes autoantibody.

#### CASE

The index case was a 15-year-old male who presented with progressive osmotic symptoms over 1 month in 2024. He was admitted for severe diabetic ketoacidosis (DKA). Initial hemoglobin A1c (HbA1c) was 10.7%, and anti-GAD was >2,000 IU/mL. He was treated with basal bolus insulin.

The youngest brother was a 12-year-old male, presented with osmotic symptoms for 1 week in 2025. Random blood glucose elevated to 36 mmol/L. HbA1c was 8.9%. Anti-GAD was >2,000 IU/mL. He was admitted with impending DKA and discharged with basal bolus insulin.

The second brother was a 15-year-old male currently asymptomatic. Random blood glucose was normal. Anti-GAD was elevated at 1,307 IU/mL. Discussion regarding teplizumab to prevent further progression to type 1 diabetes was halted due to high cost and limited availability of the drug.

#### CONCLUSION

Active screening for siblings with diabetes autoantibodies among siblings with type 1 diabetes should be considered. Treatment with teplizumab for asymptomatic persons should be considered.

## EP\_A066

### INDIVIDUALIZING THERAPY WITH REPAGLINIDE: A SINGLE-CENTRE EXPERIENCE

**Ioanna Ting Yung Sim<sup>1,2</sup>, Florence Hui Sieng Tan<sup>1</sup>, Pei Lin Chan<sup>1</sup>, Ee Wen Loh<sup>1</sup>**

<sup>1</sup>Endocrine Unit, Sarawak General Hospital

<sup>2</sup>Universiti Malaysia Sarawak (UNIMAS)

#### INTRODUCTION

Repaglinide, a meglitinide analogue, has a rapid onset and short duration of action. It offers prandial glucose control while reducing hypoglycemia risk compared to sulfonylureas. We describe its use in our special cohorts of diabetic patients where repaglinide was prescribed to reduce hypoglycemia in vulnerable patients or to optimize glycemic control through pharmacotherapy intensification or deintensification.

#### CASES

Cohort A comprised 12 elderly patients with multiple comorbidities (mean age: 70.3 years; mean DM duration: 18.3 years) characterized by high glucose variability and problematic hypoglycemia. In seven patients, low-dose gliclazide was replaced with repaglinide with reduction in hypoglycemic episodes. One patient on low-dose pre-mixed insulin was successfully switched to preprandial repaglinide. Two patients on basal insulin were able to reduce their insulin requirements and stabilize their glucose levels. A younger patient with autonomic dysfunction had hypoglycemia while on insulin glulisine, while its omission led to severe hyperglycemia. Substituting glulisine with repaglinide resolved the glucose variability. Repaglinide effectively reduced hypoglycemic episodes while maintaining glycemic stability, with a mean hemoglobin A1c (HbA1c) reduction of 0.36% over 3–6 months.

Cohort B consisted of six younger patients (mean age: 35.3 years) with focus on optimizing HbA1c and improving treatment adherence. Two patients on basal-bolus regimes successfully transitioned off bolus insulin to repaglinide, significantly improving compliance. One patient on basal insulin was successfully transitioned to an all-oral regimen. Three patients on existing oral hypoglycemic agents were started on repaglinide to close the glycemic gap. Cohort B achieved a robust mean HbA1c reduction of 2.1% within 3–6 months.

## CONCLUSION

Repaglinide remains an important armamentarium in personalized diabetes management. Its pharmacokinetics and flexible dosing allow intensification of glycemic control while minimizing the risk of hypoglycemia. It also offers a viable strategy for selected patients struggling with complex insulin regime.

## EP\_A067

### SUBARACHNOID HEMORRHAGE: A RARE BUT DEVASTATING COMPLICATION OF DIABETIC KETOACIDOSIS

Hui Min Tan<sup>1</sup>, Mohd Irfan bin Moktar<sup>1</sup>, Hwee Ching Tee<sup>2</sup>

<sup>1</sup>Department of Medicine, Hospital Beaufort

<sup>2</sup>Department of Medicine, Hospital Queen Elizabeth II

## INTRODUCTION

Diabetic ketoacidosis (DKA) is a common complication of type 1 diabetes mellitus (T1DM). Neurological complications of DKA are rare in adults. We report a case of young lady with T1DM who presented with severe DKA and complicated with subarachnoid hemorrhage (SAH).

## CASE

A 19-year-old female was diagnosed with T1DM following an admission for DKA 2 months earlier. Her hemoglobin A1c was 17.2%, and autoimmune markers showed positive anti-glutamic acid decarboxylase (anti-GAD) antibodies (71 IU/mL) with negative anti-insulinoma-associated antigen 2 (anti-IA2) and islet cell antibodies. Her C-peptide level was low at 69 pmol/L. She was discharged with basal bolus insulin analogues, but she defaulted on her medications. She presented to the hospital 2 months later with a history of epigastric pain, vomiting, and breathlessness for 2 days, and was then found unconscious at home. There was no history of trauma. She was intubated for a poor Glasgow Coma Scale (E1V1M1). Blood results showed severe DKA with glucose 25 mmol/L, blood gas pH 6.572, bicarbonate 2.6 mmol/L, and ketone more than 8.8 mmol/L. She was started on insulin infusion and fluid resuscitation. DKA resolved after 24 hours. Computed tomography (CT) of the brain showed SAH in the right frontal and left frontotemporal regions. CT angiography of the brain reported no evidence of an intracranial aneurysm. She was extubated on day 4 of admission. Subsequent cerebral digital subtraction angiography was unremarkable. The patient achieved complete neurological recovery on follow-up.

## CONCLUSION

This case highlights that severe DKA may rarely be associated with spontaneous SAH, which increases morbidity and mortality. Proposed mechanisms include vascular injury, oxidative stress from severe ketoacidosis, and endothelial dysfunction related to inflammatory mediators. Clinicians should have a high suspicion and consider neuroimaging in DKA patients with unexplained reduced consciousness or atypical neurological findings.

## EP\_A068

### ASSOCIATION OF TESTOSTERONE WITH INSULIN RESISTANCE AND BETA-CELL FUNCTION IN TYPE 2 DIABETES MELLITUS

Khoirun Mukhsinin Putra<sup>1</sup>, Yulianto Kusnadi<sup>1</sup>, Ratna Maila Dewi<sup>1</sup>, Alwi Shahab<sup>1</sup>

<sup>1</sup>Division of Endocrinology, Metabolism, and Diabetes, Faculty of Medicine, Sriwijaya University/Dr. Mohammad Hoesin General Hospital, Indonesia

## INTRODUCTION

Insulin resistance and progressive beta-cell dysfunction are key components of the pathophysiology of type 2 diabetes mellitus (T2DM). The triglyceride-to-high-density lipoprotein cholesterol (TG/HDL) ratio has been widely used as a marker of insulin resistance. In addition, testosterone deficiency has been associated with adverse metabolic profiles and T2DM. However, the relationship between testosterone levels, insulin resistance, and beta-cell function in patients with T2DM remains incompletely understood.

## METHODOLOGY

A cross-sectional study was conducted involving 25 male patients with T2DM attending the diabetic clinic at Dr. Mohammad Hoesin General Hospital. Serum testosterone, C-peptide, TG, and HDL levels were obtained from routine clinical data. The TG/HDL ratio was calculated as an index of insulin resistance. Normality was assessed using the Shapiro-Wilk test, and due to the non-normal distribution of key variables, Spearman correlation analysis was applied.

## RESULTS

A strong inverse correlation was observed between testosterone levels and TG/HDL ratio ( $r = -0.860$ ,  $p < 0.001$ ), indicating that higher insulin resistance was associated with lower testosterone levels. In addition, TG/HDL ratio showed a strong negative correlation with C-peptide levels ( $r = -0.741$ ,  $p < 0.001$ ), suggesting reduced beta-cell function in the presence of increased insulin resistance.

## CONCLUSION

In patients with T2DM, increased insulin resistance is strongly associated with lower testosterone levels and reduced beta-cell function. These findings highlight the interaction between metabolic dysfunction and hormonal status in middle-aged and elderly patients with T2DM.

## EP\_A069

### WHOLE-BODY PHASE ANGLE AS A MARKER OF CELLULAR HEALTH IN A WORKPLACE LIFESTYLE INTERVENTION

**Mohd Nahar Azmi Bin Mohamed<sup>1,2</sup> and Nurul Zfarina Binti Mohd Zaid<sup>1</sup>**

<sup>1</sup>Wellness Unit, Faculty of Medicine, University of Malaya

<sup>2</sup>Department of Sports Medicine, Faculty of Medicine, University of Malaya

## INTRODUCTION

Phase angle (PhA) derived from bioelectrical impedance analysis reflects cellular integrity and has emerged as a potential marker of metabolic health. Its role in detecting early physiological changes during lifestyle intervention remains underexplored in workplace obesity programmes.

## METHODOLOGY

This longitudinal study included 30 adults with complete paired measurements enrolled in a 12-month workplace lifestyle programme. Body composition was assessed using multifrequency bioelectrical impedance analysis. Measurements included whole-body PhA, body cell mass (BCM), skeletal muscle index (SMI), and extracellular water to total body water ratio. Paired comparisons and correlation analyses were performed.

## RESULTS

Mean PhA increased modestly from  $5.59 \pm 0.70^\circ$  to  $5.67 \pm 0.69^\circ$ , although this did not reach statistical significance ( $p = 0.17$ ). Changes in PhA were not significantly associated with changes in BCM ( $r = -0.03$ ,  $p = 0.89$ ). However, baseline PhA demonstrated a moderate positive association with SMI ( $r \approx 0.51$ ,  $p < 0.01$ ), suggesting a link between cellular integrity and muscle status. Individual trajectories revealed heterogeneous responses despite minimal weight change.

## CONCLUSION

Whole-body phase angle provides insight into cellular health beyond conventional anthropometric measures. While short-term changes were modest, PhA may serve as a clinically useful adjunct for monitoring physiological response in obesity management programmes.

## EP\_A070

### INTEGRATING BODY COMPOSITION AND BIOCHEMICAL MARKERS FOR METABOLIC RISK STRATIFICATION IN LIFESTYLE INTERVENTION

**Mohd Nahar Azmi Bin Mohamed<sup>1,2</sup>, Nor Zurina Zainol<sup>1</sup>, Ng Ai Kah<sup>1,3</sup>**

<sup>1</sup>Wellness Unit, Faculty of Medicine, University of Malaya

<sup>2</sup>Department of Sports Medicine, Faculty of Medicine, University of Malaya

<sup>3</sup>Department of Social Preventive Medicine, Faculty of Medicine, Universiti Malaya, Malaysia

## INTRODUCTION

Obesity is a heterogeneous metabolic disease in which individuals with similar body weight may exhibit markedly different physiological risk profiles. Conventional monitoring using weight alone may fail to capture underlying metabolic and cellular changes during lifestyle intervention. Integrating body composition and biochemical markers may improve risk stratification in clinical practice.

## METHODOLOGY

A prospective observational analysis was conducted among participants enrolled in a structured lifestyle programme. Baseline and follow-up assessments included biochemical markers (fasting glucose, renal function, lipid profile, and liver enzymes) alongside body composition parameters derived from bioelectrical impedance analysis, including percent body fat, visceral fat area, skeletal muscle index (SMI), and phase angle (PhA). Changes over time and associations between metabolic and body composition variables were analyzed.

## RESULTS

Metabolic responses varied substantially despite similar anthropometric profiles. Renal function improved significantly, with increased estimated glomerular filtration rate (eGFR) observed over time ( $p = 0.01$ ), and was inversely associated with fasting glucose ( $r = -0.41$ ,  $p < 0.01$ ). Lipid abnormalities persisted, although reductions in low-density lipoprotein cholesterol were noted ( $p = 0.04$ ). Total cholesterol remained elevated and correlated positively with fasting glucose ( $r = 0.36$ ,  $p = 0.02$ ). Improvements in aspartate aminotransferase were observed ( $p = 0.03$ ), while other liver markers remained stable. Notably, body composition parameters, including PhA and SMI, demonstrated variability independent of weight change, reflecting heterogeneous physiological adaptation.

## CONCLUSION

Metabolic and physiological responses to lifestyle intervention are heterogeneous and not fully captured by changes in body weight alone. The integration of bioimpedance-derived parameters with biochemical markers provides a more comprehensive approach to metabolic risk stratification and may support more personalized clinical management in obesity care.

## EP\_A071

### BEYOND BODY WEIGHT: BODY COMPOSITION AND CELLULAR HEALTH IN A WORKPLACE OBESITY INTERVENTION PROGRAMME

Mohd Nahar Azmi Bin Mohamed<sup>1,2</sup> and Nurul Zfarina Binti Mohd Zaid<sup>1</sup>

<sup>1</sup>Wellness Unit, Faculty of Medicine, University of Malaya

<sup>2</sup>Department of Sports Medicine, Faculty of Medicine, University of Malaya

## INTRODUCTION

Obesity is a chronic disease characterized by complex alterations in body composition and metabolic health. Traditional reliance on body weight may overlook important physiological adaptations during lifestyle intervention.

## METHODOLOGY

A cohort of 99 participants at programme entry underwent body composition assessment using bioelectrical impedance analysis. Parameters included percent body fat (PBF), visceral fat area (VFA), skeletal muscle index (SMI), and phase angle (PhA). Correlation analyses were performed to explore relationships between adiposity, muscle mass, and cellular health.

## RESULTS

Participants demonstrated elevated adiposity (PBF  $38.9 \pm 8.9\%$ ; VFA  $142.9 \pm 56.1 \text{ cm}^2$ ). PhA was inversely associated with VFA ( $r \approx -0.23$ ,  $p < 0.05$ ) and positively associated with SMI ( $r \approx 0.49$ ,  $p < 0.001$ ). Notably, a subset of overweight individuals exhibited relatively preserved PhA, indicating heterogeneity in metabolic health despite similar adiposity levels.

## CONCLUSION

Body composition and PhA provide complementary insights into metabolic health beyond body weight. These findings support the role of bioimpedance-derived parameters in identifying metabolic heterogeneity and guiding personalized obesity management.

## EP\_A072

### BLOOD PRESSURE IMPROVES AFTER BARIATRIC SURGERY ACROSS PATIENT SUBGROUPS

Liyana Ahmad Zamri<sup>1</sup>, Nur Azlin Zainal Abidin<sup>1</sup>, Farah Huda Mohkiar<sup>2</sup>, You Zhuan Tan<sup>2</sup>, Fazliana Mansor<sup>1</sup>, Yue Tsen Poh<sup>3,4,5</sup>, Shu Yu Lim<sup>3,4,5</sup>, Gee Tikfu<sup>3,4,5</sup>

<sup>1</sup>Endocrine and Metabolic Unit, Nutrition, Metabolism and Cardiovascular Research Centre, Institute for Medical Research, Ministry of Health

<sup>2</sup>Cardiovascular Unit, Nutrition, Metabolism and Cardiovascular Research Centre, Institute for Medical Research, Ministry of Health

<sup>3</sup>iHeal Medical Centre

<sup>4</sup>Sunway Medical Centre

<sup>5</sup>Sunway Velocity Medical Centre

## INTRODUCTION

Hypertension is common in obesity and increases cardiovascular risk. Bariatric surgery improves metabolic health, but subgroup differences in blood pressure response remain unclear. This study examined 1-year changes in systolic blood pressure (SBP) and diastolic blood pressure (DBP) after bariatric surgery across sex, age group, and diabetes status.

## METHODOLOGY

This study included 32 obese adults undergoing bariatric surgery, with blood pressure measured at baseline, 6 and 12 months. Generalized estimating equation models were used to evaluate changes in SBP and DBP over time, adjusting for age, sex, surgery type, diabetes category, baseline body mass index, antihypertensive medication use, and baseline blood pressure. Interaction terms were tested to assess differences in blood pressure trajectories across subgroups.

## RESULTS

Participants were predominantly female (67.4%), with a mean age of  $36.9 \pm 6.2$  years and a mean body mass index of  $40.7 \pm 8.8 \text{ kg/m}^2$ . Hypertension and diabetes were present in 40.6 and 31.3% of participants, respectively. There was a significant time effect for both SBP ( $p < 0.001$ ) and DBP ( $p = 0.004$ ). At 12 months post-surgery, mean SBP decreased by 15 mmHg and DBP by 7.9 mmHg compared with baseline (both  $p < 0.001$ ). No significant interactions were observed between time and sex, diabetes category, or age category, indicating that blood pressure improvements were comparable across subgroups.

## CONCLUSION

Bariatric surgery was associated with clinically meaningful reductions in both SBP and DBP, with similar improvement patterns observed across demographic and metabolic subgroups. These findings support the effectiveness of bariatric surgery as a strategy for blood pressure reduction and cardiovascular risk management in patients with obesity.

## EP\_A073

### A SINGLE-CENTRE MALAYSIAN COHORT STUDY ON PREDICTORS OF GLYCEMIC IMPROVEMENT 12 MONTHS AFTER BARIATRIC SURGERY

Anis Amalina Mohd Nadzri<sup>1</sup>, Mohd Shazli Draman<sup>1</sup>,  
Haron Ahmad<sup>2</sup>

<sup>1</sup>KPJ Healthcare University

<sup>2</sup>KPJ Damansara Specialist Hospital

#### INTRODUCTION

Bariatric surgery is an established intervention for obesity and its metabolic complications, including diabetes mellitus. However, most studies are from Western populations with limited data in Malaysia. This study evaluated glycemic status improvements and identified predictors of hemoglobin A1c (HbA1c) reduction at 12 months following bariatric surgery to contribute regional data to Southeast Asia.

#### METHODOLOGY

This retrospective analysis included 110 patients who underwent bariatric surgery between 2015 and 2025. Pre- and post-operative parameters, including HbA1c, body mass index (BMI), and lipid profiles, were collected at 1, 3, 6, 9, and 12 months and evaluated as potential predictors of glycemic status improvement at 12 months. Univariate analysis followed by stepwise multivariate linear regression was performed to identify predictors of HbA1c improvement at 12 months. Regression coefficients (B), 95% confidence intervals, and *p*-values were reported.

#### RESULTS

The mean age was 40.5 years with a mean baseline BMI of 43.49 kg/m<sup>2</sup>; 58% were female. At baseline, 60.9% (*n* = 67) had diabetes, 30.9% (*n* = 34) prediabetes, and 8.2% (*n* = 9) normal HbA1c. In univariate analysis, baseline HbA1c (*B* = 0.579, *p* < 0.001), age (*B* = -0.051, *p* = 0.034), and sex (*B* = 1.123, *p* = 0.044) were significantly associated with HbA1c change. In multivariate analysis, the final model identified baseline HbA1c, BMI difference at 12 months, and TG difference at 12 months as independent predictors of HbA1c

change. Baseline HbA1c was the strongest predictor (*B* = 0.857, *p* < 0.001) indicating that higher baseline HbA1c was associated with greater change over time. BMI difference at 12 months was also significantly associated with HbA1c change (*B* = 0.046, *p* = 0.016), indicating that greater weight loss contributed to improved glycemic control. Similarly, TG difference at 12 months was a significant predictor (*B* = 0.337, *p* = 0.023). The model explained 86.8% of the variation in HbA1c change (adjusted *R*<sup>2</sup> = 0.868).

## CONCLUSION

Bariatric surgery resulted in significant weight loss and improvement in glycemic status at 12 months, with baseline HbA1c, BMI differences, and TG reductions emerging as key predictors of glycemic improvement in a Malaysian cohort.

## EP\_A074

### REAL-WORLD EFFECTIVENESS OF SEMAGLUTIDE IN ADULTS WITH OBESITY AND TYPE 2 DIABETES IN A MALAYSIAN DISTRICT HOSPITAL

Shaleela Mohd Esha<sup>1</sup>, Hazwani Aziz<sup>1</sup>, Elliyyin Katiman<sup>1</sup>

<sup>1</sup>Hospital Tengku Ampuan Norashikin, Kajang

#### INTRODUCTION

Semaglutide has shown clinically meaningful effects on weight and glycemic control in randomized trials, but real-world evidence from Malaysian public healthcare settings remains limited. Local data are particularly relevant because access to glucagon-like peptide-1 receptor agonists may be influenced by cost and availability. We evaluated the real-world effectiveness of once-weekly semaglutide in adults with obesity and type 2 diabetes mellitus (T2DM) managed in routine clinical practice at a Malaysian district hospital.

#### METHODOLOGY

We conducted a retrospective observational study of adults with obesity and T2DM treated with once-weekly semaglutide at a single district hospital. Demographic, anthropometric, metabolic, and cardiovascular parameters were collected at baseline and follow-up. The primary outcomes were percentage weight change and the proportions of patients achieving at least 5% and at least 10% weight loss. Secondary outcomes included changes in body mass index (BMI), glycated hemoglobin A1c (HbA1c), blood pressure, lipid parameters, and insulin requirements. Paired analyses were performed to compare pre-treatment and post-treatment values.

## RESULTS

Eight patients were included (mean age 45 years; 63% women; 88% Malay). All had T2DM and hypertension, while most had dyslipidemia. Mean baseline weight was  $116.0 \pm 22.7$  kg, and mean BMI was  $43.5 \pm 9.0$  kg/m<sup>2</sup>. After a mean treatment duration of 23 months, mean weight decreased to  $102.9 \pm 23.8$  kg, representing a mean reduction of 13.1 kg or 11.5%. Six patients (75%) achieved at least 5% weight loss, and four (50%) achieved at least 10% weight loss. Mean BMI decreased to  $38.4 \pm 8.4$  kg/m<sup>2</sup>. Mean HbA1c improved from  $8.9 \pm 1.9\%$  to  $6.3 \pm 0.9\%$ . Systolic and diastolic blood pressure declined from  $153 \pm 22$  to  $134 \pm 17$  mmHg and from  $91 \pm 17$  to  $82 \pm 10$  mmHg, respectively. Total cholesterol, low-density lipoprotein cholesterol, and triglycerides also improved. Among insulin-treated patients, all discontinued insulin during follow-up. No treatment discontinuations due to adverse effects were recorded.

## CONCLUSION

In this small real-world cohort, semaglutide was associated with meaningful weight loss, improved glycemic control, favorable cardiometabolic changes, and successful insulin deintensification. These findings support its use in routine obesity-diabetes care, although larger prospective studies are needed.

## EP\_A075

### EFFECTIVENESS OF GLP-1 RECEPTOR AGONISTS ON WEIGHT LOSS IN MALAYSIAN PATIENTS WITH TYPE 2 DIABETES

Noor Hafizah Ab Hamid<sup>1</sup>, Mohammad Zulkarnain Bidin<sup>2</sup>, Ooi Chuan Ng<sup>1,2</sup>

<sup>1</sup>Department of Internal Medicine, Faculty of Medicine and Health Sciences, Universiti Putra Malaysia

<sup>2</sup>Department of Internal Medicine, Hospital Sultan Abdul Aziz Shah, Universiti Putra Malaysia

## INTRODUCTION

Glucagon-like peptide-1 receptor agonists (GLP-1 RAs) induce clinically meaningful weight reduction in patients with type 2 diabetes mellitus (T2DM), but real-world data in Southeast Asian populations are limited. This study evaluated the effectiveness of GLP-1 RAs in achieving clinically significant weight loss in Malaysian patients with obesity and T2DM.

## METHODOLOGY

A retrospective cohort study was conducted among adults with T2DM and obesity attending the Endocrinology Clinic at Hospital Sultan Abdul Aziz Shah between January 2023 and December 2024. Patients receiving GLP-1 RAs (semaglutide or liraglutide) were compared with those on standard care. Anthropometric outcomes were assessed over 6–12 months, with weight loss thresholds of  $\geq 3\%$ ,  $\geq 5\%$ , and  $\geq 10\%$ . Between-group comparisons used Fisher's exact test, and odds ratios (OR) were calculated.

## RESULTS

Eighty-five patients were included (GLP-1,  $n = 47$ ; control,  $n = 38$ ). The GLP-1 group achieved significantly higher rates of any weight loss (70.0% vs 41.2%; OR = 3.33,  $p = 0.019$ ) and  $\geq 3\%$  weight loss (42.5% vs 14.7%; OR = 4.29,  $p = 0.011$ ). Number needed to treat was 3–4 patients. Proportions achieving  $\geq 5\%$  and  $\geq 10\%$  weight loss were higher in the GLP-1 group but did not reach statistical significance.

## CONCLUSION

GLP-1 RA therapy significantly improves the likelihood of clinically meaningful weight loss in Malaysian patients with obesity and T2DM. These findings support the integration of GLP-1 RAs into routine obesity management strategies in Southeast Asia.

## EP\_A076

### **DETERMINANTS OF POLYCYSTIC OVARIAN SYNDROME AMONG ADOLESCENTS WITH OVERWEIGHT AND OBESITY: A CASE-CONTROL STUDY PROTOCOL**

Shazana Rifham Abdullah<sup>1</sup>, Nur Zati Iwani Ahmad Kamil<sup>1</sup>, Siti Sarah Hamzah<sup>1</sup>, Norhashimah Abu Seman<sup>1</sup>, Farah Huda Mohkiar<sup>1</sup>, Nur Azlin Zainal Abidin<sup>1</sup>, Ezarul Faradianna Lokman<sup>1</sup>, Azahadi Omar<sup>2</sup>, Liyana Ahmad Zamri<sup>1</sup>, Fatin Saparuddin<sup>1</sup>, Syarifah Nortasya Sayed Muhamad Kamarudin<sup>1</sup>, Puteri Sofia Nadira Megat Kamaruddin<sup>1</sup>, B. Vimala A/P R.M.T. Balasubramaniam<sup>1</sup>, Fazliana Mansor<sup>1</sup>, Nur Azurah Abdul Ghani<sup>3</sup>, Abqariyah Yahya<sup>4</sup>, Rahima Dahlan @ Mohd Shafie<sup>5</sup>, Ahmad Ali Zainuddin<sup>6</sup>, Kimberly Yuin Y'ng Wong<sup>6</sup>, Janet Yeow Hua Hong<sup>7</sup>, Nik Sumayyah Nik Mhd Nor<sup>8</sup>, Mohd Fairulnizal Md Noh<sup>8</sup>, Muhammad Yazid Jalaludin<sup>9</sup>

<sup>1</sup>Nutrition, Metabolism and Cardiovascular Research Centre, Institute for Medical Research, National Institutes of Health, Ministry of Health Malaysia

<sup>2</sup>Special Resource Centre, Institute for Medical Research, National Institutes of Health, Ministry of Health Malaysia

<sup>3</sup>Department of Obstetrics and Gynaecology, Hospital Canselor Tuanku Muhriz, Universiti Kebangsaan Malaysia

<sup>4</sup>Department of Social and Preventive Medicine, Faculty of Medicine, Universiti Malaya

<sup>5</sup>Psychiatry Department, Faculty of Medicine and Health, Universiti Putra Malaysia

<sup>6</sup>Nutrition Epidemiology Research Centre, Institute of Public Health, National Institutes of Health, Ministry of Health Malaysia

<sup>7</sup>Paediatric Department, Hospital Putrajaya

<sup>8</sup>Hospital Tuanku Azizah

<sup>9</sup>Department of Paediatrics, Faculty of Medicine, Universiti Malaya

#### **INTRODUCTION**

Polycystic ovarian syndrome (PCOS) is a complex endocrine disorder that significantly affects adolescent girls, particularly those with overweight or obesity. However, data examining the determinants and metabolic profiles of PCOS among adolescents with overweight and obesity remain limited, especially in Malaysia. This protocol describes a case-control study investigating the cardiometabolic, dietary, and psychosocial determinants of PCOS among adolescents with overweight and obesity.

#### **METHODOLOGY**

This study is designed as a case-control study involving adolescent girls aged 13–16 years with a body mass index z-score >+1 standard deviation. Cases are defined

as adolescent girls with a confirmed diagnosis of PCOS based on the recommendations of the 2017 International Consortium of Paediatric Endocrinology (ICPE), while controls are those who do not meet the diagnostic criteria for PCOS. A total sample size of 440 participants is required. Participants will be recruited from 22 secondary schools selected from a list of schools in Kuala Lumpur. Data on sociodemographic characteristics, psychosocial health, physical activity, and dietary intake will be collected using structured questionnaires. Blood samples will be obtained and analyzed for diagnostic testing (free testosterone), exclusion tests (thyroid-stimulating hormone, follicle-stimulating hormone, luteinizing hormone, estradiol, prolactin, and dehydroepiandrosterone sulfate), and biochemical parameters (liver function tests, lipid profile, hemoglobin A1c, fasting glucose, fasting insulin, and inflammatory markers).

#### **RESULTS**

The study is expected to generate comprehensive data on the cardiometabolic, dietary, and psychosocial determinants of PCOS among adolescents with overweight and obesity. The findings will inform early screening strategies and targeted interventions aimed at reducing long-term reproductive and cardiometabolic complications.

#### **CONCLUSION**

This protocol outlines a structured approach to investigating PCOS in adolescence and addresses current gaps in early identification and risk stratification among high-risk populations.

## EP\_A077

### **BASELINE PHYSICAL ACTIVITY ENHANCES GLP-1 RECEPTOR AGONIST WEIGHT LOSS IN OBESE MALAYSIAN PATIENTS WITH T2DM**

Noor Hafizah Ab Hamid<sup>1</sup>, Mohammad Zulkarnain Bidin<sup>2</sup>, Ooi Chuan Ng<sup>1,2</sup>

<sup>1</sup>Department of Internal Medicine, Faculty of Medicine and Health Sciences, Universiti Putra Malaysia

<sup>2</sup>Department of Internal Medicine, Hospital Sultan Abdul Aziz Shah, Universiti Putra Malaysia

#### **INTRODUCTION**

While Glucagon-like peptide-1 receptor agonists (GLP-1 RAs) are effective for weight reduction in type 2 diabetes mellitus (T2DM), interindividual variability exists. Lifestyle factors, particularly baseline physical activity, may modify weight loss outcomes. This study examined whether baseline activity influences GLP-1 RA efficacy in Malaysian patients.

## METHODOLOGY

A retrospective cohort of adults with obesity and T2DM receiving GLP-1 RAs (semaglutide or liraglutide) from January 2023 to December 2024 was analyzed. Baseline physical activity was classified as active or inactive. Primary outcomes were achievement of  $\geq 3$  and  $\geq 5\%$  weight loss over 6–12 months. Associations were assessed using Fisher's exact test and logistic regression.

## RESULTS

Among GLP-1-treated patients, those reporting baseline physical activity were more likely to achieve  $\geq 3\%$  weight loss and demonstrated trends toward higher,  $\geq 5\%$ , weight loss. Logistic regression suggested baseline activity increased the odds of clinically meaningful weight reduction, though statistical significance was limited by sample size.

## CONCLUSION

Baseline physical activity may enhance GLP-1 receptor agonist-mediated weight loss in obese patients with T2DM. Integrating lifestyle interventions with pharmacotherapy may optimize treatment outcomes. Larger prospective studies are warranted to confirm these findings.

## EP\_A078

### GRAY-MARKET PEPTIDES, GRAVE CONSEQUENCES: SADDLE PULMONARY EMBOLISM AND DIABETIC KETOACIDOSIS FROM UNSUPERVISED RETATRUTIDE, AOD-9604, AND TESAMORELIN

Wan Zulhafizaini Bin Wan Jusoh<sup>1</sup> and Md Syazwan Bin Md Amin<sup>2</sup>

<sup>1</sup>Department of Internal Medicine, Hospital Sultan Aziz Shah, Universiti Putra Malaysia (UPM)

<sup>2</sup>Endocrine Unit, Hospital Putrajaya

## INTRODUCTION

The growing popularity of glucagon-like peptide-1 receptor agonists (GLP-1 RAs) for weight management has inadvertently perpetuated demand for unregulated experimental peptides procured through gray markets. Retatrutide, a novel triple GLP-1/glucose-dependent insulinotropic polypeptide (GIP)/glucagon receptor agonist undergoing Phase III trials; AOD -9604, an abandoned synthetic human growth hormone fragment; and tesamorelin, a synthetic GHRH analogue, are increasingly self-administered without medical supervision. Their combined metabolic and thromboembolic risks remain unknown and unreported.

## CASE

A 50-year-old Malaysian female with morbid obesity and poorly controlled type 2 diabetes mellitus (hemoglobin A1c 13%) presented with acute dyspnea, chest tightness, syncope, and cardiogenic shock. Three weeks prior, she had self-initiated subcutaneous retatrutide, AOD-9604, and tesamorelin procured through unregulated online platforms, achieving rapid weight loss of 10 kg. Despite markedly reduced oral intake from GLP-1-mediated gastrointestinal side effects, she continued her prescribed high-dose insulin regimen and sodium-glucose cotransporter-2 (SGLT2) inhibitor without dose adjustment. She developed concurrent diabetic ketoacidosis, confirmed biochemically, alongside massive saddle pulmonary embolism with right ventricular strain on echocardiography and computed tomography pulmonary angiography. She was successfully treated with systemic thrombolysis using alteplase, guideline-directed diabetic ketoacidosis management including fixed-rate insulin infusion and fluid resuscitation, and anticoagulation. The SGLT2 inhibitor was withheld throughout admission. She was discharged on rivaroxaban with counseling to cease all unregulated compounds. All three agents were submitted to the National Pharmaceutical Regulatory Authority/Malaysian Adverse Drug Reactions Advisory Committee for adverse drug reaction reporting.

## CONCLUSION

To our knowledge, this is the first reported case of concurrent massive pulmonary embolism and diabetic ketoacidosis precipitated by unsupervised gray-market retatrutide, AOD-9604, and tesamorelin. Clinicians should enquire about unregistered supplement use, counsel insulin-dependent patients on sick-day rules when appetite-suppressing agents are initiated, and report adverse events to pharmacovigilance authorities.

## EP\_A079

### POST-BARIATRIC METABOLIC EMERGENCY: A CASE OF DKA IN A NON-INSULIN-DEPENDENT PATIENT

Izzah Zafirah Jusoh<sup>1</sup>, M.K. Mohd Firdaus<sup>1</sup>, W.H. Wan Mohd Hafez<sup>1</sup>, M.A. Masliza Hanuni<sup>1</sup>

<sup>1</sup>Endocrinology Unit, Medical Department, Hospital Sultanah Nur Zahirah

## INTRODUCTION

Bariatric surgery is an effective treatment for morbid obesity and metabolic syndrome, including type 2 diabetes mellitus. However, metabolic complications such as diabetic and starvation ketoacidosis may occur in the perioperative period, particularly in patients with reduced oral intake, rapid weight loss, and altered insulin requirements.

## CASE

A 37-year-old male with type 2 diabetes mellitus, hypertension, dyslipidemia, and morbid obesity (body mass index 60 kg/m<sup>2</sup>) was referred for bariatric surgery. Preoperatively, he was initiated on subcutaneous semaglutide 1 mg weekly for weight optimization, resulting in weight loss from 178 to 127 kg. His hemoglobin A1c was 9.5%. He subsequently underwent laparoscopic proximal jejunal bypass sleeve gastrectomy on 5 November 2025.

Two weeks postoperatively, he reported lethargy and was clinically found to be dehydrated, following poor tolerance of nourishing fluids and inadequate caloric intake. Capillary blood glucose was 7.6 mmol/L. Investigations revealed metabolic acidosis with markedly elevated serum ketones (4.9 mmol/L), consistent with ketoacidosis. He was commenced on an intravenous insulin infusion and aggressive IV fluid resuscitation. Attempts to discontinue insulin infusion resulted in recurrent ketoacidosis, attributed to poor tolerance of nourishing fluids. Following multidisciplinary input involving endocrinologists, a diabetes educator, and a dietitian, he was able to tolerate enteral nutritional supplementation. Insulin infusion was successfully discontinued, and he was discharged on a basal bolus subcutaneous insulin regimen.

## CONCLUSION

Ketoacidosis following bariatric surgery is an underrecognized complication and may occur even in patients with type 2 diabetes mellitus and relatively normal blood glucose levels. Contributing factors included prolonged caloric deprivation, rapid weight loss, post-surgical catabolic state, and relative insulin deficiency. Recently used glucagon-like peptide-1 receptor agonist may have further suppressed appetite, compounding postoperative nutritional intolerance. The involvement of a multidisciplinary team, including endocrinologists, a dietitian, diabetic educators, and surgical teams, is essential to optimize outcomes and prevent severe complications.

## EP\_A080

### STARVATION KETOACIDOSIS SECONDARY TO RETATRUTIDE-INDUCED GASTROPARESIS: A CASE REPORT

Shinye Eng<sup>1</sup> and Rabeah Md Zuki<sup>1</sup>

<sup>1</sup>Medical Department, Hospital Sultan Abdul Halim

## INTRODUCTION

Retatrutide is an investigational triple agonist targeting glucagon-like peptide-1, glucose-dependent insulinotropic polypeptide, and glucagon receptors. Early clinical trials

have demonstrated promising weight loss effects. Gastrointestinal side effects are common and dose-dependent; however, severe complications such as gastroparesis leading to starvation ketoacidosis are rarely reported. Increasing public interest in emerging anti-obesity pharmacotherapies has led to unsupervised access to investigational medications through unregulated channels. We report a case of starvation ketoacidosis associated with retatrutide-induced gastroparesis following unsupervised use of medication obtained from unregulated sources.

## CASE

A 39-year-old female healthcare worker with prediabetes (hemoglobin A1c 5.7%), class I obesity (body mass index 31.2 kg/m<sup>2</sup>), and endometriosis presented with persistent vomiting and diarrhea. She reported using retatrutide for weight loss, initially obtained from an informal source, although the authenticity and origin of the medication could not be verified. She self-titrated retatrutide over 7 weeks, escalating from 1 mg twice weekly to 6 mg weekly, with only mild nausea. Subsequently, she purchased the medication from another unverified online source. Following this change, she developed worsening nausea at the 6 mg weekly dose, prompting a dose reduction to 5 mg weekly. Two days after the most recent dose, she developed intractable vomiting and diarrhea. On presentation, she was clinically dehydrated. Venous blood gas revealed metabolic acidosis (pH 7.33, bicarbonate 18.8 mmol/L) with elevated serum ketones (4.5 mmol/L) and normal lactate (1.2 mmol/L). Blood glucose was 4.5 mmol/L, and serum amylase was normal. She was treated with intravenous fluids, fixed-rate insulin infusion, and antiemetics. Ketoacidosis resolved by day 3, with improvement of gastrointestinal symptoms by day 5.

## CONCLUSION

This case highlights a serious complication associated with retatrutide and underscores the risks of unsupervised use of investigational weight-loss therapies obtained from unregulated sources. It also emphasizes pharmacovigilance as emerging antiobesity therapies become widely used. Careful dose titration, close clinical monitoring, and use within regulated medical channels are essential for patient safety.

## EP\_A081

### ADRENAL SUPPRESSION DURING BIOLOGIC-FACILITATED STEROID TAPERING IN SEVERE ASTHMA: A REAL-WORLD TERTIARY-CENTRE EXPERIENCE

Sean Yi Xian Tay<sup>1</sup>, Travers Brian Ramadass<sup>1</sup>, Sakshi Malik<sup>1</sup>, Shoaib Faruqi<sup>1</sup>

<sup>1</sup>Hull University Teaching Hospitals Trust

#### INTRODUCTION

A significant proportion of severe asthma patients require oral corticosteroids (OCS) to maintain symptom control. Prolonged OCS predisposes patients to hypothalamic-pituitary-adrenal axis suppression which can be life-threatening. Biologic therapies are effective steroid-sparing options suitable for select severe asthma patients. We evaluated steroid tapering outcomes and adrenal function during biologic therapy in a tertiary severe asthma clinic.

#### METHODOLOGY

We retrospectively analyzed our severe asthma clinic cohort. Patients were included if they attended the clinic in 2025, had severe asthma requiring  $\geq 5$  mg maintenance prednisolone daily (or equivalent), initiated biologic therapy, and underwent adrenal function assessment with morning serum cortisol and/or Short Synacthen Test (SST) during steroid tapering between 2024 and 2025. Patients who were still weaning maintenance steroids were excluded.

#### RESULTS

A total of 43 patients were included. Median age was 66 years (interquartile range [IQR] 60–74), and 65% were male. Mepolizumab was the most used (17 patients), followed by benralizumab (15), tezepelumab (6), dupilumab (4), and omalizumab (1). Median baseline prednisolone dose was 10 mg (IQR 5–10). Median lowest dose achieved was 3 mg (IQR 0–3), sustained for at least 4 weeks in 90.7% of patients. Median reduction in prednisolone dose was 5 mg (IQR 5–7.25). In all, 42% of patients successfully discontinued maintenance steroids. Adrenal function was assessed using morning serum cortisol ( $n = 37$ ) and/or SST ( $n = 28$ ). Evidence of adrenal insufficiency was identified in 19 patients (44%), including 15 patients with failed SST and four with low morning cortisol suggestive of adrenal suppression. Morning serum cortisol was indeterminate in four patients. A total of 17 patients were referred to endocrinology. During steroid tapering, 11 asthma-related hospital admissions and eight emergency department presentations occurred, involving 10 patients.

#### CONCLUSION

Biologics facilitate the reduction of the OCS burden in severe asthma. Tertiary adrenal suppression is common during steroid tapering and requires prompt biochemical assessment and endocrinology referral. Structured monitoring of adrenal function is essential during biologic-facilitated steroid tapering in routine clinical practice.

## EP\_A082

### METASTATIC EXTRA-OVARIAN STEROID CELL TUMOR PRESENTING WITH HYPERANDROGENISM AND TRANSAMINITIS POST OOPHORECTOMY

Preeya Subramaniam<sup>1</sup>, Vanusha Devaraja<sup>1</sup>, Goh Qing Ci<sup>1</sup>, Patricia Lee Siow Ping<sup>1</sup>

<sup>1</sup>Hospital Melaka

#### INTRODUCTION

Steroid cell tumors are rare sex cord-stromal tumors, accounting for  $<0.1\%$  of ovarian neoplasms. Extraovarian steroid cell tumors are exceptionally rare, often androgen-secreting, and pose significant diagnostic challenges. Early recognition is essential to prevent prolonged morbidity from hyperandrogenism.

#### CASE

A 60-year-old female, 15 years after total hysterectomy and bilateral salpingo-oophorectomy for a large ovarian mass with massive ascites, presented with deranged liver function tests on routine follow-up. Ultrasonography and computed tomography imaging revealed multiple hypervascular lesions in the liver, retroperitoneum, and peritoneum, suggestive of metastatic disease, with normal-appearing adrenal glands. Biopsy of a liver lesion demonstrated a metastatic neoplasm with morphology and immunoprofile favoring a steroid cell tumor. However, metastasis from the adrenal cortex or an ovarian primary could not be excluded.

Given the prior bilateral oophorectomy, metastatic adrenocortical carcinoma was initially suspected, prompting endocrine evaluation. Further history revealed a 1-year history of progressive virilization, including increased facial hair and frontal balding. Hormonal studies demonstrated elevated testosterone (12.2 mmol/L and reference range 0.1–1.42) and dehydroepiandrosterone sulfate (15.9  $\mu\text{mol/L}$  and reference range 0.510–5.560) and the adrenocorticotrophic hormone level of 11.7 pmol/L (reference range 1.60–13.9) with suppressed gonadotrophins. Additional workup for catecholamine, cortisol, and aldosterone excess was unremarkable. The

discordance between androgen excess and normal adrenal imaging, despite absent ovarian tissue, suggested an extra-adrenal androgen-secreting steroid cell tumor. A second histopathology review and multidisciplinary discussion with radiology, gynecologic oncology, and pathology teams were undertaken. As the disease was deemed inoperable, repeat retroperitoneal lesion biopsy confirmed metastatic steroid cell tumor and guided palliative chemotherapy. She was subsequently referred to gynecologic oncology for systemic chemotherapy.

#### CONCLUSION

Extra-adrenal steroid cell tumors, though rare, should be considered in patients with hyperandrogenism long after bilateral oophorectomy, especially when adrenal imaging is normal. Multidisciplinary evaluation and repeat biopsy are often crucial for establishing the diagnosis and guiding treatment.

### EP\_A083

#### SEVERE HYPERTRIGLYCERIDEMIA-INDUCED ACUTE PANCREATITIS IN PREGNANCY: A CASE REPORT AND REVIEW OF MANAGEMENT

Shaleela Mohd Esha<sup>1</sup>, Chua Yi Jiang<sup>1</sup>, Wong Hui Chin<sup>1</sup>, Ooi Xin Yi<sup>1</sup>, Yong Sy Liang<sup>1</sup>

<sup>1</sup>Hospital Tengku Ampuan Rahimah

#### INTRODUCTION

Severe hypertriglyceridemia during pregnancy is a rare yet potentially life-threatening disorder. It is frequently linked to acute pancreatitis and poses considerable risks for both maternal and fetal morbidity.

#### CASE

We report a 35-year-old G4P3 female at 33 + 6 weeks gestation with underlying type 2 diabetes mellitus who presented with acute abdominal pain, nausea, vomiting, and poor oral intake, initially mistaken for preterm labor and sepsis. Further evaluation revealed profound hypertriglyceridemia (triglycerides 79.1 mmol/L) with markedly elevated total cholesterol (>32 mmol/L) and raised serum amylase, consistent with hypertriglyceridemia-induced acute pancreatitis. She was managed in a multidisciplinary setting with intravenous insulin infusion, dextrose supplementation, aggressive fluid resuscitation, and empiric antibiotics. Due to clinical deterioration and ongoing risk of maternal complications, she underwent emergency lower segment caesarean section and exploratory laparotomy at 34 weeks of gestation. Intraoperative findings included inflammatory intra-abdominal fluid and a bulky pancreas, supporting the diagnosis. Rapid biochemical improvement

was observed following treatment, with triglyceride levels decreasing by approximately 70% within 24 hours (79.1–24.0 mmol/L) and achieving >90% reduction over 10 days. Postpartum management included initiation of omega-3 fatty acids, fibrate, and statin therapy, resulting in sustained lipid control. Ophthalmologic examination demonstrated lipemia retinalis, further confirming severe dyslipidemia.

#### CONCLUSION

This case highlights the importance of early recognition of severe hypertriglyceridemia in pregnancy, particularly in patients with metabolic risk factors such as diabetes. Prompt initiation of insulin therapy can achieve rapid triglyceride reduction and may obviate the need for plasmapheresis in selected cases. Delivery should be considered in the setting of maternal instability. Long-term lipid management postpartum is essential for preventing recurrence and reducing future metabolic risk. A multidisciplinary approach remains critical in optimizing both maternal and fetal outcomes in this rare but serious condition.

### EP\_A084

#### SEVERE PREMATURE CORONARY ARTERY DISEASE IN HOMOZYGOUS FAMILIAL HYPERCHOLESTEROLEMIA WITH MARKED LIPID REDUCTION AFTER INCLISIRAN THERAPY

Shaleela Mohd Esha<sup>1</sup>, Hazwani Aziz<sup>1</sup>, Elliyyin Katiman<sup>1</sup>

<sup>1</sup>Hospital Tengku Permaisuri Norashikin

#### INTRODUCTION

Homozygous familial hypercholesterolemia (HoFH) is a rare inherited disorder characterized by markedly elevated low-density lipoprotein cholesterol (LDL-C) from birth, childhood xanthomas, and accelerated atherosclerotic cardiovascular disease. Achieving LDL-C targets remains difficult despite statins, ezetimibe, and lipoprotein apheresis, especially in patients with treatment interruption, poor adherence, or limited access to specialized lipid services. We report a female with genetically confirmed HoFH who developed severe premature coronary artery disease and showed marked lipid reduction after inclisiran therapy.

#### CASE

A 28-year-old Malay female with LDL receptor mutation-confirmed HoFH, diagnosed at age 7, had a strong family history of premature cardiovascular death. She underwent biweekly lipoprotein apheresis from ages 8 to 15 years, but later defaulted on follow-up. During pregnancy in 2021, weekly then biweekly apheresis was reintroduced for severe hypercholesterolemia, but she disengaged postpartum. In 2025, she re-presented with exertional

chest pain, orthopnea, and palpitations. Examination showed widespread xanthomas. Electrocardiography demonstrated sinus tachycardia with inferolateral ST depression. Echocardiography revealed a left ventricular ejection fraction of 40%, anterior and septal akinesia, severe mitral regurgitation, moderate tricuspid regurgitation, and pulmonary hypertension. Her lipid profile showed total cholesterol 18.1 mmol/L and LDL-C 14.9 mmol/L. Coronary angiography demonstrated triple-vessel disease with left main stem involvement and critical right coronary ostial stenosis. Coronary artery bypass grafting was advised but declined. She was treated with high-dose rosuvastatin, ezetimibe, dual antiplatelet therapy, and inclisiran 284 mg. After one dose of inclisiran, total cholesterol fell to 6.78 mmol/L and LDL-C to 4.71 mmol/L, a reduction of more than 60%.

#### CONCLUSION

This case highlights the aggressive natural history of inadequately controlled HoFH and the importance of sustained lifelong therapy. Inclisiran may provide additional LDL-C reduction in selected HoFH patients, although long-term cardiovascular outcome data remain limited.

## EP\_A085

### CONCURRENT DIABETIC KETOACIDOSIS AND THYROID STORM IN LATE PREGNANCY: A RARE DUAL ENDOCRINE EMERGENCY

Sarojini Devi Simanchalam<sup>1</sup>, Wong Poh Shean<sup>1</sup>, Noor Lita Adam<sup>1</sup>, Lee Pei Shin<sup>2</sup>, Fauzi Azizan<sup>2</sup>

<sup>1</sup>Unit Endocrinology, Department of Medicine, Hospital Tuanku Ja'afar Seremban

<sup>2</sup>Department of Medicine, Hospital Tuanku Ampuan Najihah

#### INTRODUCTION

Diabetic ketoacidosis (DKA) and thyroid storm are individually rare but potentially fatal endocrine crises in pregnancy. Each carries significant maternal and fetal morbidity, with mortality risk compounded when they occur concomitantly. Physiological and pharmacokinetic changes of pregnancy, combined with overlapping symptoms, necessitate urgent treatment strategies.

#### CASE

A 29-year-old G2P2 female at 29 weeks' gestation, with poorly controlled type 2 diabetes mellitus (hemoglobin A1c 8.1%) on a basal-bolus insulin regimen and Graves' disease managed with carbimazole, non-adherent to medications, presented with fever, vomiting, and dyspnea. On examination, she was tachycardic (HR 138 bpm), hypotensive (BP 94/60 mmHg), and hypoxic. Laboratory investigations revealed hyperglycemia (glucose 27.1 mmol/L),

severe metabolic acidosis (pH 7.02, bicarbonate 4.9 mmol/L), and elevated serum ketones (4.6 mmol/L), consistent with DKA. Thyroid function tests showed suppressed thyroid-stimulating hormone (<0.005 mIU/L) and elevated free T4 (28.2 pmol/L), with a Burch-Wartofsky score of 70. Unfortunately, intrauterine fetal demise was confirmed upon the patient's presentation to the emergency department. She was intubated and admitted to the intensive care unit, receiving fluid resuscitation judiciously according to the DKA regimen, with frequent assessment of volume status. Intravenous insulin and potassium supplements were commenced concurrently. Metabolic stabilization was achieved within 24 hours. Carbimazole, propranolol, Lugol's iodine, and intravenous hydrocortisone were started for treatment of thyroid storm. A breech-assisted vaginal delivery was performed, and her postpartum course was uneventful.

#### CONCLUSION

The case reveals the catastrophic potential of concurrent DKA and thyroid storm in pregnancy, where rapid maternal deterioration and poor fetal outcomes can occur despite timely intervention. High clinical suspicion, early biochemical confirmation, and coordinated multidisciplinary management are vital. Precipitating factors, particularly medication non-adherence, must be addressed through intensive patient education and structured follow-up to prevent recurrence.

## EP\_A086

### EXTRA-ADRENAL AND UNEXPECTED: A RARE CASE OF PRIMARY RETROPERITONEAL PARAGANGLIOMA

Raja Nurul Azafirah Raja Amir Shah<sup>1</sup>, Masliza Hanuni Mohd Ali<sup>1</sup>, Wan Mohd Hafez Wan Hamzah<sup>1</sup>, Nor Hisham M<sup>2</sup>

<sup>1</sup>Endocrinology Unit, Medical Department, Hospital Sultanah Nur Zahirah

<sup>2</sup>Surgical Department, Hospital Sultanah Nur Zahirah

#### INTRODUCTION

Paragangliomas are rare neuroendocrine tumors arising from extra-adrenal chromaffin cells, with an estimated incidence of 2–8 cases per million per year. These tumors originate from neural crest-derived cells of the sympathetic and parasympathetic paraganglia and may secrete catecholamines, resulting in malignant hypertension or symptoms such as headache, palpitations, and diaphoresis. They can occur anywhere along the paravertebral and para-aortic regions from the skull base to the pelvic floor.

## CASE

We report a case of a 14-year-old male with no known premorbid conditions who presented with presyncope and a 1-month history of headache. On examination, he had severe hypertension (242/167 mmHg), tachycardia (127 bpm), and grade IV hypertensive retinopathy. Investigations showed preserved renal function with markedly elevated 24-hour urinary metanephrines (normetanephrine 90.75  $\mu\text{mol/L}$ ). Computed tomography revealed a lobulated, heterogeneously enhancing mass measuring 5.0  $\times$  6.1  $\times$  5.4 cm along the left margin of the abdominal aorta at the infrarenal level, suggestive of an extra-adrenal lesion. Gallium-68 PET scan demonstrated a somatostatin receptor-avid left peritoneal mass. The patient underwent exploratory laparotomy and tumor excision, complicated intraoperatively by blood pressure lability requiring nitroprusside and inotropic support. Postoperatively, he improved significantly and was able to wean off all antihypertensive medications. Histopathology confirmed left retroperitoneal paraganglioma.

## CONCLUSION

Primary peritoneal paraganglioma is a rare but important cause of secondary hypertension, especially in young patients presenting with hypertensive emergency. High index of suspicion is essential for early diagnosis. Management requires a multidisciplinary approach with careful preoperative optimization to minimize perioperative complications. Surgical resection remains the definitive treatment and, as demonstrated in this case, can result in marked clinical improvement with resolution of hypertension.

## EP\_A087

### WARBURG EFFECT-ASSOCIATED NON-INSULIN-MEDIATED HYPOGLYCEMIA IN CHRONIC INFECTION

Tilagamaty Murthy<sup>1</sup>, Sharifah Noor Adrilla Long Mohd Noor Affendi<sup>1</sup>, Shazatul Reza Mohd Redzuan<sup>1</sup>, Gayathri Devi Krishnan<sup>1</sup>, Subashini Rajoo<sup>1</sup>

<sup>1</sup>Endocrine Unit, Department of Internal Medicine, Hospital Kuala Lumpur

## INTRODUCTION

The Warburg effect refers to a metabolic shift in which cells preferentially utilize aerobic glycolysis rather than oxidative phosphorylation despite adequate oxygen availability. This phenomenon is increasingly recognized as the mechanism for tumor-associated hypoglycemia, or paraneoplastic syndromes such as insulin-like growth factor-2 (IGF-2)-mediated non-islet cell tumor hypoglycemia. We present a case of Warburg effect with management challenges.

## CASE

A 47-year-old male with advanced, treatment-naive retroviral disease presented with chronic cough, progressive right thigh swelling, constitutional symptoms over several months, followed by reduced responsiveness for 2 days prior to admission. Clinically, he was delirious, cachectic with generalized lung crepitations and right thigh mass. He was diagnosed with smear-negative disseminated tuberculosis, and thigh mass was considered either a tuberculous granuloma or sarcoma.

During hospitalization, he developed recurrent hypoglycemia with lactatemia despite intravenous dextrose, optimized enteral feeding and a 1-day course of intravenous octreotide. His blood investigations showed full blood count, renal function test, liver function test, and serum ketone within normal range. His arterial blood gas analysis showed type B lactic acidosis with persistent lactatemia.

At the time of hypoglycemia (RBS: 3.1 mmol/L), his serum insulin was suppressed, C-peptide was low-normal, morning cortisol was elevated, and IGF-1 was markedly reduced suggestive of non-insulin-mediated hypoglycemia secondary to Warburg effect.

## CONCLUSION

In patients with retroviral disease and tuberculosis, Warburg effect may lead to poorer clinical outcomes and management may be challenging. Thus, definitive antimicrobial therapy with second generation somatostatin analogues (Pasireotide) may be considered in selected cases to modulate dysregulated hormonal and metabolic pathways. Early identification and timely targeted intervention are crucial to improving outcomes in this high-risk population.

## EP\_A088

### WHEN HYPOGLYCEMIA SPEAKS LOUDER THAN THE CHEST: A DECADE-LATE RECURRENCE OF IGF-2-MEDIATED NON-ISLET CELL TUMOR HYPOGLYCEMIA

Li Li Kwan<sup>1</sup> and Deviga Lachumanan<sup>2</sup>

<sup>1</sup>Department of Internal Medicine, Hospital Port Dickson

<sup>2</sup>Endocrinology Unit, Department of Internal Medicine, Hospital Port Dickson

## INTRODUCTION

Non-islet cell tumor hypoglycemia (NICTH) is a rare paraneoplastic syndrome caused by tumor secretion of insulin-like growth factor-2 (IGF-2), leading to recurrent hypoinsulinemic hypoglycemia. It is most commonly associated with large mesenchymal tumors, such as solitary

fibrous tumor, particularly those arising from the pleura or lungs. This phenomenon, also known as Doege–Potter syndrome, may precede tumor detection or signal tumor recurrence. We report a striking case of late malignant recurrence presenting solely with hypoglycemia after a decade of remission.

#### CASE

A 68-year-old female was initially presented in 2016 with respiratory symptoms and recurrent symptomatic fasting and post-prandial hypoglycemia, and was found to have a large left upper lobe mass. Tumor resection in 2017 resulted in complete resolution of hypoglycemia. She remained asymptomatic for several years. In 2023, she developed recurrent hypoglycemia without respiratory or constitutional symptoms. Biochemical evaluation demonstrated hypoinsulinemic hypoglycemia with suppressed insulin and C-peptide, low IGF-1, and markedly elevated IGF-2, resulting in an IGF-2:IGF-1 ratio of 25, consistent with IGF-2-mediated NICTH. Computed tomography imaging revealed a large left thoracic mass with invasion into the intercostal muscles and diaphragm with extension toward the stomach, associated with contralateral lung nodules and possible liver metastases, suggesting recurrent malignant disease. Hypoglycemia improved with glucocorticoid therapy, and the patient was referred for oncological assessment. Despite initiation of systemic chemotherapy, her disease progressed and she succumbed during treatment.

#### CONCLUSION

This case highlights several important lessons: Firstly, recurrent hypoinsulinemic hypoglycemia warrants evaluation for NICTH even in the absence of tumor-related symptoms. Secondly, solitary fibrous tumors may recur or undergo malignant transformation after prolonged disease-free intervals; and glucocorticoids provide effective metabolic control but do not alter oncologic prognosis. Long-term surveillance should be considered in patients with prior solitary fibrous tumors due to the risk of delayed recurrence and paraneoplastic complications.

## EP\_A089

### MATERNAL HYPOGLYCEMIA WITH LARGE UTERINE FIBROID AND PARADOXICAL FETAL OVERGROWTH: PLAUSIBLE MECHANISMS

Jayaseelan Sekaran<sup>1</sup>, Vickneswaran Marathamuthu<sup>1</sup>,  
Ooi Chuan Ng<sup>2</sup>

<sup>1</sup>Hospital Sultan Abdul Aziz Shah

<sup>2</sup>Universiti Putra Malaysia

#### INTRODUCTION

Uterine fibroids are common in reproductive-age women and are associated with obstetric complications. Their potential contribution to maternal metabolic disturbances is poorly described. We report a case of maternal hypoglycemia in the setting of a large uterine fibroid and fetal overgrowth, suggesting a possible endocrine–metabolic interaction.

#### CASE

A 39-year-old multiparous female with no history of diabetes or endocrine disease had a large lower-segment uterine fibroid measuring 8 × 10 cm. Pregnancy was otherwise uncomplicated until 39 weeks, when she underwent classical Caesarean section for transverse lie and delivered a large-for-gestational-age infant.

Postpartum, she developed recurrent symptomatic hypoglycemia despite normal hemoglobin A1c (5.0%) and preserved thyroid and adrenal function. There was no evidence of sepsis, liver disease, medication exposure, or insulinoma. Hypoglycemia resolved spontaneously following delivery. Postnatal imaging showed persistence of the fibroid (6 × 9 cm). She remains under follow-up, considering interval laparoscopic myomectomy with bilateral tubal ligation.

The coexistence of maternal hypoglycemia and fetal overgrowth raises the possibility of altered maternal–fetal glucose dynamics. Large mesenchymal tumors may produce insulin-like growth factor 2 (IGF-2), causing non-islet cell tumor hypoglycemia. Fibroid-related utero-placental hemodynamic changes or increased fetal glucose demand may also contribute. While causality cannot be established, the temporal resolution post-delivery suggests a contributory role of the fibroid in metabolic disturbance.

#### CONCLUSION

This case highlights a rare but clinically relevant association between a large uterine fibroid, maternal hypoglycemia, and fetal overgrowth. In pregnant patients with unexplained hypoglycemia, uterine fibroids may represent an overlooked factor. Multidisciplinary follow-up and further research into IGF signaling and placental–tumor interactions are warranted.

## EP\_A090

### OSTEOPOROSIS TREATMENT PRESCRIPTION IN VERY HIGH-RISK FRACTURE POPULATION: A SINGLE-CENTRE EXPERIENCE

Victoria Wei Fang Boey<sup>1</sup>, Hwee Ching Tee<sup>2</sup>, Jin Hui Ho<sup>2</sup>

<sup>1</sup>Department of Medicine, Hospital Tuaran

<sup>2</sup>Endocrine Unit, Department of Medicine, Hospital Queen Elizabeth II

#### INTRODUCTION

Osteoporosis is associated with increased fracture risk, leading to significant morbidity and mortality. Despite established clinical guidelines, a substantial gap remains between recommended and actual prescribing practices. Patients at very high fracture risk have poorer outcomes and are recommended to receive anabolic or parenteral antiresorptive therapies. However, access to these treatments is limited in Malaysian government hospitals due to cost constraints.

#### METHODOLOGY

This retrospective clinical audit evaluated osteoporosis treatment prescriptions among very high-risk patients attending the Osteoporosis Endocrine Clinic at Hospital Queen Elizabeth II from 2020 to 2025. Very high fracture risk was defined according to the American Association of Clinical Endocrinologists criteria, including recent fractures, fractures on therapy, multiple fractures, high fall risk, glucocorticoid use, very high FRAX probability (>30% major osteoporotic fracture or >4.5% hip fracture), or very low bone mineral density (T-score <-3.0).

#### RESULTS

A total of 120 patients were included, with a median age of 68 years (interquartile range [IQR] 62–73). Most were of Chinese ethnicity (60%,  $n = 72$ ), with a median body mass index of 22.6 kg/m<sup>2</sup> (IQR 19.6–26). Secondary osteoporosis was present in 70% of patients, commonly due to aromatase inhibitor use (45%), glucocorticoid-induced osteoporosis (13.3%), thyroid disorders (10.8%), and vitamin D insufficiency (9.2%). Only 12% of patients ( $n = 14$ ) received anabolic or parenteral antiresorptive therapy, while 88% ( $n = 106$ ) were treated with oral alendronate. Among those on alendronate, 19.8% ( $n = 21$ ) developed adverse outcomes, including treatment failure ( $n = 13$ ), gastrointestinal side effects ( $n = 6$ ), and atypical femoral fractures ( $n = 2$ ).

#### CONCLUSION

The uptake of guideline-recommended therapy in very high-risk osteoporosis patients remains low. A notable

proportion of patients treated with oral alendronate experienced adverse outcomes or suboptimal responses. Addressing financial and systemic barriers is crucial to improving access to advanced therapies and optimizing patient outcomes.

## EP\_A091

### REDEFINING DEFINITIVE THERAPY: PERCUTANEOUS ETHANOL ABLATION FOR PRIMARY HYPERPARATHYROIDISM IN A NONSURGICAL CANDIDATE

Thunisha Manoharan<sup>1</sup>, Yuch Chien Kuan<sup>1</sup>, Pei Lin Chan<sup>2</sup>, Whilmore Johin<sup>3</sup>, Dhayal Balakrishnan<sup>3</sup>

<sup>1</sup>Endocrine Unit, Miri General Hospital

<sup>2</sup>Endocrine Unit, Sarawak General Hospital

<sup>3</sup>Radiology Department, Sarawak General Hospital

#### INTRODUCTION

Parathyroidectomy is the definitive treatment for primary hyperparathyroidism (PHPT) due to parathyroid adenoma. However, surgery may be contraindicated in patients with significant comorbidities. Ultrasound-guided percutaneous ethanol ablation (PEA) is a minimally invasive alternative that induces biochemical remission through targeted destruction of hyperfunctioning tissue. We report a case of PHPT successfully managed with PEA in a patient unfit for surgery due to cardiac dysfunction.

#### CASE

In 2023, a 53-year-old female with stage IB breast carcinoma was found to have persistent hypercalcemia (2.68–3.59 mmol/L) during chemotherapy and post-mastectomy follow-up. Evaluation excluded bone metastases. Biochemical assessment demonstrated elevated intact parathyroid hormone (iPTH) levels 38.6 pmol/L (Reference: 1.6–6.0 pmol/L), hypophosphatemia (0.42–0.80 mmol/L), and elevated alkaline phosphatase (ALP) 215–309 U/L (30–120 U/L)—consistent with PHPT. Tc-99 m sestamibi scintigraphy localized a 1.1 × 1.5 × 1.2 cm hyperfunctioning parathyroid adenoma.

Initial management prioritized oncological therapy, including trastuzumab for 1 year. Hypercalcemia was intermittently controlled with intravenous hydration and zoledronic acid when calcium exceeded 3 mmol/L.

Her disease was complicated with severe osteoporosis (DEXA T-score -3.3) with vertebral fractures, renal impairment requiring cessation of alendronate, and medullary nephrocalcinosis on computed tomography surveillance.

Following completion of cancer therapy, she was evaluated for parathyroidectomy. Preoperative assessment revealed NYHA class II heart failure, with reduced ejection fraction (36%) and severe tricuspid regurgitation attributed to trastuzumab-related cardiomyopathy. Despite optimal medical therapy, she was deemed high-risk for surgery. Cinacalcet failed to achieve sustained calcium control with levels exceeding 3 mmol/L. She was therefore referred for PEA.

Post-procedure, iPTH decreased 80% by Day 5 (54.9–10.6 pmol/L), with sustained normocalcemia (2.25 mmol/L) at 10 days without further need for cinacalcet.

### CONCLUSION

This case illustrates that PEA can serve as definitive therapy for PHPT in patients unsuitable for surgery. It provides rapid and sustained biochemical control, while avoiding operative risk, supporting its role in individualized management.

## EP\_A092

### EXPANDING THE SPECTRUM OF VITAMIN D-DEPENDENT RICKET TYPE 2: DOMINANT-NEGATIVE VDR MUTATION AND POSTPUBERTAL CALCIUM ADAPTATION

Mohd Hazriq Awang<sup>1,2</sup>, Shireene Ratna Vethakkan<sup>1</sup>, Ooi Ying Guat<sup>1</sup>, Tharsini Sarvanandan<sup>1</sup>

<sup>1</sup>Endocrine Unit, University Malaya Medical Centre (UMMC)

<sup>2</sup>Medical Faculty, Universiti Teknologi MARA (UiTM)

### INTRODUCTION

Vitamin D-dependent rickets type 2 (VDDR2) is traditionally defined by biallelic vitamin D receptor (VDR) mutations causing resistance to 1,25(OH)<sub>2</sub>D. We describe a case of the classical VDDR2 phenotype with a single VDR mutation and an interesting physiological adaptation.

### CASE

A female diagnosed with rickets at age three presented with a femoral fracture, severe short stature, hypocalcemia (2.1 mmol/L; NR 2.35–2.70), hypophosphatemia (0.8 mmol/L; NR 1.5–2.10), and evidence of renal phosphate wasting (TMP/GFR 0.5 mmol/L; NR 1.5–2.4). Biochemistry showed markedly elevated alkaline phosphatase (1,227 IU/L; NR 50–136) and secondary hyperparathyroidism (20.7 pmol/L; NR 0.8–7.8). Despite hypocalcemia, 1,25(OH)<sub>2</sub>D was significantly elevated (>450 pmol/L; NR 60–150), consistent with VDDR2. There was no initial family history; however, subsequent evaluation of her mother—prompted by the patient's diagnosis—revealed a similar biochemical profile, along with short stature (142 cm) and a history of multiple fractures. Genetic analysis in both individuals identified

a heterozygous missense mutation in exon 10 of the VDR gene, affecting the ligand-binding domain, supporting a pattern of dominant inheritance. The patient was treated with cholecalciferol (1,200 IU daily), calcitriol (5–6 µg daily), and calcium carbonate (2,000 mg daily). Although biochemical responsiveness to therapy was evident, poor adherence resulted in suboptimal metabolic control throughout childhood and adolescence, including a second fracture at age 15 and a final adult height of 124 cm. Notably, calcium and phosphate levels progressively normalized after puberty, with sustained biochemical stability despite the patient omitting the treatment.

### CONCLUSION

This case provides two important insights. First, it represents the fourth reported case worldwide demonstrating a dominant-negative effect of a VDR gene mutation, whereby a single mutant receptor interferes with wild-type VDR function. Second, it highlights postpubertal calcium adaptation, in which vitamin D-independent intestinal absorption may restore mineral homeostasis, and disease severity can attenuate over time through adaptive physiological mechanisms.

## EP\_A093

### GIANT PARATHYROID ADENOMA WITH DELAYED HUNGRY BONE SYNDROME: A CASE REPORT

Aina Mardiah Zulkifle<sup>1,2</sup>, Nurain Mohd Noor<sup>2</sup>, Zulaikha Che Che Embi<sup>3</sup>, Noor Lita Mohd Adam<sup>4</sup>

<sup>1</sup>Hospital Canselor Tuanku Muhriz UKM

<sup>2</sup>Endocrine Unit, Internal Medicine Department, Hospital Putrajaya

<sup>3</sup>Jabatan Patologi, Hospital Putrajaya

<sup>4</sup>Endocrine Unit, Internal Medicine Department, Hospital Tuanku Ja'afar Seremban

### INTRODUCTION

Giant parathyroid adenomas (GPAs), defined as lesions >3.5 g, are rare. Their size, biochemical severity, and compressive features often mimic carcinoma, creating diagnostic and surgical challenges.

### CASE

A 33-year-old female was incidentally found to have hypercalcemia during evaluation after her newborn developed severe hypocalcemic seizures requiring NICU admission. Maternal calcium was 2.95 mmol/L with hypophosphatemia. Subsequent reviews showed persistent hypercalcemia (3.15–3.3 mmol/L), hypophosphatemia (0.32–0.51 mmol/L), and markedly elevated intact parathyroid hormone (85–96 pmol/L). She had vitamin D deficiency, very high alkaline phosphatase (1,329 U/L), and progressive

bone pain with reduced mobility. Bone mineral density revealed Z scores of -2.9 (hip) and -3.3 (lumbar spine).

Multiphase computed tomography demonstrated a multilobulated 6.9 cm mass extending from C5 to T2, compressing the esophagus and raising suspicion for carcinoma. Endoscopic evaluation excluded mucosal invasion. She underwent en bloc left inferior parathyroidectomy with hemithyroidectomy. Intraoperative parathyroid hormone fell from 41.7 to 13.4 pmol/L, confirming complete excision. The gland measured 65 × 20 × 15 mm and weighed 18.4 g. Histopathology revealed a hypercellular parathyroid tumor with endocrine atypia but no invasion, consistent with a giant adenoma.

Postoperatively, calcium was initially stable (1.99 mmol/L at discharge) but fell to 1.68–1.82 mmol/L at 2 weeks despite high-dose supplementation. Hypocalcemia persisted for 6 weeks, consistent with delayed hungry bone syndrome, likely precipitated by preoperative vitamin D deficiency, markedly elevated alkaline phosphatase, and low bone mineral density. With intensive supplementation, calcium gradually stabilized, and symptoms improved.

#### CONCLUSION

GPA can closely mimic carcinoma, with endocrine atypia complicating histopathological interpretation. This case illustrates both diagnostic overlap and the unusual, delayed onset of hungry bone syndrome, emphasizing the need for preoperative risk assessment, correction of metabolic deficiencies, and extended postoperative monitoring. Rare presentations such as delayed hungry bone syndrome refine management strategies and improve outcomes in primary hyperparathyroidism.

## EP\_A094

### CLINICAL USE OF DENOSUMAB FOR REFRACTORY HYPERCALCEMIA: A RETROSPECTIVE CASE SERIES

Mohammad Amirul Shahril<sup>1,2</sup>, Florence Hui Sieng Tan<sup>1</sup>, Ee Wen Loh<sup>1</sup>, Pei Lin Chan<sup>1</sup>, Sing Yee Sim<sup>1,2</sup>

<sup>1</sup>Endocrine Unit, Department of Medicine, Sarawak General Hospital

<sup>2</sup>Universiti Malaysia Sarawak (UNIMAS)

#### INTRODUCTION

Severe hypercalcemia is most commonly caused by primary hyperparathyroidism (PHPT) and malignancy. While standard therapies are effective in most cases, a subset of patients have persistent or refractory hypercalcemia. We present a retrospective case series detailing the clinical characteristics, biochemistry, and outcomes of patients treated with denosumab for hypercalcemia.

#### CASES

Seven patients with severe hypercalcemia were identified, comprising five with PHPT and two with malignancy-associated hypercalcemia. The mean age was 70.4 years (range 55–86), with 71% female ( $n = 5$ ) and 29% male ( $n = 2$ ). Baseline corrected calcium ranged from 2.92 to 4.59 mmol/L, with a mean of 3.26 mmol/L. In the PHPT cohort, parathyroid hormone (PTH) levels were significantly elevated (16.7–168 pmol/L), while malignancy patients had suppressed PTH (0.6 and 0.9 pmol/L).

Prior to denosumab, 4/7 patients (57%) received bisphosphonates, 3/7 (43%) received calcitonin, and 1/7 (14%) was treated with cinacalcet. Denosumab resulted in a mean reduction in corrected calcium of 0.22 mmol/L from 3.26 to 3.03 mmol/L.

Biochemical response was observed in 5/7 patients (71%). Of these, 3 patients (43%) achieved normocalcemia, while 2 patients (29%) demonstrated a partial response. The remaining 2/7 patients (29%) showed no significant improvement in calcium levels. Among responders, the mean time to calcium reduction to <3.0 mmol/L was 27 days (range 7–47). Repeat dosing was required in the majority of patients, with a mean of 1.7 doses per patient (range 1–4), indicating variability in both onset and durability of response. Among patients with PHPT, four underwent parathyroidectomy, and one declined surgery. Both patients with malignancy were managed nonsurgically.

#### CONCLUSION

Denosumab achieved normocalcemia in 43% of patients, with additional partial responses. Its effects were variable, with delayed response and frequent need for repeat dosing, supporting its role as an adjunctive or bridging therapy rather than as a definitive treatment.

## EP\_A095

### THE HIGH BONE DENSITY PARADOX: PRIMARY HYPERPARATHYROIDISM IN THE SETTING OF OSTEOPETROSIS

Marisa Masera Marzukie<sup>1</sup>, Shireene Ratna Vethakkan<sup>1</sup>, Jeyakantha Ratnasingam

<sup>1</sup>Universiti Malaya Medical Centre

#### INTRODUCTION

Primary hyperparathyroidism (PHPT) is a common disorder that typically leads to increased bone turnover and reduced bone mineral density (BMD). Osteopetrosis, in contrast, is a rare, inherited disorder of defective osteoclast function, resulting in diffusely sclerotic but structurally fragile bones. The coexistence of both conditions is rare and can significantly alter the expected skeletal phenotype of PHPT.

## CASE

We report a 77-year-old female with a previous history of resected ovarian carcinoma in remission, chronic iron deficiency anemia, and hypothyroidism. During a hospital admission for a lacunar infarct, an incidental finding of sclerotic skull lesions on computed tomography (CT) brain prompted further investigation. She had no history of fractures, hearing impairment, or family history of parathyroid or bone disorders. Biochemistry revealed parathyroid-dependent hypercalcemia with normal renal function. Bone turnover markers showed a normal resorption marker (BCTX) but an elevated formation marker (P1NP), with a mildly raised alkaline phosphatase. A sestamibi scan localized a probable left upper parathyroid adenoma, despite a negative neck ultrasound. Skeletal survey unexpectedly revealed widespread osteosclerosis of the skull, spine, and long bones, with a markedly elevated BMD on densitometry. Review of prior imaging confirmed that these sclerotic changes predated her current presentation, having been present on CTs from over a decade ago. Recurrent malignancy was excluded with repeat imaging and tumor markers. A diagnosis of PHPT secondary to parathyroid adenoma, coexisting with underlying, previously unrecognized osteopetrosis, was made. The patient declined both recommended parathyroidectomy and genetic studies.

## CONCLUSION

This case demonstrates a rare coexistence of two pathologies with opposing effects on bone metabolism. The underlying osteopetrosis, characterized by defective osteoclasts, likely rendered the patient's osteoclasts resistant to the catabolic effects of elevated PTH. This resulted in an atypically normal bone resorption marker and an unexpectedly high BMD, despite the diagnosis of PHPT.

## EP\_A096

### THE CALCIUM CHASE: UNMASKING PARATHYROID CARCINOMA WITH CONCURRENT PAPILLARY THYROID MICROCARCINOMA

Fatin Liyana Binti Shahabudin<sup>1</sup>, Nur Nisrina Binti Yahya<sup>1</sup>, Nor Shaffinaz Yusoff Azmi Merican<sup>1</sup>, Shartiyah Ismail<sup>1</sup>

<sup>1</sup>Endocrinology Unit, Department of Medicine, Hospital Sultanah Bahiyah

## INTRODUCTION

Parathyroid carcinoma is a rare endocrine malignancy found in 1–5% of patients with primary hyperparathyroidism. It commonly presents with severe hypercalcemia and

markedly elevated parathyroid hormone (PTH) levels. We report a challenging case of parathyroid carcinoma presenting with refractory hypercalcemia with incidental papillary thyroid microcarcinoma.

## CASE

A 63-year-old female with hypertension, diabetes mellitus, dyslipidemia, and ischemic heart disease had been followed for primary hyperparathyroidism since 2014 (PTH5.5 pmol/L, calcium range 2.3–4.7 mmol/L). Initial neck ultrasound was suggestive of parathyroid adenoma over left side, but parathyroid scintigraphy failed to localize a lesion. She refused surgical intervention initially until April 2025, then she later agreed. Re-evaluation prior to operation revealed PTH level 76 pmol/L, and repeated parathyroid scintigraphy showed mild sestamibi avid uptake on left thyroid nodule. While awaiting surgery, she was admitted with a hypercalcemic crisis (serum calcium 3.7–5.38 mmol/L), complicated with acute kidney injury. Repeated ultrasound neck revealed extrathyroidal lesion adjacent to inferior pole of left thyroid (1.6 × 1.7 × 1.2 cm). She required aggressive intravenous hydration, intravenous pamidronate, calcitonin, and Denosumab to optimize her calcium level peri-operatively. She underwent left neck exploration with en-bloc left inferior parathyroidectomy, left hemithyroidectomy, and central neck dissection in November 2025. Histopathological examination confirmed parathyroid carcinoma (pT3N1) with nodal metastasis (1/4 lymph nodes positive) and an incidental papillary thyroid microcarcinoma measuring 1 mm (pT1a).

## CONCLUSION

This case highlights the challenges of perioperative hypercalcemia management in parathyroid carcinoma. Effective preoperative control often requires multiple treatment modalities. Severe refractory hypercalcemia and high PTH level should raise a high index of suspicion for malignancy. Early complete resection is the cornerstone of treatment and is associated with optimal outcomes.

## EP\_A097

### SEVERE OSTEOPOROSIS WITH FRAGILITY FRACTURE REVEALING PRIMARY HYPERPARATHYROIDISM

Sarojini Devi Simanchalam<sup>1</sup>, Poh Shean Wong<sup>1</sup>, Nor Afidah Abdul Karim<sup>1</sup>, Noor Lita Adam<sup>1</sup>, Fauzi Azizan<sup>2</sup>

<sup>1</sup>Department of Medicine and Endocrinology, Hospital Tuanku Jaafar

<sup>2</sup>Department of Medicine, Hospital Tuanku Ampuan Najihah

#### INTRODUCTION

Primary hyperparathyroidism (PHPT) is frequently asymptomatic or detected incidentally; however, delayed diagnosis may lead to severe skeletal complications. Early recognition is essential, as timely identification and management of parathyroid disease can prevent significant morbidity, although diagnosis may be challenging when clinical and imaging findings are inconclusive.

#### CASE

A 46-year-old female with severe bilateral hearing impairment presented to the orthopedic clinic with 3 years' history of bilateral knee pain and was found to have a right intertrochanteric femur fracture following minimal trauma. She was referred for evaluation of suspected secondary osteoporosis. She has had intermittent constipation and long-standing oligomenorrhea since menarche. There was no history of childhood fractures or use of medications affecting bone metabolism. Examination revealed bilateral knee bowing.

Initial evaluation considered metabolic bone disease, including Paget's disease; however, skeletal survey showed no features suggestive of Paget's disease or multiple myeloma.

Biochemical investigations demonstrated persistent hypercalcemia (2.65–3.1 mmol/L) with inappropriately elevated intact parathyroid hormone (peak 7.62 pmol/L), consistent with PHPT. Serum phosphate was low-normal. Concomitant vitamin D deficiency (25-OH vitamin D 34.46 nmol/L) improved following replacement. Bone mineral density confirmed severe osteoporosis (lumbar spine T-score -5, z-score -4.1); (forearm -6.7, z-score -6.1) reflecting prolonged untreated disease.

Neck ultrasound demonstrated a mixed solid-cystic lesion posterior to the right thyroid lobe, suggestive of a parathyroid adenoma. The TC-99m Sestamibi scan showed no definite focal uptake. However, subsequent SPECT-CT revealed focal tracer uptake at the posterior right thyroid gland, consistent with a hyperfunctioning parathyroid gland. Parathyroidectomy was done. Postoperatively, the calcium level normalized.

#### CONCLUSION

Severe osteoporosis and fragility fracture occur, reflecting prolonged exposure to excess parathyroid hormone and significant skeletal morbidity. Early biochemical evaluation in unexplained severe osteoporosis is essential, as timely diagnosis and definitive management of parathyroid disease are critical to halt ongoing bone loss and prevent irreversible complications.

## EP\_A098

### A CHALLENGING CASE OF PARATHYROID CARCINOMA IN AN ADOLESCENT

S. Muhammad Imran<sup>1</sup> and Tong Chin Voon<sup>1</sup>

<sup>1</sup>Hospital Putrajaya

#### INTRODUCTION

Parathyroid carcinoma (PC) is an exceedingly rare malignancy. Definitive surgical management with en bloc resection is crucial for cure, but the post-operative course can be complicated by profound metabolic derangements, most notably hungry bone syndrome (HBS). We report a case of PC in a 15-year-old female to highlight the challenges in perioperative management.

#### CASE

A 15-year-old female presented with a painless, palpable neck mass. There is no family history of note. Investigations revealed severe primary hyperparathyroidism (PHPT) with a corrected calcium of 3.4 mmol/L and an elevated intact parathyroid hormone level of 118.6 pg/mL. Alkaline phosphatase was markedly elevated at 1,168 U/L. Ultrasound, computed tomography neck, and a sestamibi scan identified a large, lobulated 4.7-cm mass posterior to the right thyroid lobe, suspicious of malignancy. Bone mineral density of the forearm was severely diminished, with a Z-score of -6.6. The patient underwent right hemithyroidectomy and parathyroidectomy with intraoperative neural monitoring. Intraoperative parathyroid hormone levels dropped from a pre-excision level of 120.1–16.5 pg/mL 5 minutes post-excision, confirming complete resection of the hyperfunctioning tissue. Histopathological examination confirmed the diagnosis of PC, demonstrating lymphovascular invasion and clear resection margins. The Ki-67 proliferation index was 5%. Post-operatively, the patient developed hypocalcemia, with corrected calcium dropping to a nadir of 1.95 mmol/L. This was managed with intensive calcium and activated vitamin D supplementation. At 10 months post-surgery, the patient continues to require supplementation for persistent hypocalcemia. Surveillance ultrasound at 3 months showed no evidence of recurrence, and she is planned for ongoing annual monitoring.

## CONCLUSION

This case illustrates the need for a high index of suspicion for PC in young patients with severe PHPT. The post-operative course highlights the challenges in managing HBS, hypoparathyroidism, and long-term surveillance.

## EP\_A099

### PACLITAXEL-INDUCED HYPOCALCEMIA IN A PATIENT WITH METASTATIC BREAST DISEASE AND UNDERLYING HYPOPARATHYROIDISM

Marina Norman<sup>1</sup>, Nur Aini Eddy Warman<sup>1</sup>, Nur Haziqah Baharum<sup>1</sup>, Aimi Fadilah Mohamad<sup>1</sup>, Mohd Hazriq Awang<sup>1</sup>, Fatimah Zaherah Mohamed Shah<sup>1</sup>, Rohana Abdul Ghani<sup>1</sup>

<sup>1</sup>Department of Internal Medicine, Faculty of Medicine, Universiti Teknologi MARA

## INTRODUCTION

Hypocalcemia in patients with advanced malignancy is usually attributed to bone metastases, vitamin D deficiency, renal impairment, or antiresorptive therapy. Paclitaxel, a taxane-based chemotherapy agent widely used for breast cancer, is not commonly associated with calcium disturbances. Proposed mechanism includes renal tubular dysfunction, renal salt wasting, and disruptions in bone metabolism. In patients with underlying disorders of calcium homeostasis such as hypoparathyroidism, taxane-based chemotherapy such as Docetaxel and Paclitaxel may exacerbate calcium imbalance. We reported a case of recurrent hypocalcemia associated with paclitaxel therapy in a patient with metastatic breast cancer.

## CASE

A 42-year-old female with metastatic breast cancer, involving the liver and bones, had previously undergone neoadjuvant chemotherapy, mastectomy, and adjuvant radiotherapy. Following the disease progression, she was commenced on weekly intravenous paclitaxel at a 20% dose reduction due to prior complications and underlying metabolic risk. She had a history of post-thyroidectomy hypoparathyroidism and had previously been intolerant to docetaxel during the neoadjuvant chemotherapy, which was complicated by hypocalcemia, likely secondary to renal salt wasting.

During paclitaxel treatment, she developed recurrent symptomatic hypocalcemia, requiring multiple hospital admissions and repeated intravenous calcium gluconate infusions despite ongoing oral calcium and calcitriol supplementation, which were temporarily increased during

the chemotherapy. These episodes occurred intermittently in temporal association with paclitaxel administration, with other causes of hypocalcemia were considered less likely.

## CONCLUSION

Hypocalcemia associated with paclitaxel is rarely described in literature. This case highlights the importance of monitoring calcium level in patients receiving paclitaxel, particularly in those with pre-existing hypoparathyroidism.

## EP\_A100

### BEYOND THE OBVIOUS: UNMASKING PARATHYROID CARCINOMA IN AN ATYPICAL PRESENTATION

Pei Shin Lee<sup>1</sup> and Poh Shean Wong<sup>2</sup>

<sup>1</sup>Hospital Tuanku Ampuan Najihah

<sup>2</sup>Hospital Tuanku Ja'afar

## INTRODUCTION

Incidental hyperparathyroidism with hypercalcemia is not uncommon. However, parathyroid carcinoma is an extremely rare endocrine malignancy, accounting for less than 1% of cases of primary hyperparathyroidism.

## CASE

A 57-year-old Malay female with well-controlled type 2 diabetes was incidentally found to have hypercalcemia during hospitalization for pyelonephritis. She was asymptomatic, with no history of calcium supplementation or family history of endocrine disorders. Physical examination revealed no obvious neck swelling, and other systemic examinations were unremarkable. Investigations showed elevated serum calcium (2.87–3.4 mmol/L), low phosphate (0.34–0.76 mmol/L), and elevated intact parathyroid hormone (iPTH) (6.81 pmol/L). Her 25-OH vitamin D was deficient (45.58 nmol/L). Ultrasound of the neck revealed a solid lesion (1.6 × 2.0 × 2.8 cm) posterior to the right thyroid lobe with bilateral thyroid nodules, with the highest TR4, and normal cervical lymph nodes. Sestamibi scan showed multinodular goiter with cold nodules in bilateral thyroid lobes and a soft tissue lesion posterior to the right thyroid lobe. Subsequently, she underwent right hemithyroidectomy with intraoperative nerve monitoring and right inferior parathyroidectomy with intraoperative iPTH monitoring; the intraoperative iPTH level dropped appropriately from 24 to 2.4 pmol/L. Histopathological examination of the excised right parathyroid gland revealed parathyroid carcinoma, while the right thyroid lobe showed nodular hyperplasia. Post-operatively, calcium and iPTH levels normalized, and she remained well under follow-up.

## CONCLUSION

Parathyroid carcinoma typically presents with markedly elevated calcium and iPTH levels, often alongside a palpable neck mass. However, in this patient, serum iPTH was only slightly above the upper limit of normal, with tumor size less than 3 cm, no lymph node or surrounding structures involvement from pre-operative evaluation imaging. This highlights the variability in both physical and biochemical presentations of parathyroid carcinoma and the challenges in distinguishing it from benign parathyroid tumors pre-operatively.

## EP\_A101

### FATAL HYPERCALCEMIC CRISIS SECONDARY TO PRIMARY HYPERPARATHYROIDISM: A CASE REPORT

Pey Hui See<sup>1</sup>, Ee Wen Loh<sup>1</sup>, Pei Lin Chan<sup>1</sup>, Florence Hui Sieng Tan<sup>1</sup>

<sup>1</sup>Endocrinology Unit, Department of Medicine, Sarawak General Hospital

## INTRODUCTION

Hypercalcemic crisis, a decompensated state characterized by multiorgan dysfunction and a corrected serum calcium (CCa) level typically >3.5 mmol/L, is a rare but life-threatening endocrine emergency that requires prompt recognition and aggressive multimodal management. We report a fatal case of hypercalcemic crisis secondary to primary hyperparathyroidism, which was refractory to multiple lines of medical therapy.

## CASE

A 55-year-old female with diabetes mellitus, hypertension, and chronic kidney disease (creatinine 159  $\mu\text{mol/L}$ ; estimated glomerular filtration rate 33 mL/min) presented with 3 days of confusion, profound fatigue, and constipation, preceded by a 1-month history of polyuria and polydipsia. Her Glasgow Coma Scale (GCS) was E4V3M5. Physical examination was unremarkable, with no palpable neck swelling. Significant laboratory findings included severe hypercalcemia with markedly elevated serum intact parathyroid hormone (iPTH) (CCa 4.49 mmol/L; phosphate 1.01 mmol/L; iPTH 60.1 pmol/L [N 1.6–6.0]; creatinine 149  $\mu\text{mol/L}$ ). Saline diuresis was initiated together with subcutaneous calcitonin, resulting in an initial biochemical response, with CCa decreasing to a nadir of 3.61 mmol/L. However, the CCa subsequently rebounded to 5.00 mmol/L. Hemodialysis was performed, followed by administration of subcutaneous denosumab 60 mg. Nonetheless, the CCa decreased only modestly to 4.28 mmol/L. She became increasingly drowsy, and her clinical course was further

complicated by aspiration pneumonia and lung collapse, leading to respiratory failure requiring intubation and inotropic support. Despite intensive care, additional sessions of hemodialysis and continuous renal replacement therapy, her CCa remained persistently above 4.0 mmol/L, peaking at 5.35 mmol/L. Due to her critical condition, imaging for lesion localization could not be performed. She eventually succumbed to her illness on day 10 of admission, before definitive surgery could be undertaken.

## CONCLUSION

This case highlights the potentially fatal course of hypercalcemic crisis secondary to primary hyperparathyroidism. The reported mortality rate is high, at around 60%. Early recognition and intensive management, including emergency parathyroidectomy in resistant cases, have been shown to be crucial in improving outcomes.

## EP\_A102

### CATASTROPHIC SKELETAL FRAGILITY IN TRANSFUSION-DEPENDENT HBE $\beta$ -THALASSEMIA: ENDOCRINE SIDEROSIS AND FAILURE OF ANTI-RESORPTIVE THERAPY

Ahmad Syahmi Yusof Zaki<sup>1,2</sup>, Nur Izat Muhamad<sup>2</sup>, Ezelea Elwina Walter Sandosam<sup>2</sup>, Wan Mohd Izani Wan Mohamed<sup>2</sup>

<sup>1</sup>Faculty of Medicine, University Sultan Zainal Abidin

<sup>2</sup>Department of Internal Medicine, School of Medical Sciences, University Science Malaysia

## INTRODUCTION

Skeletal disease in transfusion-dependent thalassemia is commonly attributed to reduced bone mineral density and managed with anti-resorptive therapy. However, chronic iron overload can induce progressive endocrine siderosis, disrupting anabolic pathways essential for bone homeostasis. This mechanism remains under-recognized and may underlie treatment failure in severe cases.

## CASE

We describe a 34-year-old female with transfusion-dependent HbE  $\beta$ -thalassemia, post-splenectomy, receiving regular transfusions and iron chelation, who sustained multiple pathological fractures following a trivial fall, including bilateral supracondylar femur fractures and a distal radius fracture. She had severe systemic iron overload (ferritin 2,621 ng/mL) complicated by hepatic cirrhosis, insulin-dependent diabetes, and hypogonadotropic hypogonadism. Bone mineral density assessment demonstrated severe osteoporosis (hip T-score -5.4) despite

prolonged bisphosphonate therapy, with prior vertebral compression fracture. Endocrine evaluation revealed multi-axis dysfunction, including gonadal failure and probable growth hormone deficiency, consistent with pituitary and peripheral endocrine siderosis.

#### CONCLUSION

This case demonstrates that skeletal fragility in transfusion-dependent thalassemia reflects an endocrine-driven failure of bone formation rather than isolated loss of bone mineral density. Iron overload-induced endocrine siderosis impairs osteoblast function and suppresses anabolic signaling, leading to profound skeletal vulnerability. The progression of osteoporosis despite anti-resorptive therapy highlights the limitation of conventional approaches and supports reframing thalassemia-associated bone disease as an endocrine disorder. Severe osteoporosis should prompt systematic endocrine evaluation, with early hormonal replacement and consideration of anabolic therapy to prevent catastrophic fractures and long-term disability.

## EP\_A103

### CRANIOFACIAL BROWN TUMOR SECONDARY TO PERSISTENT MULTIGLANDULAR PRIMARY HYPERPARATHYROIDISM: A REVERSIBLE COMPLICATION

Fathiyah Ramly<sup>1</sup>, Siti Sanaa Wan Azman<sup>1</sup>, Masliza Hanuni Mohd Ali<sup>1</sup>, Wan Mohd Hafez Wan Hamzah<sup>1</sup>

<sup>1</sup>Endocrinology Unit, Department of Internal Medicine, Hospital Sultanah Nur Zahirah

#### INTRODUCTION

Brown tumors, also known as osteitis fibrosa cystica, are focal bone lesions resulting from increased osteoclastic activity and fibroblastic proliferation. They represent a rare complication of uncontrolled hyperparathyroidism (HPT) and may affect any part of the skeleton, including craniofacial bones.

#### CASE

We report a case of a 31-year-old Malay female diagnosed with primary HPT secondary to multiglandular disease, who initially presented with symptomatic hypercalcemia. Biochemical evaluation revealed elevated corrected calcium (2.84 mmol/L; reference range 2.2–2.6 mmol/L), low phosphate (0.63 mmol/L; reference range 0.8–1.6 mmol/L), and markedly elevated serum intact parathyroid hormone (iPTH) (286 pg/mL; reference range 14.9–56.9 pg/mL). Ultrasound parathyroid showed a large right extrathyroidal lesion, most likely suggestive of parathyroid adenoma, where sestamibi scan suggested multiglandular parathyroid

adenomas with possible mediastinal involvement. She underwent exploratory parathyroidectomy on 19 June 2024, with excision of bilateral inferior parathyroid adenomas confirmed on histopathology. Despite surgery, she had persistent hypercalcemia (2.8–3.1 mmol/L) and rising iPTH levels (307 pg/mL on 24 June 2024, increasing to 413 pg/mL by 2 September 2024), consistent with persistent disease. Repeat imaging demonstrated hyperfunctioning parathyroid tissue in the anterior mediastinum. Subsequently, the patient developed progressive enlargement of the left upper gingiva associated with significant pain during mastication. Clinical and radiological evaluation revealed aggressive lesions with cortical expansion. Excisional biopsy of the gingival lesion confirmed the diagnosis of brown tumors involving the jaws. She later underwent a second parathyroidectomy with intraoperative parathyroid hormone monitoring at another centre. Postoperatively, normalization of serum calcium and iPTH levels was achieved, which led to marked clinical improvement and regression of the craniofacial brown tumor.

#### CONCLUSION

This case highlights that skeletal manifestations of HPT, including brown tumors, may regress following adequate biochemical control without additional local therapy. Early recognition and definitive surgical management of persistent or ectopic hyperfunctioning parathyroid tissue are essential to prevent progression and promote spontaneous bone healing processes.

## EP\_A104

### HOW ATYPICAL ADENOMA WORE THE MASK OF CARCINOMA IN A YOUNG MAN WITH SKELETAL CRISIS

Chee Kit Tee<sup>1</sup>, Yong Siang Ng<sup>1</sup>, Noor Hafis Md Tob<sup>1</sup>, Norhaliza Mohd Ali<sup>1</sup>

<sup>1</sup>Hospital Sultanah Aminah

#### INTRODUCTION

Atypical parathyroid adenoma is a rare cause of primary hyperparathyroidism and represents a borderline entity between benign adenoma and parathyroid carcinoma. Due to overlapping clinical, biochemical, and imaging features with carcinoma, diagnosis can be challenging and relies on histopathological evaluation to guide management and follow-up.

#### CASE

A 25-year-old male presented with a 3-month history of generalized bone pain and lethargy, with significant weight loss of 17 kg over 7 months. He denied headache, visual disturbance, or hypoglycemic episodes. There was no known

family history of endocrine tumors. Examination revealed a palpable right-sided neck mass. Biochemical evaluation showed severe primary hyperparathyroidism with marked hypercalcemia (4.12 mmol/L), hypophosphatemia (0.6 mmol/L), markedly elevated intact parathyroid hormone (137 pmol/L) and alkaline phosphatase (1,958 U/L). Thyroid function was normal. Neck ultrasound demonstrated a right TIRADS 4 lesion, and fine-needle aspiration suggested parathyroid tissue. Sestamibi scan localized a hyperfunctioning right inferior parathyroid gland measuring 2.1 × 1.7 × 3.3 cm. During admission, he sustained low-impact fragility fractures of the left femur and humerus after a fall. Preoperatively, management of hypercalcemia proved challenging. Despite aggressive medical therapy and intensive intravenous hydration with up to 6 liters of normal saline per day, serum calcium levels remained persistently exceeding 3.0 mmol/L. He underwent right hemithyroidectomy with excision of the right inferior parathyroid gland. The postoperative course was complicated by hungry bone syndrome, necessitating intravenous calcium gluconate infusion for 1 week. Histopathological examination confirmed the diagnosis of an atypical parathyroid adenoma. On postoperative follow-up, serum calcium and phosphate levels normalized while he remained on calcium carbonate and calcitriol supplementation.

### CONCLUSION

Severe primary hyperparathyroidism in young patients may indicate aggressive parathyroid pathology. Atypical parathyroid tumors can mimic carcinoma, and diagnosis requires histopathology with long-term follow-up due to uncertain malignant potential.

## EP\_A105

### BROWN TUMOR: RARE TODAY, BUT NEVER TO BE FORGOTTEN

Min Jing Choo<sup>1,2</sup> and Liang Wei Wong<sup>3</sup>

<sup>1</sup>Department of Internal Medicine, Hospital Kulim

<sup>2</sup>Department of Internal Medicine, Hospital Taiping

<sup>3</sup>Unit of Endocrinology, Endocrine Institute

### INTRODUCTION

Brown tumors are rare skeletal manifestations of primary hyperparathyroidism (PHPT), now seen in less than 5% of cases due to widely accessible biochemical screening. Despite being benign, they can mimic malignant bone lesions, making diagnosis challenging.

### CASE

A 45-year-old female presented with lethargy and hypercalcemia (corrected calcium 3.5 mmol/L) and was discharged after intravenous zoledronate. She returned 1 week later with an enlarging gingival mass present for 2 months but not previously disclosed, with a strong family history of malignancy. Examination revealed a 6 × 3 cm pedunculated lesion over the right alveolar ridge. Biochemistry showed persistent hypercalcemia (2.7–2.9 mmol/L), hypophosphatemia, and elevated alkaline phosphatase. Contrast-enhanced computed tomography of the neck demonstrated lytic mandibular and skull changes, raising suspicion for malignancy. Tumor markers and multiple myeloma screening were negative. Parathyroid hormone (PTH) later returned markedly elevated at 222.1 pg/mL (upper limit of normal 56.9 pg/mL), consistent with PHPT, alongside concomitant vitamin D deficiency. Excision biopsy of the mandibular lesion confirmed a brown tumor on histopathology. Following preoperative localization, she underwent left parathyroidectomy and recovered without hungry bone syndrome. Histology confirmed a parathyroid adenoma, and she has remained normocalcemic since.

Brown tumors arise from prolonged osteoclastic activity and represent advanced PHPT. Craniofacial involvement is rare, with the mandible affected in 4–5% of cases, and lesions may clinically and radiologically mimic primary bone tumors or metastases, creating diagnostic uncertainty. Hypercalcemia should be systematically investigated to determine the underlying cause, with early measurement of PTH to distinguish PTH-dependent from PTH-independent etiologies. Untreated brown tumors may result in bone pain, deformity, pathological fractures, and functional impairment, highlighting the importance of early detection and management.

### CONCLUSION

Brown tumors, although rare, remain an important differential diagnosis for lytic bone lesions in the context of hypercalcemia. Early measurement of PTH and careful clinical examination are essential to avoid misdiagnosis and prevent disease-related morbidity.

## EP\_A106

### A MULTIMODAL APPROACH USING CALCITONIN, DENOSUMAB, AND HEMODIALYSIS FOR THE MANAGEMENT OF REFRACTORY HYPERCALCEMIA IN MALIGNANCY

Nur Haziqah Baharum<sup>1</sup>, Mohd Hazriq A.<sup>1</sup>, Aimi Fadilah M.<sup>1</sup>, Nur Aini Eddy Warman<sup>1</sup>, Fatimah Zaherah MS<sup>1</sup>, Rohana A.G.<sup>1</sup>

<sup>1</sup>Endocrine Unit, Faculty of Medicine, University Technology MARA (UiTM)

#### INTRODUCTION

Severe hypercalcemia is a life-threatening metabolic emergency that necessitates prompt initiation of systemic therapy due to the risk of cardiac arrhythmias. It is frequently linked to squamous cell carcinoma through the production of parathyroid hormone-related protein, which mediates the development of humoral hypercalcemia of malignancy.

#### CASE

This is a case of a 38-year-old male who was diagnosed 1 year ago with locally advanced poorly differentiated basaloid squamous cell carcinoma of the lower anterior mandibular alveolus involving cortical, medullary bone, and perineural invasion. He underwent extensive tumor resection with reconstruction, tracheostomy, and bilateral neck dissection, followed by multiple revision surgeries for postoperative complications. He completed adjuvant chemoradiotherapy.

He presented with acute confusion without other systemic symptoms. His Glasgow Coma Scale was E4V4M5. Neurological and systemic examinations were unremarkable, and oral cavity assessment showed no evidence of recurrence.

Investigations revealed severe hypercalcemia (5.94 mmol/L) with normal phosphate (1.16 mmol/L) associated with shortened QTc. Other tests were unremarkable, with no evidence of infection, uremia, liver dysfunction, or alternative metabolic causes. Lumbar puncture was unremarkable. His parathyroid hormone level was suppressed at 0.50 pg/mL. Computed tomography brain showed no evidence of meningoencephalitis, hydrocephalus, cerebral oedema, or metastasis. Aggressive hydration was initiated alongside subcutaneous calcitonin, which was subsequently titrated. However, there was no clinical or biochemical improvement after 1 day, with persistent confusion and calcium remaining at 5.87 mmol/L. Subcutaneous denosumab was then administered, and hemodialysis was initiated on alternate days due to refractory hypercalcemia. This resulted in

improvement of calcium levels to 3.2–3.6 mmol/L and resolution of confusion.

#### CONCLUSION

Refractory hypercalcemia may represent a late manifestation of advanced squamous cell carcinoma and is an ominous prognostic indicator, necessitating prompt evaluation and oncologic management.

## EP\_A107

### THE PLACENTA AS A PARATHYROID: PREGNANCY-INDUCED NORMALIZATION OF REFRACTORY POSTSURGICAL HYPOPARATHYROIDISM

Dinehs Rao<sup>1</sup>, Siti Sanaa Wan Azman<sup>1</sup>, Dorothy Maria Anthony Bernard, Foo Siew Hui<sup>1</sup>

<sup>1</sup>Endocrine Unit, Medical Department, Hospital Selayang

#### INTRODUCTION

Permanent hypoparathyroidism is a recognized complication of total thyroidectomy, with an estimated incidence of 10.47%. Standard treatment involves supplementation with calcium and activated vitamin D. However, some patients remain refractory to conventional therapy and fail to achieve normocalcemia. During pregnancy, significant physiological changes occur in calcium-regulating hormones. Notably, the placenta increases the production of parathyroid hormone-related peptide (PTHrP), which acts as a calcitropic hormone, mimicking the effects of parathyroid hormone.

#### CASE

A 38-year-old female with a history of total thyroidectomy 14 years ago for follicular thyroid carcinoma presented with permanent hypoparathyroidism. Her condition was refractory to high-dose replacement therapy, which included calcium carbonate 3 g BD, alfacalcidol 4 mcg ON, calcitriol 1 mcg BD, and cholecalciferol 100,000 IU OD. Despite compliance, her serum calcium levels fluctuated between 1.7 and 1.93 mmol/L, necessitating intermittent intravenous calcium infusions. Laboratory investigations showed a phosphate level of 1.63 mmol/L and 24-hour urine calcium of 4.81 mmol/L. Her thyroid function remained stable on levothyroxine 150 mcg daily (T4: 12.0 pmol/L; thyroid-stimulating hormone: 2.93 mIU/L). While off-label use of teriparatide was being considered, she became pregnant. As the pregnancy progressed, her calcium levels stabilized. Calcitriol was discontinued at 26 weeks' gestation when her calcium reached 2.5 mmol/L. By 30 weeks, the alfacalcidol dose was reduced to 3.5 mcg daily, with cholecalciferol dosing reduced to 50,000 IU OD. Her corrected calcium levels remained between

2.4 and 2.6 mmol/L until delivery. Similar reduction in supplementation requirements was noted during her previous pregnancy.

#### CONCLUSION

Elevated PTHrP during pregnancy likely contributed to improved calcium homeostasis by increasing maternal bone resorption and enhancing placental calcium transfer. This case underscores the necessity of individualized, dynamic adjustments to calcium and vitamin D therapy based on rigorous biochemical monitoring for pregnant patients with hypoparathyroidism.

## EP\_A108

### SEVERE TOPHACEOUS GOUT CAUSING PTH-INDEPENDENT HYPERCALCEMIA: AN UNCOMMON ASSOCIATION

Hu Chong Siang<sup>1</sup>, Kuan Yueh Chien<sup>1</sup>, Lee Ho Mi<sup>1</sup>,  
Cheong Yaw Kiet<sup>2</sup>

<sup>1</sup>Miri Hospital

<sup>2</sup>Sarawak General Hospital

#### INTRODUCTION

Chronic tophaceous gout is a rare cause of parathyroid hormone (PTH)-independent hypercalcemia. This is due to increased 1-alpha hydroxylase activity within granulomatous inflammation surrounding gouty tophi, resulting in excess calcitriol production. In advanced disease, immobilization from pain and joint deformity may further exacerbate hypercalcemia due to immobilization-related bone resorption, leading to clinically significant symptoms and complications.

#### CASE

A 59-year-old male with chronic tophaceous gout complicated with CKD and nephrocalcinosis was referred for inpatient evaluation of hypercalcemia. He had an episode of acute pancreatitis attributed to hypercalcemia 1 month prior. Serum calcium levels have risen progressively over the preceding year, from 2.48 mmol/L (reference 2.0–2.65) to 3.17 mmol/L.

His gout was poorly controlled with uric acid levels ranging 641–709 umol/L, with extensive tophi over the upper and lower limbs and gluteal regions. He had been maintained on low-dose allopurinol 150 mg/day for 2 years. Functionally, he was largely bedbound and wheelchair-dependent.

On admission, corrected calcium was 3.48 mmol/L with suppressed intact parathyroid hormone (<0.6 pmol/L) consistent with PTH-independent hypercalcemia. Malignancy and myeloma workup, including tumor markers,

was unremarkable. Serum phosphate (0.9 mmol/L) and alkaline phosphatase (152 IU/L) were normal.

Hypercalcemia persisted despite intravenous hydration and calcitonin. Low-dose prednisolone was then initiated, followed by pamidronate, resulting in normalization of corrected calcium to 2.17 mmol/L. He remained normocalcemic while on tapering prednisolone for a month. However, calcium rebounded months after cessation.

Gradual escalation of allopurinol to 900 mg/day improves uric acid levels to 389–429 umol/L with better functional status (standing unsupported briefly and mobilizing with assistance). However, calcium remains moderately elevated 2.65–2.85 mmol/L.

#### CONCLUSION

This case highlights severe tophaceous gout as a rare but significant cause of PTH-independent hypercalcemia, in which glucocorticoids can be effective in treating refractory hypercalcemia. It also underscores the importance of addressing the underlying disease through optimization of urate-lowering therapy and functional rehabilitation.

## EP\_A109

### NEITHER A FRIEND NOR A FOE: AN UNUSUAL CASE OF SEVERE SYMPTOMATIC HYPERCALCEMIA SECONDARY TO ATYPICAL PARATHYROID ADENOMA

Wye Hong Leong<sup>1</sup>, Qing Ci Goh<sup>1</sup>, Vanusha Devaraja Pillai<sup>1</sup>, Siow Ping Lee<sup>1</sup>, Maryam Ahmad Sharifuddin<sup>2</sup>

<sup>1</sup>Endocrinology Unit, Department of Medicine, Hospital Melaka

<sup>2</sup>Department of Pathology, Hospital Melaka

#### INTRODUCTION

Atypical parathyroid adenoma (APA) constitutes approximately 0.5–4.0% of all cases of primary hyperparathyroidism (pHPT). Here, we report a case of APA presenting with severe hypercalcemia, complicated with renal impairment, bilateral medullary nephrocalcinosis, and multiple fragility fractures.

#### CASE

A 45-year-old male initially presented with a 6-month history of constipation, polyuria, lethargy, bone pain, and difficulty in initiating micturition. Laboratory investigations revealed impaired renal function with an estimated glomerular filtration rate of 41.4 mL/min, severe hypercalcemia (4.07 mmol/L), and an elevated intact parathyroid hormone (iPTH) level of 104.0 pmol/L (reference range: 1.58–6.03 pmol/L), confirming the diagnosis of pHPT. He was also found to have vitamin D

deficiency, with a serum total 25-hydroxyvitamin D level of 46 nmol/L.

Ultrasound of the abdomen demonstrated bilateral medullary nephrocalcinosis, while neck ultrasound and Tc-99 m sestamibi parathyroid scintigraphy revealed a concordant lesion in the posterior aspect of the left thyroid lobe, suggestive of a parathyroid adenoma.

He returned 3 months later with closed fractures of the right subtrochanteric femur and the right humerus following a fall from standing height.

In view of persistent hypercalcemia despite hyperhydration and treatment with zoledronic acid, subcutaneous denosumab (60 mg) was administered, resulting in an improvement in serum calcium levels. A left inferior parathyroidectomy was then performed concurrently with internal fixation of the right femur. The surgery was uneventful. Histopathological examination confirmed an atypical parathyroid adenoma. Postoperatively, the serum calcium and iPTH levels normalized, and the patient remained asymptomatic and normocalcemic during regular follow-up.

#### CONCLUSION

APA remains a diagnostic and therapeutic challenge due to its clinical, biochemical, and histopathological features of equivocal malignancy. Surgical resection remains the mainstay of management of APA, and long-term surveillance is essential in view of its uncertain malignant potential and risk of recurrence.

## EP\_A110

### BEYOND MTC: CLINICAL MANIFESTATIONS OF MEN2A IN HEREDITARY MEDULLARY THYROID CANCER PATIENTS IN A TERTIARY CENTRE

Qin Zhi Lee<sup>1</sup>, Chin Voon Tong<sup>1</sup>, Raja Nurazni Raja Azwan<sup>1</sup>, Zanariah Hussein<sup>1</sup>

<sup>1</sup>Endocrinology Unit, Department of Medicine, Hospital Putrajaya

#### INTRODUCTION

Medullary thyroid carcinoma (MTC) has the highest familial predisposition syndrome of any hereditary cancer syndrome. The most common subtype of hereditary MTC is multiple endocrine neoplasia type 2A (MEN2A), which is an autosomal dominant syndrome characterized by MTC, pheochromocytoma, and primary hyperparathyroidism (HPP). This study evaluates the genotypic distribution, phenotypic manifestations, and clinical characteristics of MEN2A within a retrospective MTC cohort.

#### METHODOLOGY

A retrospective audit of MTC patients was conducted at a tertiary centre. Patients with clinically or genetically confirmed hereditary MTC were identified for further analysis. Electronic medical records were reviewed for demographic data, RET germline mutations, occurrence of pheochromocytoma and HPP, laterality of disease, and documented surgical interventions.

#### RESULTS

In all, 18 patients (31.6%) were classified as hereditary from a cohort of 57 patients with a median age at diagnosis of 29.2 years. Among genetically confirmed cases with available variant data ( $n = 11$ ), mutations predominantly involved exon 11 codon 634 (90.9%,  $n = 10$ ), including p.Cys634Arg ( $n = 4$ ), p.Cys634Tyr, and p.Cys634Ser, with one codon 618 mutation.

Extrathyroidal manifestations were common. Pheochromocytoma occurred in 50.0% ( $n = 9$ ), of which 77.8% ( $n = 7$ ) were bilateral. Most patients underwent adrenalectomy, including bilateral procedures in those with bilateral disease. HPP was identified in 44.4% ( $n = 8$ ), managed with selective parathyroidectomy. Both pheochromocytoma and HPP were present in 22.2% ( $n = 4$ ), while isolated MTC occurred in 27.8% ( $n = 5$ ).

#### CONCLUSION

Hereditary MTC in our cohort is predominantly associated with high-risk codon 634 RET mutations and demonstrates substantial penetrance of pheochromocytoma and HPP. The high frequency of bilateral adrenal involvement highlights the importance of systematic biochemical surveillance and appropriately timed surgical management in MEN2A. A nationwide registry would be timely.

## EP\_A111

### SAFETY AND CLINICAL OUTCOMES OF RAMADAN FASTING IN PATIENTS WITH ARGININE VASOPRESSIN DEFICIENCY: A RETROSPECTIVE COHORT STUDY

Suprhamanyam Evali<sup>1</sup>, Nur Arina binti Mohammed Zain<sup>1</sup>, Nao Chang Zhao<sup>1</sup>, Noor Ashikin binti Ismail<sup>1</sup>, Dineash Kumar Kannesan<sup>1</sup>, Nurain binti Mohd Noor<sup>1</sup>

<sup>1</sup>Endocrine Unit, Hospital Putrajaya

#### INTRODUCTION

Arginine vasopressin deficiency (AVP-D) is characterized by impaired antidiuretic hormone secretion, leading to polyuria and a significant dehydration risk. The British Islamic Medical Association classifies AVP-D as a "very high risk" condition, advising against Ramadan fasting.

However, many patients fast due to religious convictions, creating a gap between clinical guidelines and patient practice. This study evaluates the clinical outcomes and safety of fasting in this population.

#### METHODOLOGY

A single-centre retrospective cohort study was conducted at Hospital Putrajaya. We included adults with permanent AVP-D on desmopressin therapy for more than 1 year who fasted during Ramadan 2025. Data were extracted from electronic medical records and patient consultations. Primary outcomes included hospitalization rates, dehydration symptoms, and desmopressin dose adjustments.

#### RESULTS

Of the 43 patients (mean age  $42.4 \pm 15.28$  years; 53.5% female), 27 successfully fasted for a mean of  $27.6 \pm 6.56$  days. Pre-Ramadan counseling was documented in only 55.8% of cases. While 25.9% of participants experienced dehydration symptoms (thirst, dizziness), and 22.2% broke their fast for safety reasons, there were no hospitalizations. None of the patients required additional desmopressin dose adjustments. Most patients (66.7%) maintained twice-daily desmopressin dosing (Sahur and Iftar). Anterior pituitary deficiencies were present in 70.3% of the cohort.

#### CONCLUSION

Despite being classified as very high risk, many AVP-D patients safely complete Ramadan fasting without severe adverse events. However, the high rate of dehydration symptoms and the significant gap in pre-Ramadan counseling (44.2% un-counseled) highlight the need for structured clinical reviews 4–6 weeks prior to Ramadan to optimize hydration and dosing.

## EP\_A112

### A CASE SERIES OF CARCINOID SYNDROME: A SINGLE-CENTRE EXPERIENCE

Jie En Tan<sup>1</sup> and Noor Ashikin Ismail<sup>1</sup>

<sup>1</sup>Endocrine Institute, Hospital Putrajaya

#### INTRODUCTION

Carcinoid syndrome is a hormonal complication accompanying neuroendocrine tumors (NETs) and is defined by chronic diarrhea and/or flushing in the presence of systemically elevated levels of serotonin or its metabolite 5-hydroxyindolacetic acid. The condition is often diagnosed late because of nonspecific symptoms, and many patients present with metastatic disease. This was a retrospective review of patients with carcinoid syndrome who were

followed up at the Endocrine Clinic, Putrajaya Hospital, up to date.

#### CASE

Three women aged between 30 and 40 years were diagnosed with carcinoid syndrome secondary to metastatic NETs. Two cases were diagnosed before and during their pregnancies, resulting in one successful pregnancy while another required termination of pregnancy. All patients presented with symptomatic disease, predominantly flushing and chronic diarrhea and abdominal distension, leading to the diagnosis within the same year to as long as a decade after symptomatology. All were found to have extensive liver and nodal metastases at diagnosis. Liver biopsy showed tumor grade 1 in two of the cases, while the case with tumor grade 2 exhibited an aggressive disease course with carcinoid heart disease and bone metastases. None were amenable to surgery. Somatostatin analogues (SSAs) were the mainstay of treatment, administered every 2–4 weeks and titrated according to clinical response. Cytotoxic chemotherapy and bone-targeted agent were given for the case with rapid disease progression and skeletal-related event. Somatostatin analogue radiolabeled peptide therapy (PRRT) was reserved for symptom control in progressive disease refractory to first-line SSAs, after assessment with PET-Ga68 DOTATATE imaging.

#### CONCLUSION

This case series highlights delayed diagnosis and advanced presentation due to its nonspecific symptoms. The occurrence in young women, including during pregnancy, underscores the complexity of management and the need for individualized multidisciplinary care, with somatostatin analogues, systemic therapy, and PRRT playing key roles in symptoms control and disease progression.

## EP\_A113

### AORTIC DISSECTION: A RARE COMPLICATION IN ACROMEGALY

Zanariah Hussein<sup>1</sup>, Wan Faizal Wan Rahimi Shah<sup>2</sup>, Hamdan Leman<sup>2</sup>

<sup>1</sup>Endocrine Institute, Hospital Putrajaya

<sup>2</sup>Cardiac Vascular Sentral Kuala Lumpur (CVSKL)

#### INTRODUCTION

Aortic root dilatation is not uncommon in acromegaly as a result of persistent growth hormone (GH) excess, causing degenerative changes in the aortic wall. Acute and extensive aortic dissection is rare and a potentially fatal complication.

## CASE

We report a 51-year-old male with acromegaly due to a GH-secreting pituitary macroadenoma with parasellar extension, diagnosed in 2014. As primary surgical therapy was not recommended, he received medical therapy, initially with monthly lanreotide depot injections and subsequently switched to pasireotide LAR for 7 years. Following tumor size reduction with medical therapy, he underwent transphenoidal surgery followed by stereotactic radiotherapy for residual tumor. Despite multimodal intervention, growth hormone and insulin-like growth factor 1 levels were persistently mildly elevated and required combination medical therapy along with multiple hormone replacement therapies with thyroxine, hydrocortisone, and testosterone for panhypopituitarism. Both hypertension and diabetes were well controlled on treatment.

In December 2025, he presented with sudden, severe central chest pain and rapidly progressive left lower limb weakness. Imaging studies with computed tomography aortography and lower limb angiogram detected an Extensive Type A Aortic Dissection with entry point proximal to the origin of the coronary arteries, extending to the right common carotid, internal and external carotid arteries, and distally into the left common iliac, proximal internal and external iliac arteries, which were completely thrombosed.

He underwent emergency aortic dissection repair with hemi-aortic arch replacement of the ascending aorta and repair of perforated right coronary sinus wall, with two vessel CABG and lower limb femoral-femoral bypass. Postoperatively, he required prolonged ventilation and intensive care unit care due to multiple complications: pericardial and pleural effusions, repeated left lower limb thrombosis requiring left popliteal embolectomy, and embolic stroke of the right internal carotid artery and posterior cerebral artery with subsequent hemorrhagic transformation. He continued to recover well with intensive physiotherapy and acupuncture and is now able to ambulate independently.

## CONCLUSION

Cardiovascular surveillance with regular echocardiogram and specific monitoring for aortic dilatation is important in uncontrolled acromegaly. Consideration for surgical intervention in selected cases may be necessary to prevent acute dissection.

## EP\_A114

### INSULINOMA IN PREGNANCY PRESENTING WITH RECURRENT HYPOGLYCEMIA: DIAGNOSTIC CHALLENGES, MULTIDISCIPLINARY MANAGEMENT, AND THERAPEUTIC DILEMMAS

Abdullah Faiz Zaihan<sup>1</sup>, Srinivas Siwalingam<sup>2</sup>,  
Noor Hayatul Akmal Noralam<sup>3</sup>, Kaeshaelya  
Thiruchelvam<sup>4</sup>, Chia Siang Kow<sup>4</sup>

<sup>1</sup>Department of Pharmacy, Hospital Shah Alam

<sup>2</sup>Department of Radiology, Hospital Shah Alam

<sup>3</sup>Department of Radiology, Hospital Sultan Abdul Aziz Shah

<sup>4</sup>Faculty of Pharmacy, IMU University

## INTRODUCTION

Insulinoma during pregnancy is exceedingly rare, with fewer than 30 cases reported worldwide. Diagnosis is often delayed due to overlapping physiological and gestational symptoms, posing significant risks to both mother and fetus.

## CASE

We report a case of a 36-year-old G4P2 + 1 female presenting at 7 weeks' gestation with recurrent symptomatic hypoglycemia initially suspected due to poor oral intake. She returned at 12 weeks with persistent neuroglycopenic symptoms and weight loss. Biochemical evaluation demonstrated inappropriately non-suppressed insulin and C-peptide levels during hypoglycemia, raising suspicion for endogenous hyperinsulinemia. Imaging with magnetic resonance imaging identified a 2.3 × 2.5 cm pancreatic lesion consistent with insulinoma.

A multidisciplinary team (MDT) approach involving Internal Medicine, Endocrinology, Obstetrics and Gynecology (Maternal-Fetal Medicine), Hepatobiliary Surgery, and Radiology guided management. Due to concerns regarding surgical and ablative risks during pregnancy, medical therapy with octreotide was initiated, achieving partial glycemic control. The pregnancy was complicated by fetal growth restriction, necessitating delivery at 34 weeks.

Postpartum, the patient underwent endoscopic ultrasound-guided radiofrequency ablation (EUS-RFA), requiring two sessions before achieving glycemic stabilization.

## CONCLUSION

This case highlights the diagnostic challenges of insulinoma in pregnancy and underscores the importance of MDT-guided individualized management. It also illustrates the limitations of EUS-RFA and medical therapy, particularly in larger tumors, and raises important considerations regarding fetal outcomes.

## EP\_A115

### BALANCING DISEASE CONTROL AND METABOLIC HARM: A CASE OF IgG4-RELATED HYPOPHYSITIS

Asma' Mohd Nazlee<sup>1</sup>, Dorothy Maria Anthony Bernard<sup>1</sup>, Siti Sanaa Wan Azman<sup>1</sup>, Siew Hui Foo<sup>1</sup>

<sup>1</sup>Hospital Selayang

#### INTRODUCTION

Immunoglobulin G4-related hypophysitis (IgG4-RH) is a rare fibro-inflammatory disorder affecting the pituitary gland. Glucocorticoids remain the first-line therapy, but their use may be complicated in patients with significant metabolic comorbidities. We report a case of suspected IgG4-RH presenting with hyperosmolar hyperglycemic state (HHS), highlighting the challenges of balancing disease control against glucocorticoid metabolic toxicity adverse effects.

#### CASE

A 32-year-old female with obesity and newly diagnosed diabetes mellitus was admitted with HHS. Prior to admission, she reported weight fluctuations, episodic headaches, progressive visual disturbance, and secondary amenorrhea. Following resolution of HHS, persistent polyuria of 10–16 L/day prompted further evaluation and led to a diagnosis of arginine vasopressin deficiency. Anterior pituitary hormonal work-up revealed hypogonadotropic hypogonadism. Pituitary magnetic resonance imaging demonstrated infundibular thickening measuring 0.5 cm, with concomitant marked bilateral parotid enlargement. Serum IgG4 was elevated at 2.26 g/L (0.63–2.01), raising strong suspicion for IgG4-RH with systemic involvement. Histopathological confirmation from the parotid gland biopsy was consistent with sialadenosis.

She was commenced on sublingual desmopressin and cyclical sex hormone replacement therapy. Given the provisional diagnosis of IgG4-RH, oral prednisolone 40 mg daily was initiated as a reduced induction regimen. However, treatment was poorly tolerated, with rapid weight gain from 93 to 100 kg and worsening glycemic control. Prednisolone was therefore tapered rapidly to 10 mg daily. Repeat imaging demonstrated interval improvement in infundibular thickening, but no functional endocrine recovery was observed.

#### CONCLUSION

This case illustrates the therapeutic challenge of managing IgG4-RH in the setting of pre-existing metabolic syndrome. Although glucocorticoids are effective for induction, their metabolic adverse effects may significantly restrict

treatment tolerability. Early consideration of steroid-sparing agents, such as rituximab or azathioprine, may be important to achieve remission while minimizing glucocorticoid-related adverse effects.

## EP\_A116

### A DIAGNOSTIC DILEMMA IN ECTOPIC ACTH SYNDROME: WHEN BIOCHEMISTRY AND IMAGING CONFLICT

Ioanna Ting Yung Sim<sup>1,2</sup>, Florence Hui Sieng Tan<sup>1</sup>, Sing Yee Sim<sup>1,2</sup>, Pei Lin Chan<sup>1</sup>, Ee Wen Loh<sup>1</sup>

<sup>1</sup>Endocrine Unit, Sarawak General Hospital

<sup>2</sup>Universiti Malaysia Sarawak (UNIMAS)

#### INTRODUCTION

Ectopic ACTH secretion (EAS) is a rare cause of Cushing's syndrome, accounting for 5–15% of cases. Pulmonary neuroendocrine tumors are the most frequent cause. However, primary tumor localization remains a significant diagnostic challenge, delaying effective treatment.

#### CASE

A 59-year-old female with diabetes mellitus presented with refractory hypertension and hypokalemia. Initial laboratory findings revealed a baseline cortisol of 1,164 nmol/L and morning adrenocorticotropic hormone (ACTH) of 19.5 pmol/L (normal <10.2 pmol/L), with an overnight dexamethasone suppression test cortisol of 624 nmol/L. Pituitary magnetic resonance imaging (MRI) and computed tomography (CT) scans of the thorax, abdomen, and pelvis were initially unremarkable. A PET scan identified mild hypermetabolism in the left adrenal gland and gastrointestinal tract, though colonoscopy revealed only chronic colitis. An intravenous desmopressin stimulation test demonstrated a 181% rise in ACTH and a 35% rise in cortisol, pointing toward pituitary Cushing's. However, repeat pituitary MRI remained normal.

A high-dose dexamethasone suppression test showed approximately 34% cortisol suppression (cortisol 1,128 nmol/L to 745 nmol/L), suggesting ectopic Cushing's syndrome. Bilateral inferior petrosal sinus sampling demonstrated a peak central-to-peripheral ACTH ratio of 1.8 on the right and 1.6 on the left, pointing toward ectopic Cushing's.

Localization with DOTATATE PET-CT identified a 7 × 9 × 8 mm nodule in the right middle lobe. A wedge resection was performed. Histopathology confirmed a typical carcinoid tumor with clear resection margins. Immunohistochemistry revealed tumor cells positive for CK AE1/

AE3, synaptophysin, chromogranin, and INSM-1, with weak positivity for ACTH. The latest 8 am cortisol was 117 nmol/L and ACTH 1.74 pmol/L, confirming biochemical cure. Hypokalemia resolved, with improvement in her metabolic profile.

#### CONCLUSION

This case highlights the diagnostic complexities of EAS, particularly when initial imaging is inconclusive and biochemical tests yield conflicting results. Timely, precise localization of the causative tumor is crucial for successful surgical intervention and to prevent severe complications of hypercortisolism, thereby improving patient outcomes.

## EP\_A117

### FROM HYPERNATREMIA TO HYPONATREMIA: SEQUENTIAL CENTRAL AVP DEFICIENCY (AVP-D) AND CEREBRAL SALT WASTING (CSW) IN TUBERCULOUS MENINGITIS (TBM)

Chia Yin Por<sup>1</sup>, Ee Wen Loh<sup>1</sup>, Pei Lin Chan<sup>1</sup>, Florence Hui Sieng Tan<sup>1</sup>

<sup>1</sup>Endocrinology Unit, Department of Medicine, Sarawak General Hospital

#### INTRODUCTION

Electrolyte imbalance is common in central nervous system infections. Arginine vasopressin deficiency (AVP-D), Cerebral Salt Wasting (CSW), and Syndrome of Inappropriate Antidiuretic Hormone secretion (SIADH) are important etiologies that can cause opposing extremes of serum sodium, posing diagnostic and therapeutic challenges. We report a rare case of transient central AVP-D followed by CSW secondary to tuberculous meningitis (TBM).

#### CASE

An 18-year-old female presented with a 1-month history of fever, reduced responsiveness, and visual hallucinations. Her Glasgow Coma Scale was E4V1M4 with neck stiffness and upper motor neuron signs. Initial investigations revealed severe hyponatremia (119 mmol/L) and communicating hydrocephalus with third ventricle ballooning on brain imaging. Coupled with a positive tuberculosis contact, anti-tuberculous therapy was initiated for probable TBM alongside 3% saline correction prior to insertion of external ventricular drain (EVD). Her condition deteriorated on day 5, requiring intubation for aspiration pneumonia. Repeated imaging showed worsening hydrocephalus, necessitating EVD revision. She subsequently developed polyuria (urine output [UO] 150–300 mLs/hour), with biochemical findings consistent with AVP-D (serum sodium 154 mmol/L; urine

osmolality 96 mOsm/kg; urine sodium <20 mmol/L). Intravenous desmopressin 1 mcg was administered, and UO reduced to 30 mLs/hour. However, polyuria recurred on Day 9, accompanied by tachycardia, hypotension, and a rapid decline in serum sodium to 120 mmol/L. Diagnosis of CSW was established (urine sodium 204 mmol/L; urine osmolality 470 mOsm/kg). Oral fludrocortisone was initiated and titrated to 0.4 mg daily to maintain serum sodium >130 mmol/L. Due to persistent hydrocephalus, right ventriculoperitoneal shunt was inserted on Day 22, after which her UO gradually decreased, allowing tapering of fludrocortisone. She remains on fludrocortisone 0.1 mg daily with ongoing rehabilitation.

#### CONCLUSION

TBM can be complicated by SIADH, AVP-D, or CSW. Concurrent AVP-D and CSW have not been reported. This case highlights the dynamic electrolyte disturbances in TBM which may lead to diagnostic confusion and therapeutic error. Early recognition and tailored therapy, alongside definitive management to reduce intracranial pressure, are essential for optimal outcomes.

## EP\_A118

### MASKING ANDROPAUSE BY A FUNCTIONING GONADOTROPH MACROADENOMA: DISCORDANT CLINICAL AND HORMONAL FINDINGS

Niken Febriharsari<sup>1</sup>, Mirza Adhyatma<sup>1</sup>, Hemi Sinorita<sup>2</sup>

<sup>1</sup>Endocrinology, Metabolism, and Diabetes Fellowship Program, Gadjah Mada University, Dr. Sardjito General Hospital

<sup>2</sup>Division of Endocrinology, Metabolism and Diabetes, Department of Internal Medicine, Gadjah Mada University, Dr. Sardjito General Hospital

#### INTRODUCTION

Functioning gonadotroph adenomas (FGPAs) in males are rare and typically present with macroorchidism. In elderly patients, the presentation can be confounding. This case illustrates a unique scenario where a pituitary tumor masked the physiological decline of testosterone, maintaining the patient's stamina despite Introduction testicular involution.

#### CASE

A 65-year-old male was referred for a pituitary macroadenoma (10.7 × 10.6 × 11.4 mm) following progressive headaches. Remarkably, the patient denied symptoms of andropause; his stamina, mood, and libido were well-preserved. Investigations revealed elevated follicle-stimulating hormone (15.42 mIU/mL) and luteinizing

hormone (12.1 mIU/mL) with normal testosterone levels. Scrotal ultrasound showed bilateral testicular involution (right: 8.66 mL, left: 7.21 mL), contradicting the expected macroorchidism of FGPA. Although the patient felt his vision was normal, a confrontation test revealed temporal visual field defects, indicating chiasmatic compression. This case presents a striking clinical discordance where tumor-induced gonadotropin hypersecretion provided a supra-physiological drive to the involuting testes, maintaining testosterone levels and masking andropause. The primary indication for transsphenoidal surgery is the introduction of evidence of visual field defects. However, removing the adenoma will abruptly eliminate this “hormonal drive.” Postoperative management will focus on rigorous hormonal monitoring. Testosterone replacement therapy is not immediately indicated; rather, it will be carefully planned only if postoperative evaluations demonstrate a significant hormonal decline accompanied by symptomatic hypogonadism. This tailored approach ensures that the benefits of intervention outweigh the potential risks in an elderly patient.

#### CONCLUSION

In elderly patients, FGPA can mask age-related hormonal decline. In this case, clinicians must treat the patient, not just the tumor. Anticipating a potential decline in postoperative stamina is as crucial as the surgery itself. Comprehensive hormonal evaluation and a personalized approach to therapy are essential to preserve quality of life after the “masking” effect is removed.

## EP\_A119

### WHEN HYPERPROLACTINEMIA FAILS TO SUPPRESS: THE SILENT GONADOTROPH IN A PITUITARY MACROADENOMA

Min Jing Choo<sup>1</sup> and Liang Wei Wong<sup>2</sup>

<sup>1</sup>Department of Internal Medicine, Hospital Taiping

<sup>2</sup>Endocrine Institute, Hospital Putrajaya

#### INTRODUCTION

Pituitary macroadenomas may present with mass effects, hypopituitarism, or hormone hypersecretion. Hyperprolactinemia, resulting from a prolactin-secreting tumor or stalk compression, typically suppresses gonadotropins. Thus, elevated follicle-stimulating hormone (FSH) and luteinizing hormone (LH) with low testosterone in this context are unusual. We report a macroprolactinoma with a clinically non-functioning gonadotroph adenoma.

#### CASE

A 69-year-old male presented with acute giddiness and headache while in Vietnam. He reported reduced libido but no visual symptoms or galactorrhea. Examination showed no neurological deficits, normal visual fields, and secondary sexual characteristics; bilateral testes volume of 25 mL. Magnetic resonance imaging (MRI) brain revealed a 1.6 × 2.2 × 2.1 cm pituitary macroadenoma compressing the optic chiasm and pituitary stalk.

Initial pituitary evaluation demonstrated hyperprolactinemia (prolactin >200 µg/L; normal 2.4–13.1), central hypothyroidism (T4 6.8 pmol/L [7.8–14.4], thyroid-stimulating hormone 2.3 mIU/L [0.38–5.3]), elevated FSH (21.5 IU/L [1.2–19.2]) and LH (191 IU/L [1.24–8.62]), low testosterone (8.88 nmol/L), normal insulin-like growth factor 1 (IGF-1) (68 µg/L [46.5–191.9]), and cortisol 237 nmol/L. Cabergoline was initiated at 0.25 mg twice weekly and titrated to 1 mg twice weekly over 4 months, alongside levothyroxine 25 µg daily.

Repeated MRI brain 2 months after cabergoline initiation showed a persistent macroadenoma (1.7 × 2.2 × 2.2 cm) with bilateral cavernous sinus extension. Prolactin decreased to <170 µg/L, central hypothyroidism persisted; levothyroxine was optimized, and hydrocortisone was initiated.

At the 5-month follow-up, prolactin further improved to 57 µg/L. Central hypothyroidism and borderline adrenal function persisted, requiring continued replacement therapy. Testosterone remained low-normal (10.2 nmol/L) despite elevated FSH (15.4 IU/L) and LH (92 IU/L). Follow-up MRI and hormonal reassessment were planned in May 2026.

#### CONCLUSION

Profoundly elevated prolactin level >200 µg/L and response to cabergoline reflect true prolactinoma rather than stalk effect. Persistently low testosterone with discordant high FSH/LH suggests a non-functioning gonadotroph component producing biologically inactive gonadotropins. Definitive diagnosis requires histopathological confirmation, while serial biochemical and radiological follow-up guides management and clarifies tumor subtype.

## EP\_A120

### PITUITARY STALK INTERRUPTION SYNDROME DIAGNOSED IN THE FOURTH DECADE: A RARE CAUSE OF PATHOLOGICAL FRACTURE IN ADULTHOOD

Muhammad Atif Sadiqqi bin Nor Azlan<sup>1</sup> and Amalina Haydar Ali Tajuddin<sup>2</sup>

<sup>1</sup>Department of Internal Medicine, Sultan Ahmad Shah Medical Centre

<sup>2</sup>Department of Internal Medicine, Kulliyah of Medicine

#### INTRODUCTION

Pituitary stalk interruption syndrome (PSIS) is a rare congenital disorder characterized by the neuroradiological triad of an absent or interrupted pituitary stalk, ectopic posterior pituitary, and anterior pituitary hypoplasia. It is typically diagnosed in infancy or childhood due to growth failure or delayed puberty. Diagnosis in adulthood is uncommon and may occur after decades of untreated hypopituitarism.

#### CASE

A 34-year-old Malay male with underlying physical and intellectual disability presented after a mechanical fall resulting in left slipped capital femoral epiphysis, an unusual pathological fracture in adulthood. Clinical examination revealed marked infantilism with complete absence of secondary sexual characteristics (Tanner stage I). Laboratory evaluation demonstrated combined pituitary hormone deficiency, including severe central hypothyroidism, profound hypogonadotropic hypogonadism, and central adrenal insufficiency. Growth hormone and insulin-like growth factor 1 were undetectable, while prolactin was mildly elevated, consistent with pituitary stalk disruption due to loss of hypothalamic dopaminergic inhibition. Bone age assessment showed severe delay, corresponding to 15 years. Pituitary magnetic resonance imaging demonstrated the classical PSIS triad: anterior pituitary hypoplasia with partial empty sella, a high T1 signal nodule at the median eminence representing ectopic posterior pituitary, and non-visualization of the infundibulum, consistent with an absent pituitary stalk. Birth history revealed premature breech delivery, a recognized perinatal risk factor. The patient was commenced on hormone replacement therapy, including levothyroxine, hydrocortisone, testosterone undecanoate, and calcium-vitamin D supplementation.

#### CONCLUSION

This case illustrates that PSIS may remain undiagnosed into adulthood, leading to severe consequences of long-standing hypopituitarism such as osteoporosis and pathological

fractures. Clinicians should consider hypopituitarism in adults presenting with unexplained fractures and delayed sexual maturation, particularly when supported by a suggestive perinatal history.

## EP\_A121

### A SILENT INTERVAL WITH AGGRESSIVE RETURN: METASTATIC SDHB-MUTATED MEDIASTINAL PARAGANGLIOMA

Seetha Devi Subramanian<sup>1</sup>, Nor Shaffinaz Yusoff Azmi Merican<sup>1</sup>, Shartiyah Ismail<sup>1</sup>

<sup>1</sup>Endocrinology Unit, Department of Medicine, Hospital Sultanah Bahiyah

#### INTRODUCTION

Mediastinal paragangliomas (PGLs) are extremely rare extra-adrenal neuroendocrine tumors, accounting for approximately 2% of all PGLs and commonly associated with pathogenic germline variants (PGVs), particularly those involving succinate dehydrogenase (SDH) mutations.

#### CASE

We report a 35-year-old female presenting with chronic cough and hemoptysis, accompanied by paroxysmal symptoms and new-onset hypertension. She had a history of pheochromocytoma treated 15 years earlier with right adrenalectomy and liver lobectomy due to intraoperative adrenal adherence to the liver. Histopathology confirmed adrenal pheochromocytoma, with no evidence of PGL in the liver. She remained in biochemical remission for 3 years but subsequently defaulted. Biochemical evaluation revealed markedly elevated 24-hour urinary normetanephrine (58,950 nmol/L; ~26-fold increase). Computed tomography of the thorax demonstrated a mediastinal mass compressing the right bronchus, resulting in luminal narrowing and segmental lung collapse. Endobronchial biopsy confirmed PGL (Ki-67 index 5%). Functional imaging with DOTATATE, FDG-PET, and MIBG demonstrated metastatic disease involving the lungs and lymph nodes. Genetic testing identified a heterozygous pathogenic SDHB mutation (c.79C>T; p.Arg27), consistent with autosomal dominant hereditary PGL-pheochromocytoma syndrome; family screening confirmed the same mutation in her father and two siblings. She underwent two sessions of bronchoscopic intervention, including cryoablation, balloon dilation, argon plasma coagulation, and intratumoral alcohol injection for airway control and hemoptysis. Multidisciplinary evaluation deemed complete surgical resection high risk and not feasible; therefore, peptide receptor radionuclide therapy was initiated.

## CONCLUSION

This case demonstrates the aggressive and metastatic nature of SDHB-mutated PGLs. This group of patients require long term surveillance given the risk of developing new tumors even years or decades after primary tumor resection. It highlights the importance of genetic testing following pheochromocytoma surgery to guide targeted therapy, lifelong surveillance, and family screening within a multidisciplinary care approach.

## EP\_A122

### PRUDENT MANAGEMENT OF MICROPROLACTINOMA IN A TRANSGENDER WOMAN ON FEMINIZING HORMONAL THERAPY

Zi Yang Lian<sup>1</sup>, Nicholas Ken Yoong Hee<sup>2</sup>, Shireene Vethakkan<sup>1</sup>, Jeyakantha Ratnasingam<sup>1</sup>

<sup>1</sup>Endocrine Unit, Department of Medicine, Faculty of Medicine, Universiti Malaya

<sup>2</sup>Endocrine Unit, Department of Medicine, Universiti Malaya Medical Centre

## INTRODUCTION

Gender-affirming hormone therapy (GAHT) for transgender women utilizes estrogen and an anti-androgen like cyproterone acetate (CPA) which can both lead to hyperprolactinemia. Although mild prolactin elevations are common, the development of prolactinomas in transgender women on GAHT is rare.

## CASE

A 23-year-old trans-woman on self-purchased estradiol hemihydrate (17 $\beta$ -estradiol) 4 mg and CPA 12.5 mg daily for GAHT presented with galactorrhea. Investigations revealed markedly elevated prolactin at 2,369 mIU/L and elevated estradiol at 848 pmol/L. A pituitary magnetic resonance imaging (MRI) identified a 0.4  $\times$  0.5 cm microprolactinoma.

She declined clinical advice to reduce her medication dose and continued on the same treatment. In the subsequent year, her peak prolactin was 1,383 mIU/L, and a repeat MRI showed the microprolactinoma remained stable. She continues to be on close clinical monitoring.

Transgender females experience approximately a fourfold higher rate of developing prolactinomas. The patient's choice to persist with GAHT reflects the challenges in managing gender dysphoria alongside medical complications. A recent paper by BJ Nolan et al. suggests using prolactin levels exceeding 2,000–3,000 mIU/L to guide further investigations including a pituitary MRI to

rule out a prolactinoma. In most cases, the serum prolactin levels will return to the normal range with a reduction or discontinuation of the GAHT. Normalization of prolactin levels have been reported after gonadectomy and CPA cessation in transgender females on GAHT, which suggests that CPA usage may be associated with higher risk of hyperprolactinemia compared to estrogen therapy.

## CONCLUSION

This case highlights that GAHT can lead to development of prolactinomas. Prolactin monitoring and MRI investigations should be reserved for symptomatic patients, and for those with significantly elevated or increasing prolactin levels. While treatment using dopamine agonists have been reported, this case demonstrates that conservative management and close monitoring can be a viable approach for structurally stable microprolactinomas.

## EP\_A123

### DIAGNOSTIC AND THERAPEUTIC ROLE OF ENDOSCOPIC ULTRASOUND (EUS) IN A CT-NEGATIVE OCCULT INSULINOMA

Chee Kit Tee<sup>1</sup>, Yong Siang Ng<sup>1</sup>, Noor Hafis Md Tob<sup>1</sup>, Norhaliza Mohd Ali<sup>1</sup>

<sup>1</sup>Hospital Sultanah Aminah Johor Bahru

## INTRODUCTION

A negative computed tomography (CT) scan does not preclude an insulinoma, as small lesions frequently remain undetected on conventional imaging. This case highlights the indispensable role of endoscopic ultrasound (EUS)—not just for localizing occult tumors, but as a definitive, minimally invasive therapeutic alternative to high-risk surgical resection.

## CASE

A 39-year-old female with underlying hypertension presented with a 5-month history of predominantly fasting hypoglycemia (glucose <3.0 mmol/L) and neuroglycopenic symptoms, fulfilling Whipple's triad. A supervised 72-hour fast confirmed endogenous hyperinsulinemic hypoglycemia at 31 hours, with a nadir glucose of 1.4 mmol/L, insulin 116 pmol/L, and C-peptide 821 pmol/L. Notably, contrast-enhanced CT of the pancreas was reported as normal. To overcome this, EUS was performed, successfully identifying a hidden 19  $\times$  18 mm lesion in the head of the pancreas, intimately abutting the main pancreatic duct.

Despite medical therapy with diazoxide and strict dietary modifications, her hypoglycemia remained refractory. Given the tumor's proximity to the main pancreatic duct, surgical enucleation carried a prohibitively high risk of

complications. Consequently, she underwent EUS-guided radiofrequency ablation (RFA). Immediate post-procedure outcomes demonstrated near-complete resolution of the hypoglycemic episodes. Diazoxide was subsequently stopped. Outpatient continuous glucose monitoring confirmed sustained normoglycemia and marked symptom resolution, with no procedure-related complications.

#### CONCLUSION

The absence of a pancreatic lesion on CT demands persistent clinical suspicion in cases of biochemically proven hypoglycemia. EUS remains paramount for detecting occult lesions missed by standard imaging. Importantly, EUS-RFA serves as a highly effective, tissue-sparing alternative to surgical resection for insulinomas, especially when conventional surgery poses prohibitive anatomical risks.

## EP\_A124

### RARE PROGRESSION OF MICROPROLACTINOMA TO MACROPROLACTINOMA: A CASE REPORT

Shinye Eng<sup>1</sup> and Rabeah Md Zuki<sup>1</sup>

<sup>1</sup>Medical Department, Hospital Sultan Abdul Halim

#### INTRODUCTION

Prolactinomas are the most common functioning pituitary adenomas, accounting for 50% of all pituitary tumors. Microprolactinomas (<10 mm) are the most frequent subtype and usually follow a benign course, with tumor progression reported in only 5% of cases. We report a rare case of microprolactinoma that progressed to macroprolactinoma over 16 years.

#### CASE

A 39-year-old female was initially diagnosed with a microprolactinoma at the age of 23 during evaluation for irregular menses since menarche. Baseline pituitary magnetic resonance imaging (MRI) at that time revealed a lesion measuring 2 × 2 × 0.8 mm. She was treated with bromocriptine for 2 months but subsequently lost to follow-up. The patient had been married for 10 years without conceiving and continued to have irregular menses.

She decided to repeat prolactin before seeking fertility treatment after 16 years. Laboratory investigations revealed markedly elevated serum prolactin (>42,000 mIU/L) with suppressed gonadotropins, while thyroid and adrenal axes were normal. She reported no galactorrhea, headache, or visual disturbances and notably did not develop amenorrhea. Visual field assessment was normal.

Repeat pituitary MRI demonstrated that the previously diagnosed microprolactinoma had progressed to a macroprolactinoma, measuring 2.1 × 2.3 × 1.6 cm, with extension into the left cavernous sinus and encasement of the left internal carotid artery, without optic chiasm compression. Oral cabergoline 0.25 mg twice weekly was initiated. She was counselled regarding potential risks of dopamine agonist therapy and advised to use mechanical contraception during treatment. At the 2-week follow-up, she tolerated therapy well. Follow-up imaging and prolactin monitoring were planned at 3 months to assess treatment response and guide fertility planning.

#### CONCLUSION

This case highlights the rare progression of microprolactinoma to macroprolactinoma, underscoring the importance of long-term monitoring in patients with prolactinoma. A careful balance between tumor control and fertility management is essential for optimizing care in women of reproductive age.

## EP\_A125

### EMPTY SELLA AS A CLUE TO IDIOPATHIC INTRACRANIAL HYPERTENSION PRESENTING WITH PULSATILE TINNITUS AND PROGRESSIVE HEARING LOSS

Jean Mun Cheah<sup>1</sup>, Prasana Nair Gengadharan<sup>2</sup>, Yuan Ye Beh<sup>2</sup>, Shireene Ratna Vethakkan<sup>1</sup>

<sup>1</sup>Endocrine Unit, Department of Medicine, Faculty of Medicine, Universiti Malaya

<sup>2</sup>Neurology Unit, Department of Medicine, Faculty of Medicine, Universiti Malaya

#### INTRODUCTION

Empty sella (ES) is characterized by herniation of the subarachnoid space into the sella turcica, leading to pituitary flattening. Although often considered incidental, ES is increasingly recognized as a radiological marker of idiopathic intracranial hypertension (IIH) which classically presents with headache and visual loss. Importantly, IIH may also present with otolaryngological manifestations such as pulsatile tinnitus, hearing loss, and vertigo. Audiovestibular symptoms have been reported in up to 88.9% of patients with primary ES, with sensorineural hearing loss being the most frequent, while pulsatile tinnitus occurs in approximately 58% of IIH cases.

#### CASE

A 51-year-old female presented with 3 months of progressively worsening headaches, rapid deterioration of left-sided hearing, and a 20-kg weight gain over 1 year.

Audiometry confirmed moderate left sensorineural hearing loss. Examination revealed a normotensive female with a body mass index of 35 kg/m<sup>2</sup> and diplopia on left upward gaze without evidence of ophthalmoplegia. The rest of the neurological examination was unremarkable. There was no evidence of papilledema or Cushingoid features. Repeat magnetic resonance imaging brain in 2025 showed persistent partial ES and loss of the posterior pituitary bright spot without an intracranial mass lesion or venous sinus thrombosis. There was no biochemical evidence of hypopituitarism or Cushing's syndrome. Autoimmune markers were unremarkable. Lumbar puncture demonstrated a mildly elevated opening pressure of 23 mmHg with normal CSF composition.

Based on the clinical and radiological findings, early IIH was diagnosed. She was treated with acetazolamide, and prescribed tirzepatide for weight reduction, resulting in improvement in headache and tinnitus.

#### CONCLUSION

IIH can manifest with partial ES and audiovestibular symptoms related to raised intracranial pressure. Early recognition is important, and IIH should be suspected in patients with pulsatile tinnitus or progressive sensorineural hearing loss. Acetazolamide and weight management remain the mainstay of treatment, with emerging evidence supporting a potential role for glucagon-like peptide-1 receptor agonists in reducing intracranial pressure.

## EP\_A126

### THE TWO-YEAR PARADOX: A "PANCREATIC ADENOCARCINOMA" REVEALED AS METASTATIC INSULINOMA

Lim Chee Jack<sup>1,2,3</sup>, Gaayathri Krishnan<sup>2,3</sup>, Ilham Ismail<sup>2</sup>, Mahrunissa Mahadi<sup>2</sup>, Nurul Atiqah Abu Sahmah<sup>4</sup>, Tan Geok Chin<sup>4</sup>, Norlaila Mustafa<sup>1,2</sup>, Norasyikin A. Wahab<sup>1,2</sup>

<sup>1</sup>Department of Medicine, Faculty of Medicine, Universiti Kebangsaan Malaysia

<sup>2</sup>Department of Medicine, Hospital Canselor Tuanku Muhriz

<sup>3</sup>Ministry of Health Malaysia

<sup>4</sup>Department of Pathology, Hospital Tuanku Canselor Muhriz

#### INTRODUCTION

Pancreatic neuroendocrine tumors (PNETs) are rare, comprising less than 3% of all pancreatic neoplasms. These tumors are broadly classified as functioning or non-functioning. Insulinoma is the most common functioning PNET. Non-functioning PNETs often present significant

diagnostic issues and may be misdiagnosed as pancreatic adenocarcinoma, especially when immunohistochemical evaluation is omitted during histological examination. We describe a case of metastatic insulinoma that was misdiagnosed as a poorly differentiated pancreatic adenocarcinoma.

#### CASE

A 65-year-old female first presented to a private hospital in 2023 with obstructive jaundice and was found to have a pancreatic head lesion that was causing biliary obstruction. As a result, a biliary stent was placed. She underwent aortocaval lymph node biopsy, and the result showed poorly differentiated pancreatic adenocarcinoma. Nonetheless, she refused surgical and oncological intervention. Even so, she remained clinically stable and maintained good functional status for 2 years.

In 2025, she presented to Hospital Canselor Tuanku Muhriz with recurrent hypoglycemia fulfilling Whipple's triad. The unexpectedly indolent clinical course prompted reassessment of the initial diagnosis. Biochemical evaluation confirmed endogenous hyperinsulinemic hypoglycemia, with inappropriately elevated insulin (11.03 µIU/mL) and C-peptide levels (1,089 pmol/L). Computer tomography of the abdomen revealed multiple hepatic lesions and progressive lymphadenopathy, suggestive of metastatic disease. Re-evaluation of the initial histopathological specimen showed a well-differentiated neuroendocrine tumor (Grade 1, Ki-67 ~2%). Hence, the diagnosis was revised to metastatic insulinoma.

She was referred to the hepatobiliary surgical team for surgical debulking, but the procedure was deemed high-risk and likely to have high mortality due to the extent of the disease. She was managed with diazoxide and long-acting somatostatin analogues for glycemic control.

#### CONCLUSION

This case highlights the critical importance of diagnostic vigilance when evaluating pancreatic neoplasms. Persistent or unexplained clinical courses, especially when endocrine symptoms arise, should prompt thorough reassessment. Immunohistochemical confirmation is essential to avoid misdiagnosis and ensure optimal patient management.

## EP\_A127

### DIAGNOSTIC DILEMMA IN INTERPRETING INFERIOR PETROSAL SINUS SAMPLING IN SUSPECTED CYCLICAL CUSHING'S DISEASE IN AN ADOLESCENT

Nicholas Wee Wern Phan<sup>1</sup>, Pei Sun Tan<sup>1</sup>, Subashini Rajoo<sup>1</sup>, Vanusha A/P Devaraja Pillai<sup>2</sup>, Shazatul Reza binti Mohd Redzuan<sup>1</sup>, Gayathri Devi Krishnan<sup>1</sup>, Sharifah Noor Adrilla Long Mohd Noor Affendi<sup>1</sup>

<sup>1</sup>Endocrine Unit, Department of Internal Medicine, Hospital Kuala Lumpur

<sup>2</sup>Department of Internal Medicine, Hospital Melaka

#### INTRODUCTION

Cushing's disease in adolescents is rare and frequently difficult to diagnose due to overlapping features with common pubertal and metabolic conditions. We present an adolescent who underwent inferior petrosal sinus sampling (IPSS) with possible cyclical Cushing's disease, highlighting the diagnostic challenges and the interpretive value of IPSS.

#### CASE

A 16-year-old female presented with progressive weight gain, acne, hirsutism, secondary amenorrhea, proximal myopathy, violaceous striae, and facial plethora over 1 year. Her 24-hour urinary cortisol was >3,310 nmol/L with failure of suppression following a 1-mg overnight dexamethasone suppression test (701 nmol/L). Her adrenocorticotropic hormone (ACTH) was raised (77.9 pg/mL), consistent with ACTH-dependent Cushing syndrome. Her hemoglobin A1c was 5.9%, and she has low bone mass for age with a Z score of -2.9 at the Lumbar spine.

Pituitary magnetic resonance imaging identified a right-sided microadenoma measuring 0.6 × 0.5 cm, while computed tomography of the thorax, abdomen, and pelvis showed no ectopic source. IPSS with desmopressin stimulation was performed to confirm the ACTH source. No steroidogenesis inhibitors were administered prior to testing. Notably, cortisol levels during IPSS were relatively low, with midnight cortisol of 91 nmol/L and morning cortisol of 200 nmol/L, suggesting testing during a trough phase of possible cyclical hypercortisolism. Despite this, IPSS demonstrated a significant central-to-peripheral ACTH gradient supporting a pituitary source.

#### CONCLUSION

This case highlights the diagnostic dilemma of interpreting IPSS in suspected cyclical Cushing's disease. Fluctuating cortisol secretion may result in discordant biochemical findings and complicate localization studies. IPSS findings

should be interpreted cautiously and integrated with clinical features, imaging, and serial biochemical monitoring. Recognition of cyclical disease patterns is essential to ensure appropriate management in adolescent patients.

## EP\_A128

### WHEN IGF-1 MISLEADS: DISCORDANT BIOCHEMICAL FINDINGS IN ACROMEGALY

Ashwini Chandrasekaran<sup>1</sup>, Subashini Rajoo<sup>1</sup>, Gayathri Devi Krishnan<sup>1</sup>, Shazatul Reza<sup>1</sup>, Sharifah Noor Adrilla<sup>1</sup>, Xe Hui Lee<sup>2</sup>

<sup>1</sup>Hospital Kuala Lumpur

<sup>2</sup>Hospital Pulau Pinang

#### INTRODUCTION

Acromegaly is an endocrine disorder caused by excess growth hormone (GH), causing somatic overgrowth, multiple comorbidities, and premature mortality. It is confirmed biochemically by an elevated GH level, which is not suppressed post oral glucose tolerance test (OGTT). The serum level of insulin-like growth factor-1 (IGF-1) is recommended for diagnosis, monitoring, and screening, and a normal level effectively excludes the disease. We report a patient with acromegaly who presented with normal IGF-1.

#### CASE

A 21-year-old female, with no known medical illness, presented with a persistent, progressive headache and amenorrhea for the past 6 months. She also noticed a change in facial appearance and an increase in the size of her hands and feet. Blood parameters revealed raised GH level of >50 ng/mL, normal IGF-1 30.3 nmol/L (12.17–44.80), mildly raised prolactin 692 mIU/L, low am cortisol 62 nmol/L (166–507), thyroid-stimulating hormone of 0.63 mIU/L (0.27–4.20), free thyroxine 4 11 pmol/L (12–22), low follicle-stimulating hormone 0.90 IU/L, luteinizing hormone <0.30 IU/L, estradiol <18.4 pmol/L, and fasting blood sugar of 17.7 mmol/L with hemoglobin A1c 9%. In view of normal IGF-1 with a high index of suspicion for acromegaly, she underwent OGTT which showed unsuppressed GH. Magnetic resonance imaging pituitary showed sellar mass 2.4 × 2.9 × 2.1 cm with suprasellar extension as well as extension into the right cavernous sinus, suggestive of pituitary macroadenoma. She was diagnosed with acromegaly with secondary adrenal insufficiency and central hypothyroidism with hypogonadotropic hypogonadism, complicated with poorly controlled diabetes. She was started on thyroxine and hydrocortisone replacement and required basal bolus insulin of 1.3 u/kg/day. Repeated IGF-1 showed a raised

value, 85.4 nmol/L, after optimization of diabetes. She underwent endoscopic transsphenoidal surgery with normalization of blood sugar post-surgery. Blood pressure was normal throughout.

#### CONCLUSION

False negative or normal IGF-1 levels may result in patients with hepatic or renal failure, hypothyroidism, malnutrition, use of oral estrogen, severe infection, and poorly controlled diabetes mellitus. Hence, a low or normal IGF-1 does not exclude acromegaly in patients with a high index of suspicion and warrants further investigation.

## EP\_A129

### BIG AND BLURRY: GIANT PROLACTINOMA CASE SERIES

Nur Farrah Anima<sup>1</sup>, Qing Ci Goh<sup>1</sup>, Vanusha Devaraja Pillai<sup>1</sup>, Siow Ping Lee<sup>1</sup>

<sup>1</sup>Endocrinology Unit, Department of Medicine, Hospital Melaka

#### INTRODUCTION

Giant prolactinomas represent 2–3% of prolactin-secreting pituitary adenomas and show a male predominance. They present with mass effect symptoms and hypogonadism, but may be overlooked, leading to delayed diagnosis. Although dopamine agonists are first-line therapy, management remains challenging due to the large size and invasive behavior. This study aims to describe the clinical and radiological features, treatment modalities, and outcomes of three cases of giant prolactinomas. We retrospectively reviewed three men with giant prolactinomas, including their clinical, biochemical, and radiological features, along with treatment and outcomes.

#### CASES

Three male patients aged 35–59 years with giant prolactinomas were included. Two patients presented with visual disturbances, headache, and features of hypogonadism, while one patient had acute confusion and visual loss secondary to obstructive hydrocephalus requiring ventriculoperitoneal shunt insertion. Imaging in all cases demonstrated large invasive pituitary macroadenomas with extensive local extension. Baseline serum prolactin levels were markedly elevated, ranging from 86,568 to 441,116 uIU/mL (86–324 uIU/mL). All patients had secondary hypogonadism, while secondary hypothyroidism and hypocortisolism were each identified in two patients. One patient also had poorly controlled diabetes mellitus at presentation. Dopamine agonist therapy was initiated as the primary therapy for all the patients. Two patients developed cerebrospinal fluid leak following initiation of low-dose dopamine agonist therapy (one patient received

cabergoline 0.25 mg weekly, while another received 0.5 mg weekly), which resolved spontaneously with conservative management. Serum prolactin levels decreased markedly, with significant improvement in symptoms related to mass effect following treatment.

#### CONCLUSION

Giant prolactinomas may present with significant mass effect and multiple pituitary hormone deficiencies. Dopamine agonists remain the cornerstone of management and can result in substantial biochemical and clinical improvement even in large invasive tumors. However, rapid tumor shrinkage may lead to complications such as cerebrospinal fluid leak, highlighting the importance of close monitoring during treatment initiation.

## EP\_A130

### BEYOND THE INFARCT: THE SILENT SELLAR SURPRISE

Siti Nabilah Afni Pakururazi<sup>1,2,3</sup>, Ilham Ismail<sup>2</sup>, Mahrunissa Mahadi<sup>2</sup>, Norlaila Mustafa<sup>1,2</sup>, Norasyikin A. Wahab<sup>1,2</sup>

<sup>1</sup>Department of Medicine, Faculty of Medicine, Universiti Kebangsaan Malaysia

<sup>2</sup>Department of Medicine, Hospital Canselor Tuanku Muhriz

<sup>3</sup>Ministry of Health Malaysia

#### INTRODUCTION

Pituitary apoplexy is a rare, life-threatening endocrine emergency caused by acute hemorrhage or infarction of the pituitary, often in the setting of a pre-existing adenoma (2–12%). While classically presenting with sudden headache, visual loss, and altered consciousness, it can occasionally mimic an acute stroke. Occurrence after coronary procedures is exceptionally rare, particularly when accompanied by cerebral infarction. We report a middle-aged male who developed an acute stroke following percutaneous coronary intervention (PCI) and subsequently had panhypopituitarism secondary to pituitary apoplexy.

#### CASE

A 50-year-old male, with underlying diabetes mellitus, hypertension, dyslipidemia, and chronic kidney disease stage G3A, initially admitted to a private centre for PCI, however, complicated with acute left-sided weakness, headache, and reduced consciousness 2 days post-procedure. He had a history of progressive left visual loss for 3 months. Examination revealed Glasgow Coma Scale E2V4M4, blood pressure 118/82 mmHg, left-sided power 4/5, and temporal pallor of the left optic disc. His blood sugar was 15.5 mmol/L.

Urgent computer tomography scan of the brain demonstrated a right basal ganglia infarct with sellar mass measuring 15 × 15 × 20 mm extending into the suprasellar cistern with mass effect. Magnetic resonance imaging confirmed multifocal acute and chronic infarcts with an acute pituitary hemorrhage compressing the optic chiasm. Biochemistry showed mild acute kidney injury (urea 11.7 mmol/L, creatinine 119 µmol/L) without electrolyte imbalance, thrombocytopenia, or anemia. Hormonal studies revealed partial hypopituitarism with normal thyroid function, secondary adrenal insufficiency (serum morning cortisol 40 nmol/L), and central hypogonadism (serum testosterone 2.2 nmol/L). Hydrocortisone was initiated inpatient, followed later by testosterone replacement and antiplatelet therapy during follow-up.

### CONCLUSION

This case illustrates pituitary apoplexy with an atypical presentation: acute neurological deficits following invasive cardiovascular procedures. It underscores the importance of multidisciplinary management involving endocrinologists, cardiologists, neurologists, and neurosurgeons to optimize outcomes. Early recognition, prompt neuroimaging, and timely treatment are vital to prevent irreversible neurological and endocrine complications.

## EP\_A131

### AVP DEFICIENCY AS THE INITIAL MANIFESTATION OF MULTISYSTEM LANGERHANS CELL HISTIOCYTOSIS: A DIAGNOSTIC ODYSSEY

Yuvaranee Samanaseh<sup>1</sup>, Vanusha Devaraja<sup>1</sup>, Goh Qing Ci<sup>1</sup>, Patricia Lee Siow Ping<sup>1</sup>

<sup>1</sup>Hospital Melaka

### INTRODUCTION

Arginine vasopressin (AVP) deficiency is an uncommon but important presentation of infiltrative hypothalamic-pituitary disorders. In adults, isolated AVP deficiency with pituitary stalk thickening is diagnostically challenging, especially in the absence of systemic disease. Langerhans cell histiocytosis (LCH) is a rare cause and may precede systemic involvement by several years.

### CASE

We report a 42-year-old male who presented in 2017 with polyuria and polydipsia, with urine output of up to 10 L/day. AVP deficiency was confirmed by the water deprivation test, and desmopressin was initiated. Initial pituitary magnetic resonance imaging (MRI) was normal, baseline anterior pituitary hormonal evaluation was unremarkable,

and contrast-enhanced computed tomography (CECT) of the thorax and abdomen showed no abnormalities.

Repeat pituitary MRI 1 year later demonstrated loss of the posterior pituitary bright spot with pituitary stalk thickening. In the absence of systemic involvement, a presumptive diagnosis of lymphocytic hypophysitis was made, and pituitary biopsy was deferred due to the high procedural risk.

Serial pituitary MRIs over the following years showed persistent infundibular thickening and continued absence of the posterior pituitary bright spot, without interval progression or development of additional hormonal deficiencies. The patient remained clinically stable until June 2024, when new-onset left hip pain prompted MRI, revealing a heterogeneous mass involving the femoral neck and intertrochanteric region with a pathological fracture. Histopathological examination following wide resection confirmed LCH, with negative BRAF V600 mutation. Postoperative PET scan revealed a multisystem disease involving the skeleton, lymph nodes, spine, and gastrointestinal tract, with no bone marrow involvement. He subsequently completed six cycles of intravenous methotrexate and cytarabine.

### CONCLUSION

Adult-onset AVP deficiency may be the earliest manifestation of occult multisystem Langerhans cell histiocytosis. This case highlights the importance of long-term follow-up and reconsideration of the initial diagnosis when new systemic features emerge.

## EP\_A132

### A RARE CASE OF PITUITARY APOPLEXY ASSOCIATED WITH MIDDLE CEREBRAL ARTERY INFARCT: A CORRELATION OR COINCIDENCE?

Muhammad Fitri Azizi Mat Dait<sup>1</sup> and Khairul Azmi Ibrahim<sup>1</sup>

<sup>1</sup>Neurology Unit, Medical Department, Hospital Sultanah Nur Zahirah

### INTRODUCTION

Pituitary apoplexy is a rare, life-threatening condition resulting from hemorrhage or infarction of the pituitary gland, most commonly in patients with pre-existing pituitary tumors. It typically presents with a sudden headache, visual disturbance, ophthalmoplegia, and altered mental status. An uncommon but serious complication is ischemic stroke in the middle cerebral artery (MCA)

territory, particularly in the absence of direct internal carotid artery (ICA) compression.

#### CASE

We report a case of a 36-year-old male who presented with headache, visual impairment, and fever. Initial computed tomography (CT) brain imaging demonstrated a heterogeneous sellar lesion with peripheral calcification measuring  $2.4 \times 3.2 \times 2.7$  cm, suggestive of a pituitary mass with possible apoplexy, without evidence of acute cerebral infarction. The patient subsequently developed dysarthria, hemianopia, and reduced consciousness, prompting repeat neuroimaging. Follow-up CT revealed a large hypodense area in the right fronto-parieto-temporal region consistent with ischemic infarction. Magnetic resonance imaging confirmed an acute infarct in the right MCA territory without hemorrhagic transformation. A sellar-suprasellar mass measuring  $2.3 \times 2.8 \times 3.8$  cm was identified, consistent with a pituitary macroadenoma with intratumoral hemorrhage compressing the optic chiasm, but without direct right ICA compression. Time-of-flight mineralocorticoid receptor antagonists demonstrated attenuated flow in the right ICA (C2–C7), suggesting intracranial ICA thrombosis and reduced perfusion in the right MCA and its branches. Laboratory evaluation revealed hyperthyroidism and hypocortisolism, with no evidence of coagulopathy. The patient was treated with corticosteroid replacement and carbimazole and referred for neurosurgical management.

#### CONCLUSION

This case highlights a rare association between pituitary apoplexy and MCA stroke, possibly mediated by vasospasm, inflammation, or hypercoagulability. More research is needed to understand this connection and improve treatment strategies.

## EP\_A133

### DEFYING THE SCALPEL: MANAGEMENT OF PITUITARY APOPLEXY WITH HYDROCORTISONE

Lakshna Vani Nadarajan<sup>1</sup>, Sarojini Devi Simanchalam<sup>1</sup>, Poh Shean Wong<sup>1</sup>, Hamizah Hamzah<sup>1</sup>, Nor Afidah Abdul Karim<sup>1</sup>, Noor Lita Adam<sup>1</sup>

<sup>1</sup>Department of Medicine and Endocrinology, Hospital Tuanku Jaafar

#### INTRODUCTION

Pituitary apoplexy is an acute endocrine emergency, as early recognition may influence the outcomes, often presenting with sudden headache, visual disturbances, ocular palsies, vomiting, or altered consciousness. Given that urgent

surgical decompression is a common management, emerging evidence supports corticosteroid therapy in our patient with significant neuro-ophthalmic deficits.

#### CASE

A 65-year-old male with hypertension, dyslipidemia, type 2 diabetes mellitus, chronic kidney disease stage III, and ischemic heart disease presented with a 4-day history of fever, vomiting, bifrontal headache, and generalized abdominal pain. Initially, he was treated for presumed intra-abdominal sepsis. On day 3 of admission, he developed acute right-sided complete ptosis with ophthalmoplegia involving cranial nerves III, IV, and VI. Prior to that, he had also reduced morning erections for 6 months before presentation. Biochemical evaluation revealed markedly reduced total testosterone (0.33 nmol/L) with inappropriately low-normal gonadotropins (luteinizing hormone 1.5 IU/L, follicle-stimulating hormone 2.3 IU/L), in keeping with secondary hypogonadism. Adrenocorticotrophic hormone was suppressed, indicating secondary adrenal insufficiency. Thyroid function was preserved. Overall findings suggested partial hypopituitarism. Magnetic resonance imaging confirmed a cystic pituitary lesion measuring  $1.4 \times 2.6 \times 1.8$  cm with cavernous sinus involvement and features of pituitary apoplexy. His Pituitary Apoplexy Score was 4. He was offered surgical intervention but was not keen. He was treated with intravenous hydrocortisone, with rapid clinical improvement, including near-complete resolution of right eye ptosis and restoration of extraocular movements within 3 days, and was able to recover without surgery. The hydrocortisone was gradually tapered, and the patient was discharged well with Endocrine follow-up.

#### CONCLUSION

Timely corticosteroid therapy alone can result in rapid, near-complete neurological recovery in pituitary apoplexy, even with multiple cranial nerves involvement. In carefully selected patients without visual field compromise, conservative management may safely obviate the need for urgent surgical intervention, emphasizing the importance of early recognition and individualized treatment strategies.

## EP\_A134

### **MALIGNANT HYPERNATREMIA COMPLICATING A HYPOTHALAMIC TUMOR: AN ENDOCRINE EMERGENCY**

Vijayrama Rao Sambamoorthy<sup>1</sup>, Man Ee Chiew<sup>1</sup>,  
Xe Hui Lee<sup>1</sup>

<sup>1</sup>Endocrine Unit, Medical Department, Hospital Pulau Pinang

#### **INTRODUCTION**

Hypernatremia is a common yet high-mortality electrolyte disorder. The hypothalamus maintains water homeostasis via thirst sensation and arginine vasopressin (AVP) secretion. Hypothalamic tumors, such as gliomas, can progressively destroy these osmoregulatory centres, leading to “malignant” hypernatremia (>180 mmol/L). We report a case of life-threatening hypernatremia in a patient with a progressive hypothalamic glioma, exploring its complex pathophysiology.

#### **CASE**

A 41-year-old female with a progressive high-grade hypothalamic glioma and persistent hydrocephalus presented with generalized weakness, reduced oral intake, and dehydration. Her initial Glasgow Coma Scale was E4V3M6. Laboratory investigations revealed malignant hypernatremia (serum sodium 209 mmol/L) and a serum osmolality of 441 mOsm/kg. Despite life-threatening dehydration (urea 26.2 mmol/L, creatinine 343 umol/L), she was still able to deceptively produce urine output of 400 mL/day with a concentrated urine osmolality of 890 mOsm/kg. A 1 mcg IV desmopressin trial reduced urine output to 60 mL/day and serum sodium by 10 mmol/L within 14 hours, confirming relative AVP deficiency. The patient’s malignant hypernatremia was gradually corrected to 168 mmol/L over 1 week (8–12 mmol/L/day) using controlled intravenous hydration. However, her condition deteriorated due to hospital-acquired infection, and she succumbed 10 days after admission.

#### **CONCLUSION**

This case underscores several critical learning points for managing hypothalamic emergencies. First, hypothalamic tumors can reset the osmostat or destroy osmoregulatory centres, causing adipsic AVP deficiency. Second, clinicians must be alert to “masked polyuria” where severe hypovolemia reduces the glomerular filtration rate, causing urine output to appear “normal” despite underlying AVP deficiency. This state of “relative polyuria” is a hallmark of hypothalamic hypernatremia, thus indicating that a normal urine output does not rule out AVP deficiency. While desmopressin is indicated, its use in adipsic patients demands strict fluid titration to prevent iatrogenic hyponatremia. Rapid hypotonic correction carries a proven risk of

cerebral oedema, and sodium measurement accuracy varies significantly across laboratory methods in extreme ranges.

## EP\_A135

### **ISOLATED CRANIAL DIABETES INSIPIDUS UNMASKED AFTER HYPEROSMOLAR HYPERGLYCEMIC STATE IN TYPE 2 DIABETES MELLITUS**

Suseelah Bala Subramaniam<sup>1</sup>, Rabeah Md Zuki<sup>2</sup>, Loh  
Hoong Heng<sup>3</sup>

<sup>1</sup>Department of Internal Medicine, Hospital Kulim

<sup>2</sup>Department of Endocrinology, Hospital Sultan Abdul Halim

<sup>3</sup>Department of Internal Medicine, Hospital Kulim

#### **INTRODUCTION**

Central diabetes insipidus (CDI) is characterized by impaired arginine vasopressin secretion, resulting in hypotonic polyuria and hypernatremia. In patients with coexisting diabetes mellitus, persistent polyuria may be misattributed to hyperglycemia, delaying recognition of a concurrent water balance disorder. CDI without identifiable structural abnormalities may be overlooked, leading to delayed diagnosis and complications.

#### **CASE**

We report a 30-year-old Malay female with underlying type 2 diabetes mellitus and premorbid obesity who presented with hyperosmolar hyperglycemic state, accompanied by persistent polyuria, polydipsia, weight gain, and amenorrhea. Despite resolution of hyperglycemia, she had ongoing polyuria with hypernatremia, raising suspicion of a concomitant water balance disorder.

Biochemical evaluation demonstrated a hyperosmolar state with serum osmolality 334 mOsm/kg and inappropriately dilute urine (urine osmolality 254 mOsm/kg), supporting impaired vasopressin activity. A modified water deprivation test showed a >50% rise in urine osmolality following desmopressin, consistent with CDI. Diabetes autoantibody screening was negative. Anterior pituitary function was preserved, with normal thyroid and adrenal axes (thyroid-stimulating hormone 3.30 mIU/L, cortisol 290.6 nmol/L), and gonadotropins not suggestive of hypopituitarism (luteinizing hormone 6.8 IU/L, follicle-stimulating hormone 24.6 IU/L).

Neuroimaging with computed tomography brain showed no structural hypothalamic-pituitary lesion. Magnetic resonance imaging of the pituitary demonstrated absence of the posterior pituitary bright spot, with preserved gland morphology and no focal lesion, supporting CDI without an identifiable structural cause.

Her clinical course was complicated by severe hospital-acquired infection leading to septic shock, requiring intensive care support, mechanical ventilation, and renal replacement therapy. She was commenced on desmopressin, with subsequent clinical and biochemical improvement, alongside multidisciplinary management.

#### CONCLUSION

In patients with type 2 diabetes mellitus, persistent polyuria may obscure an underlying water balance disorder. This case highlights the importance of considering alternative causes of polyuria and a systematic endocrine approach to ensure accurate diagnosis and appropriate management.

## EP\_A136

### RARE CASE: EMPTY SELLA SYNDROME, GROWTH HORMONE DEFICIENCY, AND HASHIMOTO'S THYROIDITIS IN THALASSEMIA SPECTRUM

**Athari Fadhila Namanda Putri<sup>1,2</sup>, Eva Decroli<sup>2</sup>, Dinda Aprilia<sup>2</sup>, Alexander Kam<sup>1,2</sup>, Yanne Pradwi Efendi<sup>1</sup>**

<sup>1</sup>Internal Medicine Department, Medical Faculty, Universitas Andalas

<sup>2</sup>Endocrinology Metabolic and Diabetes Division, Internal Medicine Department, Medical Faculty, Universitas Andalas/ M. Djamil General Hospital

#### INTRODUCTION

Thalassemia is a hemoglobin synthesis disorder associated with chronic anemia and transfusion-related iron overload, which predisposes patients to multiple endocrine complications. Iron deposition in the pituitary and gonads may result in growth hormone deficiency (GHD) and hypogonadism. Empty sella syndrome (ESS), characterized by herniation of the subarachnoid space into the sella turcica, may also contribute to hypopituitarism. The coexistence of thalassemia-related endocrinopathies, ESS, and autoimmune thyroid disease is rare and presents significant diagnostic complexity.

#### CASE

A 27-year-old female with transfusion-dependent thalassemia on deferiprone presented with secondary amenorrhea and short stature. Her height was 145 cm (below the target range of 140.5–157.5 cm), body mass index 17.3 kg/m<sup>2</sup>, and Tanner stage M3P1.

Laboratory evaluation revealed elevated thyroid-stimulating hormone (10.92 mIU/L) with low-normal free thyroxine 4 (11.4 pmol/L), consistent with primary hypothyroidism. Thyroid ultrasound demonstrated

features of chronic thyroiditis, and anti-thyroid peroxidase antibodies (8.18 IU/mL) supported a diagnosis of Hashimoto's thyroiditis. Insulin-like growth factor-1 was markedly reduced (68 ng/mL), indicating GHD. Morning cortisol was within normal range (14.5 µg/dL). Gonadotropins were inappropriately low-normal (follicle-stimulating hormone 7.42 mIU/mL, luteinizing hormone 11.41 mIU/mL) with low estradiol (26.49 pg/mL), suggesting hypogonadotropic hypogonadism.

Skeletal survey showed thalassemia-related bone changes, including trabecular coarsening and metaphyseal widening, with a predicted adult height of 142.7 cm. Pituitary magnetic resonance imaging revealed an empty sella.

#### CONCLUSION

Thalassemia must be recognized not only as a primary hematologic condition but also as a complex multisystem disorder with profound endocrine implications. Furthermore, the co-occurrence of these conditions with rare manifestations such as ESS and Hashimoto's thyroiditis underscores the diagnostic complexity faced by clinicians. Therefore, early detection and rigorous, regular endocrine screening are essential to optimize management strategies and improve the long-term quality of life for patients with thalassemia.

## EP\_A137

### THYROID-STIMULATING HORMONE (TSH)-SECRETING MACROADENOMA PRESENTING WITH RECURRENT ATRIAL FIBRILLATION IN FAILURE

**Muzhaffar Mokhtar<sup>1</sup>, Masliza Hanuni Mohd Ali<sup>1</sup>, Wan Mohd Hafez Wan Hamzah<sup>1</sup>**

<sup>1</sup>Endocrine Unit, Department of Medicine, Hospital Sultanah Nur Zahirah

#### INTRODUCTION

Accounting for less than 2% of all pituitary adenomas, TSH-secreting pituitary adenomas (TSHoma) are an uncommon cause of hyperthyroidism. Majority are macroadenomas with delayed diagnosis as most patients are unwittingly treated for primary hyperthyroidism. Recurring discordant thyroid function test (TFT) with elevated thyroid-stimulating hormone (TSH) and Free T4 is a hint and warrants additional investigation to facilitate diagnosis.

#### CASE

We report a case of a 48-year-old female who was treated for primary hyperthyroidism since her late 20s with multiple admissions for recurrent congestive heart failure

and atrial fibrillation. The cardiac issue was preceded by worsening thyrotoxicosis. Previous thyroid autoantibodies were negative. Of note, she had recurring discordant TFT results from two different assays (TSH:84.7, free thyroxine 4 [FT4]:75.43) (TSH:37.86, FT4:27.34) during admission, excluding assay interference and prompting toward TSHoma or Resistance to Thyroid Hormone (RTH). Examination revealed a large goiter (10 × 8 cm) hard in consistency, and pansystolic murmur over tricuspid area. No thyroid eye disease nor bitemporal hemianopia or clinical sign of acromegaly.

Echocardiography showed dilated left atrium and mild to moderate tricuspid regurgitation with preserved ejection fraction. Thyroid-releasing hormone (TRH) stimulation test demonstrated blunted TSH response confirming TSHoma. Anterior pituitary hormone profile revealed normal insulin-like growth factor-1 level with suppressed sex hormones and prolactin, thus excluding co-secreting hormone. Sex hormone-binding globulin level,  $\alpha$ -subunit, and T3 suppression test were not done due to unavailability. Magnetic resonance imaging pituitary uncovered pituitary mass measuring (2.6 × 3.3 × 2.2 cm) suggestive of macroadenoma with encasement of cavernous internal carotid arteries and cavernous sinus compression. Computed tomography neck revealed diffuse thyroid enlargement with compressive mass effects onto adjacent structure with trachea narrowing. After discussing with a multidisciplinary team, we planned her for total thyroidectomy followed by transsphenoidal surgery.

#### CONCLUSION

Late presentation and diagnosis in TSHoma remain a major challenge. TFT interpretation is fundamental in identifying the causes of secondary hyperthyroidism to avert detrimental sequelae and to guide optimal treatment.

## EP\_A138

### SMALL LESION, BIG IMPACT: EUS LOCALIZATION AND ABLATION OF A CT-OCCULT INSULINOMA

Tharshini Indrajothy<sup>1</sup>, Vanusha Devaraja<sup>1</sup>, Goh Qing Ci<sup>1</sup>, Tay Yang Zet<sup>2</sup>, Patricia Lee Siow Ping<sup>1</sup>

<sup>1</sup>Hospital Melaka

<sup>2</sup>Hospital Kuala Lumpur

#### INTRODUCTION

Insulinoma is a rare functioning pancreatic neuroendocrine tumor and the most common cause of endogenous hyperinsulinemic hypoglycemia. Although biochemical confirmation is usually straightforward, tumor localization

may be difficult when lesions are small and not detected on conventional cross-sectional imaging. In such cases, endoscopic ultrasound (EUS) plays an important role in identifying occult lesions and facilitating definitive treatment.

#### CASE

A 52-year-old female was admitted in April 2025 with recurrent seizures secondary to hypoglycemia for 3 years, with increasing frequency over time. She fulfilled Whipple's triad, with documented capillary glucose of 1.8 mmol/L during an episode and symptom resolution following glucose administration. A supervised prolonged fasting test confirmed endogenous hyperinsulinemic hypoglycemia, with plasma glucose 1.4 mmol/L, insulin 122 pmol/L, and C-peptide 1,010 pmol/L. Short Synacthen test demonstrated adequate adrenal reserve. Due to persistent hypoglycemia, she required high-dose diazoxide.

Contrast-enhanced computed tomography abdomen did not reveal a pancreatic lesion but incidentally detected a right ovarian teratoma. She underwent total abdominal hysterectomy and bilateral salpingo-oophorectomy in June 2025, with histopathology confirming a mature cystic teratoma without malignancy. However, hypoglycemic episodes persisted. Further evaluation with EUS in July 2025 identified a highly vascular isoechoic 8 × 8 mm lesion in the pancreatic body. Fine-needle biopsy confirmed a well-differentiated neuroendocrine tumor (WHO grade 1) with Ki-67 index of 2%. She subsequently underwent EUS-guided radiofrequency ablation in August 2025. Follow-up EUS in December 2025 showed post-ablation change, and her hypoglycemic episodes resolved completely, allowing diazoxide to be discontinued.

#### CONCLUSION

This case highlights the diagnostic challenge of occult insulinoma in the presence of negative conventional imaging. EUS was pivotal for tumor localization and tissue diagnosis, while EUS-guided radiofrequency ablation provided effective minimally invasive treatment in a carefully selected patient.

## EP\_A139

### CUSHING DISEASE MASQUERADING AS POLYCYSTIC OVARY SYNDROME: A DIAGNOSTIC PITFALL IN SEVERE HYPERANDROGENISM

Jean Mun Cheah<sup>1</sup>, Fei Bing Yong<sup>1</sup>, K.J. Lingeswary<sup>1</sup>, Jen Hoong Oon<sup>1</sup>, Sharifah Noor Adrilla binti Long Mohd Noor Affendi<sup>1</sup>, Gayathri Devi A/P Krishnan<sup>1</sup>, Shazatul Reza binti Mohd Redzuan<sup>1</sup>, Subashini Rajoo<sup>1</sup>

<sup>1</sup>Endocrine Unit, Department of Medicine, Hospital Kuala Lumpur

#### INTRODUCTION

Polycystic ovary syndrome (PCOS) is the most common cause of hyperandrogenism in women of reproductive age. However, several endocrine disorders, particularly Cushing disease (CD), can closely mimic the clinical, biochemical, and radiological features of PCOS. This overlap may lead to misdiagnosis and delayed recognition of hypercortisolism, with significant metabolic and reproductive consequences.

#### CASE

We report a 24-year-old female with young-onset diabetes mellitus who was referred for endocrine co-management during admission for recurrent mons pubis and labial abscesses with poorly controlled glycemia. She had a 5-year history of progressive hirsutism, oligomenorrhoea, scalp hair loss, significant weight gain, and insulin resistance, and had previously been labelled as having PCOS during adolescence, with subsequent default of follow-up. On examination, she was obese (body mass index 33 kg/m<sup>2</sup>) with plethoric facies, acanthosis nigricans, proximal myopathy, and hirsutism (Ferriman–Gallwey score 10), without overt virilization or acromegalic features.

Biochemical evaluation demonstrated severe hyperandrogenism with markedly elevated total testosterone (7.05 nmol/L), suppressed gonadotropins, and adrenocorticotrophic hormone (ACTH)-dependent hypercortisolism. Cortisol failed to suppress on low-dose dexamethasone testing, and 24-hour urinary free cortisol was markedly elevated (>4,900 nmol/24 h). Pelvic ultrasonography and computed tomography imaging showed polycystic ovarian morphology without evidence of an ovarian mass. Pituitary magnetic resonance imaging revealed a small right-sided pituitary microadenoma measuring 2.6 × 3.7 mm. Inferior petrosal sinus sampling demonstrated a central-to-peripheral ACTH gradient with adequate prolactin ratios, confirming pituitary CD.

#### CONCLUSION

This case highlights how Cushing disease can closely mimic PCOS, including polycystic ovarian morphology and hyperandrogenism. Progressive symptoms, severe biochemical androgen excess, and marked insulin resistance should prompt evaluation for secondary causes of hyperandrogenism, particularly hypercortisolism, to avoid delayed diagnosis and prolonged morbidity.

## EP\_A140

### CRISIS IN THE MASTER GLAND: A CASE SERIES OF PITUITARY APOPLEXY

Lok Yee Chek<sup>1</sup>, Wei Wei Ng<sup>1</sup>, Ijaz binti Hallaj Rahmatullah<sup>1</sup>, Anilah Abdul Rahim<sup>1</sup>

<sup>1</sup>Hospital Raja Permaisuri Bainun

#### INTRODUCTION

Pituitary apoplexy is a rare but potentially life-threatening endocrine emergency caused by hemorrhage or infarction of the pituitary gland. Its presentation often mimics other acute neurological conditions, posing diagnostic and management challenges. We report a case series of three patients presenting with similar neuro-ophthalmic complaints but differing in symptom onset and radiological features.

#### CASES

The first case was a 25-year-old obese female who presented with acute headache, fever, and right eye ptosis with complete ophthalmoplegia for 2 days. Imaging demonstrated a heterogeneous pituitary macroadenoma with superimposed hemorrhage. Cortisol, prolactin, and insulin-like growth factor-1 levels were low. She received hydrocortisone replacement and underwent left pterional craniotomy with tumor debulking, resulting in marked visual improvement.

The second case involved a 59-year-old male who presented with headache and bilateral blurred vision for 1 week, followed by acute right-sided ptosis. Imaging showed a heterogeneous sellar-suprasellar mass compressing the optic chiasm. He had central hypocortisolism, hypothyroidism, and hyponatremia. Surgical intervention was declined, and outpatient follow-up showed stable neuro-ophthalmic findings.

The third case was a 30-year-old female who presented with a 2-week history of headache and right-sided blurred vision with temporal hemianopia. Imaging revealed a sellar-suprasellar mass with fluid-fluid levels compressing the optic chiasm. She had central hypocortisolism, hypothyroidism, and hypogonadism. Hydrocortisone

replacement was initiated, followed by transsphenoidal surgery with tumor debulking. Her vision improved after the surgery.

#### CONCLUSION

Pituitary apoplexy may present with similar clinical features despite differing onset and radiological characteristics. Early corticosteroid therapy is essential, while surgical intervention should be reserved for patients with severe or progressive neuro-ophthalmic deficits. This case series highlights the importance of individualized, multi-disciplinary management to achieve favorable outcomes.

## EP\_A141

### COEXISTENCE OF NONFUNCTIONING PITUITARY ADENOMA AND GRAVES' DISEASE: A DIAGNOSTIC CHALLENGE

Alexander Kam<sup>1,2</sup>, Dinda Aprilia<sup>1,2</sup>, Eva Decroli<sup>1,2</sup>, Syafril Syahbuddin<sup>1,2</sup>, Yanne Pradwi Efendi<sup>1,2</sup>, Athari Fadhila Namanda Putri<sup>1,2</sup>

<sup>1</sup>Metabolic Endocrinology and Diabetes Division, Internal Medicine Department, Medical Faculty, Universitas Andalas

<sup>2</sup>Metabolic Endocrinology and Diabetes Division, Internal Medicine Department, M. Djamil General Hospital

#### INTRODUCTION

Nonfunctioning pituitary adenomas (NFPA) may cause central hypothyroidism due to pituitary compression, often presenting with low thyroid-stimulating hormone (TSH). However, suppressed TSH in this setting should not automatically be attributed to pituitary dysfunction, as primary hyperthyroidism—such as Graves' disease—may rarely coexist. Distinguishing between these disorders is essential to avoid misdiagnosis and inappropriate management.

#### CASE

A 42-year-old female presented with intermittent headache, visual field impairment, palpitations, fine tremors, and weight loss. Physical examination revealed visual field deficits and no goiter.

Laboratory evaluation showed cortisol level of 1 µg/dL (normal: 3.7–19.4 µg/dL), luteinizing hormone 1.62 mU/L (normal: 2.4–12.6 mU/L), follicle-stimulating hormone 5.01 mU/L (normal: 3.5–12.5 mU/L), free thyroxine 428.32 pmol/L (normal: 12–22 pmol/L), TSH 0.02 µIU/mL (normal: 0.27–4.2 µIU/mL), and prolactin 70.84 ng/mL. Thyrotropin receptor antibody (TRAb) was 3.53 IU/L, confirming Graves' disease.

Contrast-enhanced brain magnetic resonance imaging demonstrated a pituitary macroadenoma (2.13 × 2.28 × 3.05 cm) with optic chiasm compression.

The patient was diagnosed with NFPA, Graves' disease, secondary adrenal insufficiency, possible hypogonadotropic hypogonadism, and hyperprolactinemia likely due to the stalk effect.

Preoperative management included hydrocortisone replacement and antithyroid therapy. The patient subsequently underwent transsphenoidal surgery with appropriate perioperative care. Postoperatively, no new pituitary hormone deficiencies were observed. She was maintained on thiamazole 10 mg daily with clinical improvement and remains under regular follow-up.

#### CONCLUSION

This case highlights a rare but clinically important coexistence of NFPA and Graves' disease. Suppressed TSH in patients with pituitary adenoma should not be assumed to reflect pituitary dysfunction without thorough evaluation. Comprehensive thyroid assessment is crucial to ensure accurate diagnosis and appropriate management.

## EP\_A142

### RECURRENT ISCHEMIC STROKE TWO DECADES AFTER CRANIOSPINAL RADIOTHERAPY FOR SUPRASellar GERMINOMA: A CASE OF SUSPECTED RADIATION-INDUCED CEREBROVASCULAR DISEASE

Choon Peng Sun<sup>1</sup> and Ahmad Affan bin Hassannuddin<sup>1</sup>

<sup>1</sup>Hospital Teluk Intan

#### INTRODUCTION

Cranial radiotherapy is an established treatment for intracranial germinoma but may lead to late cerebrovascular complications including radiation-induced vasculopathy, cavernoma formation, and premature intracranial atherosclerosis. These complications may manifest many years after treatment and represent an important cause of stroke in young adult survivors of brain tumors.

#### CASE

We report a 39-year-old male with a history of suprasellar germinoma treated with transsphenoidal surgery followed by craniospinal radiotherapy in 2006. He subsequently developed panhypopituitarism requiring lifelong hormone replacement therapy. In October 2024, he experienced a cerebrovascular accident resulting in mild residual right-sided weakness. Brain magnetic resonance imaging demonstrated multifocal old infarcts, small vessel disease (Fazekas grade 2), and multiple susceptibility artifacts suggestive of radiation-induced cavernomas.

In March 2026, he presented with new onset right-sided weakness and facial asymmetry. Initial neurological examination revealed right-sided motor power of 4/5. Computed tomography of the brain showed no acute intracranial hemorrhage but confirmed multiple old infarcts and small vessel ischemic changes. Computed tomography angiography revealed intracranial atherosclerotic disease with 25–50% stenosis of the cavernous segments of both internal carotid arteries and mild irregularities of posterior circulation vessels without evidence of large vessel occlusion or aneurysm.

Radiation-induced vasculopathy is a recognized delayed complication of cranial irradiation, often presenting 5–25 years after treatment. Pathophysiological mechanisms include endothelial injury, accelerated atherosclerosis, and progressive arterial stenosis. In rare cases, cranial irradiation may also lead to secondary Moyamoya syndrome, characterized by progressive stenosis of the intracranial internal carotid arteries with development of collateral vessels. Although this patient's vascular imaging did not demonstrate the characteristic collateral network seen in Moyamoya syndrome, it remains an important differential diagnosis in young patients presenting with recurrent stroke after cranial irradiation. In this patient, young age, prior cranial irradiation, multifocal infarcts, and coexisting radiation-induced cavernomas strongly suggest radiation-related cerebrovascular disease as a major contributor to recurrent stroke.

## CONCLUSION

Long-term survivors of intracranial germinoma treated with cranial radiotherapy remain at risk of delayed cerebrovascular complications. Early recognition and aggressive secondary stroke prevention, along with continued neurological surveillance, are essential to reduce morbidity in this population.

## EP\_A143

### ASSOCIATION BETWEEN MEN1 GENE AND AIHA

**Fatihin Abdul Razak<sup>1</sup>, Nur Aini Eddy Warman<sup>1</sup>, Mohd Hazriq Awang<sup>1</sup>, Aimi Fadilah Mohamad<sup>1</sup>, Nur Haziqah Baharum<sup>1</sup>, Fatimah Zaherah Mohamed Shah<sup>1</sup>, Rohana Abdul Ghani<sup>1</sup>**

<sup>1</sup>Department of Internal Medicine, Faculty of Medicine, Universiti Teknologi MARA

## INTRODUCTION

Multiple endocrine neoplasia type 1 (MEN1) is a rare autosomal dominant syndrome caused by mutations in the tumor suppressor gene MENIN, classically characterized

by endocrine tumors of the parathyroid glands, pancreas, and pituitary. Beyond tumorigenesis, emerging evidence suggests a role for MENIN in immune regulation, with deficiency linked to CD4<sup>+</sup> and CD8<sup>+</sup> lymphocyte dysfunction and predisposition to autoimmunity. While autoimmune conditions such as thyroiditis and pernicious anemia have been described in MEN1, an association with autoimmune hemolytic anemia (AIHA) has not been previously reported. We describe a rare case of MEN1 associated with warm AIHA, highlighting a potential link between endocrine tumorigenesis and immune dysregulation.

## CASE

A 56-year-old female presented with a 4-month history of lethargy, anorexia, weight loss, and painless jaundice. She is para 6 + 1, with no history of anemia in pregnancy, prior blood transfusions, or family history of hematological disorders. Examination revealed mild pallor, jaundice, and hepatomegaly without splenomegaly.

She had a prior diagnosis of MEN1, with two hallmark features: primary hyperparathyroidism and a pancreatic neuroendocrine tumor. She underwent pancreatic enucleation, hemithyroidectomy, and hemiparathyroidectomy; histopathology demonstrated a benign thyroid nodule and parathyroid hyperplasia.

Whole exome sequencing identified no pathogenic MEN1 mutation but revealed a c.1621A>G variant, classified as a non-deleterious polymorphism. Variants in TP53 and BRCA1 were also detected without phenotypic expression. Surveillance colonoscopy and mammography were unremarkable.

Laboratory findings were consistent with warm AIHA, including elevated lactate dehydrogenase, indirect hyperbilirubinemia, low haptoglobin, reticulocytosis, and a positive direct Coombs test (immunoglobulin G). Peripheral blood film was nonspecific. She responded well to a tapering course of prednisolone.

## CONCLUSION

This case highlights a possible association between MEN1 and autoimmune hemolysis. The presence of the MEN1 c.1621A>G variant, alongside TP53 and BRCA1 variants, raises the possibility of modifier effects influencing immune dysregulation. Further studies are needed to clarify this relationship.

## EP\_A144

### BIOCHEMICAL DISCORDANCE IN ACROMEGALY COMPLICATED BY PITUITARY APOPLEXY AND SEVERE INSULIN RESISTANCE

Jean Mun Cheah<sup>1</sup>, Fei Bing Yong<sup>1</sup>, K.J. Lingeswary<sup>1</sup>, Jen Hoong Oon<sup>1</sup>, Sharifah Noor Adrilla binti Long Mohd Noor Affendi<sup>1</sup>, Gayathri Devi A/P Krishnan<sup>1</sup>, Shazatul Reza binti Mohd Redzuan<sup>1</sup>, Subashini Rajoo<sup>1</sup>

<sup>1</sup>Endocrine Unit, Department of Medicine, Hospital Kuala Lumpur

#### INTRODUCTION

Acromegaly is usually diagnosed by elevated age- and sex-adjusted insulin-like growth factor-1 (IGF-1) levels reflecting chronic growth hormone (GH) excess. IGF-1 is preferred as a screening biomarker due to its longer half-life and reduced pulsatility compared with GH. However, IGF-1 levels may be disproportionately low or only modestly elevated in certain clinical contexts, leading to diagnostic uncertainty. Pituitary apoplexy is one such condition in which acute tumor hemorrhage or infarction may disrupt sustained GH secretion and attenuate IGF-1 production.

#### CASE

A 48-year-old female with hypertension, type 2 diabetes mellitus, and dyslipidemia presented with a 2-day history of severe headache, vomiting, and visual disturbance, on a background of progressive acral enlargement over 2 years. Examination revealed coarse facial features, prognathism, enlarged hands, and cranial nerve involvement. Magnetic resonance imaging demonstrated an invasive sellar-suprasellar pituitary macroadenoma with optic chiasmal compression and cavernous sinus encasement. Intravenous dexamethasone was initiated pre-operatively due to a significant mass effect.

Biochemical evaluation showed markedly elevated random GH levels (>50 ng/mL) with only mildly elevated IGF-1 at 1.19 times the upper limit of normal, below the threshold at which confirmatory oral glucose tolerance testing may be omitted according to current guidelines. Other pituitary axes suggested evolving hypopituitarism. During admission, she developed severe hyperglycemia with marked insulin resistance, requiring high-dose insulin therapy (approximately 1.5 U/kg/day). She underwent urgent transsphenoidal surgery, with histopathology confirming a pituitary neuroendocrine tumor with extensive hemorrhage and infarction, consistent with pituitary apoplexy. Postoperatively, GH levels were suppressed to <5 ng/mL, insulin requirements decreased markedly, and hormone replacement was initiated for secondary adrenal insufficiency and central hypothyroidism.

#### CONCLUSION

This case highlights that IGF-1 levels below conventional diagnostic thresholds do not exclude clinically significant acromegaly, particularly in the setting of pituitary apoplexy. Integration of clinical phenotype, GH levels, and imaging findings is essential to avoid diagnostic delay and ensure timely management.

## EP\_A145

### GROWTH AGAINST THE CLOCK: HORMONAL THERAPY IN LATE-DIAGNOSED MOSAIC TURNER SYNDROME

Asma' Mohd Nazlee<sup>1</sup>, Dorothy Maria Anthony Bernard<sup>1</sup>, Siti Sanaa Wan Azman<sup>1</sup>, Siew Hui Foo<sup>1</sup>

<sup>1</sup>Endocrinology Unit, Internal Medicine Department, Hospital Selayang

#### INTRODUCTION

Short stature and delayed puberty characterize Turner syndrome (TS). The 2024 international clinical practice guidelines recommend growth hormone (GH) for late-diagnosed patients if epiphyses remain open. For patients with remaining growth potential, initiating GH alongside low-dose estrogen effectively balances linear growth with the need for timely pubertal induction.

#### CASE

A 15-year-old female, born prematurely at 6 months gestation, presented with delayed puberty, primary amenorrhea, and short stature. Examination revealed a height of 122 cm (<5<sup>th</sup> percentile), weight of 26 kg, with no syndromic facies, and Tanner stage 1. Investigations confirmed hypergonadotropic hypogonadism. Metabolic screening, including thyroid, renal, and liver profile, was normal. Her baseline insulin-like growth factor 1 (IGF-1) was low at 117.5 ng/mL (127.5–541.5). Karyotyping confirmed mosaic TS (45,X/46,Xr). Her skeletal bone age was delayed at 12 years, indicating a viable window for linear growth prior to complete epiphyseal fusion.

Subcutaneous GH was initiated at 0.3 mg up titrated to 1.2 mg (0.45 µg/kg) daily over 4 weeks, then 1.35 mg (50 µg/kg) daily at month 5. Low-dose oral estradiol (0.5 mg three times weekly) was introduced for pubertal induction at month 4. After 9 months of combined GH and estrogen therapy, the patient achieved a height increment of 6 cm, reaching 128 cm without an adverse event. To achieve the clinical target of a 10–15 cm increment in the first year, her GH dose was further increased to 1.50 mg (55 µg/kg) daily. She showed an appropriate biochemical response with IGF-1 increased to 40.2 nmol/L (16.4–67.8) with a total height gain of 6 cm over the first 9 months of GH therapy.

## CONCLUSION

Concomitant GH and estrogen therapy in late-diagnosed TS successfully induced clinically significant height gain. This dual approach maximized the limited window for linear growth, without delaying pubertal induction and compromising patient's psychosocial well-being.

## EP\_A146

### FULVESTRANT INTERFERENCE WITH ESTRADIOL IMMUNOASSAYS: A CASE REPORT AND REVIEW OF LABORATORY IMPLICATIONS

Dywei Lee<sup>1</sup> and Waye Hann Kang<sup>1</sup>

<sup>1</sup>Department of Medicine, M. Kandiah Faculty of Medicine and Health Sciences, Universiti Tunku Abdul Rahman

#### INTRODUCTION

Fulvestrant, a selective estrogen receptor degrader widely used in hormone receptor-positive breast cancer, can cause significant analytical interference with estradiol immunoassays due to structural similarity with 17 $\beta$ -estradiol. This interference may result in falsely elevated estradiol measurements, potentially leading to diagnostic confusion and inappropriate clinical interventions. We report a case demonstrating this clinically significant analytical interference and emphasize the importance of liquid chromatography-tandem mass spectrometry (LC-MS/MS) in hormone monitoring for patients receiving fulvestrant therapy.

#### CASE

A 31-year-old female with metastatic hormone receptor-positive breast cancer receiving combination therapy (fulvestrant, letrozole, ribociclib, and goserelin) presented with inappropriately elevated serum estradiol levels of 566 pmol/L (early follicular phase 200–500 pmol/L), measured by chemiluminescence immunoassay. Despite effective gonadotrophin suppression evidenced by low luteinizing hormone (0.2 IU/L) and follicle-stimulating hormone (4.1 IU/L) levels and clinical amenorrhea, the discordant estradiol elevation raised suspicion of assay interference. Confirmatory testing with LC-MS/MS revealed an estradiol concentration of <36 pmol/L, consistent with expected hormonal suppression and confirming immunoassay cross-reactivity with fulvestrant.

The case demonstrates significant fulvestrant interference with estradiol immunoassays, resulting in a greater than 15-fold overestimation compared to LC-MS/MS measurement. The clinical presentation was consistent with effective endocrine therapy, supported by suppressed gonadotropin

levels, clinical amenorrhea, and stable disease on imaging. LC-MS/MS provided accurate estradiol measurement, avoiding potential diagnostic confusion and unnecessary clinical interventions.

## CONCLUSION

Clinicians should be aware of potential fulvestrant interference with estradiol immunoassays when interpreting hormone levels in breast cancer patients. Discordant laboratory findings, particularly elevated estradiol despite clinical evidence of effective hormonal suppression, should prompt consideration of LC-MS/MS confirmation. This case underscores the clinical importance of analytical method selection in hormone monitoring and highlights the need for improved laboratory-clinical communication to optimize patient care in oncology practice.

## EP\_A147

### PRIMARY AMENORRHEA IN A PATIENT WITH CONGENITAL ANOMALIES OF THE KIDNEY AND URINARY TRACT (CAKUT): UNMASKING ATYPICAL MRKH SYNDROME TYPE II

Dameil Saw Kah Kheng<sup>1</sup>

<sup>1</sup>Hospital Queen Elizabeth II

#### INTRODUCTION

Mayer-Rokitansky-Küster-Hauser (MRKH) syndrome is characterized by congenital agenesis or hypoplasia of the uterus and upper vagina in phenotypic females with normal secondary sexual characteristics and a 46,XX karyotype. Atypical MRKH syndrome, or MRKH type II, is associated with extragenital anomalies, particularly renal abnormalities. Its diagnosis may be delayed when overshadowed by complex medical comorbidities.

#### CASE

A 19-year-old phenotypic female with CAKUT, complicated by right duplex kidney and end-stage renal failure on continuous ambulatory peritoneal dialysis, was admitted in September 2025 for peritonitis. Further history revealed primary amenorrhea. Physical examination demonstrated preserved pubertal development with Tanner stage III pubic hair and at least Tanner stage IV breast development. Hormonal profile was unremarkable, and chromosomal analysis showed a normal female karyotype (46,XX). Pelvic ultrasonography and computed tomography of the thorax, abdomen, and pelvis demonstrated uterine agenesis. In addition, bilateral oval-shaped heterogeneous soft tissue masses were identified within the paracolic gutters; ultrasonography showed multiple cysts within both masses,

and each was associated with a gonadal vein, suggestive of bilateral ectopic gonadal structures on imaging. These findings were consistent with atypical MRKH syndrome type II in the context of underlying renal anomalies.

#### CONCLUSION

This case highlights the importance of evaluating primary amenorrhea even in patients with significant chronic illness. In phenotypic females with CAKUT, associated Müllerian anomalies should be actively considered. Atypical MRKH syndrome type II should be recognized early to enable accurate diagnosis, multidisciplinary follow-up, and appropriate reproductive and psychosocial counseling.

### EP\_A148

#### ACTIVE MODERATE-TO-SEVERE THYROID EYE DISEASE: A CASE SERIES

Salmi Fatirah Salim<sup>1</sup>, Chee Koon Low<sup>1</sup>, Abdullah Shamshir Abd Mokti<sup>1</sup>, Akmal Haliza Zamli<sup>2</sup>

<sup>1</sup>Endocrine Unit, Department of Internal Medicine, Hospital Tengku Ampuan Afzan

<sup>2</sup>Department of Ophthalmology, Hospital Tengku Ampuan Afzan

#### INTRODUCTION

Thyroid eye disease (TED) is a heterogeneous condition and the most common extrathyroidal manifestation of Graves' disease. Although most cases are mild, disease progression may threaten vision and significantly impact quality of life.

#### METHODOLOGY

We described four patients with active moderate-to-severe TED, highlighting their clinical characteristics, therapeutic approaches, and clinical outcomes.

#### RESULTS

Three males and one female patient were included in this descriptive study. Most were identified by the endocrine team. Their median age was 52.5 years (range 47–56 years). All patients had long-standing Graves' disease (range 6–10 years). Two of them were active smokers. Their clinical activity score ranged from 3 to 5. Common presenting features included diplopia (60%), proptosis (60%), and ocular redness (60%).

At the onset of active TED, all patients were euthyroid while receiving either antithyroid therapy or were maintained on stable levothyroxine following radioactive iodine treatment and thyroidectomy. Thyroid receptor autoantibodies were assessed in only two patients, with one elevated result. Orbital computed tomography, performed in 3 patients, demonstrated extraocular muscle enlargement consistent with TED, particularly involving the inferior and medial recti.

All patients received standard-dose intravenous methylprednisolone (cumulative 3.5–4.5 g). They showed improvement in visual acuity following treatment, with partial improvement in ophthalmoplegia.

#### CONCLUSION

Clinical risk factors observed in this series were consistent with the literature. TED diagnosis relies heavily on recognition by the endocrine team, underscoring the importance of holistic Graves' disease management. High-dose corticosteroids remain the mainstay of treatment in our setting, with generally favorable outcomes when timely multidisciplinary care is provided.

### EP\_A149

#### BEYOND THE PITUITARY STALK: PRIMARY HYPOTHYROIDISM AS A RARE PRESENTATION OF MULTISYSTEM LANGERHANS CELL HISTIOCYTOSIS

Fang Chan Lim<sup>1</sup> and Shireen Siow Leng Lui<sup>2</sup>

<sup>1</sup>Department of Internal Medicine, Hospital Tawau

<sup>2</sup>Endocrinology Unit, Department of Internal Medicine, Hospital Queen Elizabeth II

#### INTRODUCTION

Langerhans cell histiocytosis (LCH) is a clonal proliferative disorder of langerin-positive histiocytes. Endocrine involvement most frequently manifests as central diabetes insipidus or secondary hypothyroidism, caused by infiltration of the hypothalamic-pituitary axis. Conversely, direct infiltration of the thyroid gland leading to primary hypothyroidism is an exceptionally rare clinical entity, particularly when presenting concurrently with central disease.

#### CASE

A 21-year-old female with known right otic and multisystem LCH presented with septic shock secondary to a right ear abscess accompanied by polyuria and polydipsia. Physical examination revealed a palpable goiter. Clinical and biochemical evaluation confirmed central diabetes insipidus with associated anterior hypopituitarism (low adrenocorticotropic hormone, follicle-stimulating hormone, and luteinizing hormone). However, concurrent thyroid function tests demonstrated overt primary hypothyroidism, evidenced by an appropriately elevated thyroid-stimulating hormone (26.19 mIU/L) and low free T4 (5.47 pmol/L), rather than the anticipated secondary hypothyroidism. Neck ultrasound showed diffuse thyroid enlargement with heterogeneous echotexture. Crucially, anti-thyroid peroxidase and anti-thyroglobulin antibodies were both negative, rendering Hashimoto's thyroiditis highly unlikely. Although the patient declined confirmatory

fine-needle aspiration, the constellation of a palpable goiter, characteristic ultrasonographic findings, negative autoimmunity, and active multisystem disease strongly supported a diagnosis of direct histiocytic infiltration of the thyroid gland. She was initiated on appropriate glucocorticoid coverage and subsequent levothyroxine replacement, alongside systemic intravenous cytarabine.

#### CONCLUSION

This case highlights a rare, mixed endocrine profile in multisystem LCH, demonstrating that pituitary and direct end-organ infiltration can coexist. Hypothyroidism in LCH patients with established central diabetes insipidus should not be reflexively assumed to be central in origin. A comprehensive diagnostic workup, including autoantibody screening, ultrasound, and ideally histopathological confirmation, is essential to accurately identify primary endocrine failure and guide appropriate clinical management in these complex cases.

## EP\_A150

### IMMUNE-MEDIATED PANCYTOPENIA ASSOCIATED WITH GRAVES' DISEASE MIMICKING EVANS SYNDROME AND CARBIMAZOLE-INDUCED AGRANULOCYTOSIS

Ahmad Syahmi Yusof Zaki<sup>1,2</sup>, Ezelea Elwina Walter Sandosam<sup>2</sup>, Nur Izat Muhamad<sup>2</sup>, Wan Mohd Izani Wan Mohamed<sup>2</sup>

<sup>1</sup>Faculty of Medicine, University Sultan Zainal Abidin

<sup>2</sup>Department of Internal Medicine, School of Medical Sciences, University Science Malaysia

#### INTRODUCTION

Autoimmune thyroid disease is frequently associated with other immune-mediated disorders; however, clinically significant pancytopenia is rare. In patients with Graves' disease receiving antithyroid therapy, leukopenia raises concern for drug-induced agranulocytosis, a rare but potentially life-threatening complication characterized by severe neutropenia requiring immediate drug withdrawal. The coexistence of hemolytic anemia and thrombocytopenia may instead suggest Evans syndrome, defined by autoimmune hemolytic anemia with immune thrombocytopenia, with or without neutropenia. Importantly, uncontrolled thyrotoxicosis itself may cause immune-mediated cytopenias, creating a diagnostic challenge.

#### CASE

We report a 55-year-old female with thyroid receptor antibody-positive Graves' disease who presented with jaundice and pancytopenia while receiving carbimazole

therapy. Laboratory evaluation demonstrated anemia with reticulocytosis and a positive direct antiglobulin test, thrombocytopenia and leukopenia. Complement testing revealed reduced C3 with normal C4, consistent with immune-mediated hemolysis. Peripheral blood film showed no blast cells or marrow infiltration, and autoimmune screening, including antinuclear antibodies and anti-double stranded DNA, was negative.

The coexistence of Coombs-positive hemolysis and thrombocytopenia initially raised suspicion for Evans syndrome, while leukopenia during carbimazole therapy prompted concern for drug-induced agranulocytosis. However, neutropenia was not severe, and the absence of marrow infiltration or systemic autoimmune disease made alternative causes of pancytopenia less likely. Importantly, blood counts progressively improved following the optimization of thyroid control despite continuation of carbimazole at a reduced dose, without the use of immunosuppressive therapy. This clinical course supported the interpretation of thyrotoxicosis-associated immune cytopenia rather than primary Evans syndrome or carbimazole-induced agranulocytosis.

#### CONCLUSION

This case highlights thyrotoxicosis-associated immune cytopenia as an important mimic of Evans syndrome and carbimazole-related hematological toxicity. Recognizing this entity is essential to avoid unnecessary discontinuation of antithyroid therapy or inappropriate immunosuppressive treatment.

## EP\_A151

### COLD SPOT WITHIN A HOT NODULE: THYROID STORM FROM TOXIC ADENOMA REVEALING RARE HURTHLE CELL ADENOMA

Ying Guat Ooi<sup>1</sup>, Jun Kit Khoo<sup>1</sup>, Tharsini Sarvanandan<sup>1</sup>, Quan Hziung Lim<sup>1</sup>, Jeyakantha Ratnasingam<sup>1</sup>, Lee Ling Lim<sup>1</sup>, Shireene Ratna Vethakkan<sup>1</sup>, Nicholas Ken Yoong Hee<sup>1</sup>

<sup>1</sup>Endocrine Unit, Department of Medicine, Faculty of Medicine, University Malaya

#### INTRODUCTION

Hurthle cell adenoma is a rare benign thyroid neoplasm that can only be diagnosed through histopathological examination. Hurthle cell neoplasm typically presents as nonfunctioning cold nodule on thyroid scintigraphy. We report a rare case of Hurthle cell adenoma presenting with thyroid storm, with unusual findings of "cold" within "hot" thyroid nodule on scintigraphy.

## CASE

A 73-year-old male with hypertension, chronic kidney disease, coronary artery disease, and Parkinson's disease presented to the emergency department with fever and diarrhea. His temperature was 38.4°C, heart rate 106 bpm, and blood pressure 138/75 mmHg, with atrial fibrillation and signs of heart failure. The Burch-Wartofsky score was 50, consistent with thyroid storm.

Laboratory tests revealed free thyroxine 4 37.8 pmol/L (NR 11.5–22.7), free thyroxine 3 5.6 pmol/L (NR 3.5–6.5), and thyroid-stimulating hormone <0.01 mIU/L (NR 0.55–4.78). Thyroid autoantibodies, including anti-thyroid peroxidase, anti-thyroglobulin, and thyroid-stimulating immunoglobulins, were negative (<0.10 IU/L). The thyroid storm was precipitated by invasive *Klebsiella* syndrome with endophthalmitis and lung and liver abscess. He was treated with Lugol's iodine, corticosteroid, antibiotics, and carbimazole.

Ultrasound thyroid revealed a mixed cystic-solid nodule in the left thyroid lobe, measuring 2.3 × 3.3 × 4.3 cm (TI-RADS category 3). Technetium-99m thyroid scintigraphy demonstrated a hyperfunctioning left thyroid nodule with a focal intranodular cold spot measuring 5.0 × 3.7 cm. Fine needle aspiration cytology of the nodule was benign follicular cells. Following stabilization with anti-thyroid treatment, he underwent left hemithyroidectomy. Histopathology examination revealed a Hurthle cell adenoma without capsular or vascular invasion.

Postoperatively, he remained clinically euthyroid. Surveillance ultrasound performed 8 months later showed a normal right thyroid lobe, and lifelong surveillance was planned.

## CONCLUSION

This case illustrates a rare and unusual presentation of thyroid storm caused by a toxic Hurthle cell adenoma containing an intranodular cold spot on scintigraphy. To our knowledge, only one similar case has been reported in the literature, and our case is the first to present with thyroid storm.

## EP\_A152

### ACUTE THYROID PAIN IN PREGNANCY: PAINFUL HASHIMOTO'S THYROIDITIS VERSUS SUBACUTE THYROIDITIS— A CASE REPORT

**Hamizah Hamzah<sup>1</sup>, Sarojini Devi Simanchalam<sup>1</sup>, Wong Poh Shean<sup>1</sup>, Nor Afidah Karim<sup>1</sup>, Noor Lita Adam<sup>1</sup>**

<sup>1</sup>Endocrine Unit, Medical Department, Hospital Tuanku Ja'afar Seremban

## INTRODUCTION

Painful Hashimoto's thyroiditis is a rare and atypical form of autoimmune thyroid disease characterized by thyroid pain and tenderness. It can closely resemble subacute thyroiditis and must be distinguished from other causes of thyroid pain, including hemorrhage into a cyst and thyroid abscess. This distinction is particularly important in pregnancy, where radionuclide imaging is not recommended.

## CASE

A 27-year-old pregnant female (G4P3) at 24 weeks' gestation, with Southeast Asian ovalocytosis and diet-controlled gestational diabetes, was diagnosed with primary hypothyroidism at 14 weeks following evaluation of a painless goiter. Initial tests showed markedly elevated thyroid-stimulating hormone (>150 mIU/L), low free thyroxine (3.5 pmol/L), and positive anti-thyroid peroxidase antibodies (319 IU/mL), consistent with Hashimoto's thyroiditis. Levothyroxine therapy achieved biochemical euthyroidism.

At 24 weeks, she developed acute right-sided anterior neck pain radiating to the ear, with dysphagia, odynophagia, and fever. Examination revealed a tender thyroid without lymphadenopathy. Ultrasound demonstrated diffuse enlargement with bilateral ill-defined hypoechoic avascular areas. Inflammatory markers showed markedly elevated C-reactive protein (184 mg/L) with a normal erythrocyte sedimentation rate (16 mm/h), while thyroid function remained within target range. Imaging and clinical findings made abscess and hemorrhage unlikely.

The presence of pre-existing autoimmune thyroid disease, antibody positivity, and hypothyroidism before symptom onset supported painful Hashimoto's thyroiditis over subacute thyroiditis. This case highlights that normal thyroid function tests do not necessarily indicate disease remission, as inflammatory activity may persist independently of hormone levels.

## CONCLUSION

Painful Hashimoto's thyroiditis should be considered in pregnant patients with known autoimmune thyroid disease presenting with acute thyroid pain despite normal thyroid function. Diagnosis requires integration of clinical, biochemical, and imaging findings to guide appropriate management.

## EP\_A153

### THE HIDDEN HAZARD AFTER TOTAL PARATHYROIDECTOMY: A CASE REPORT

Jie En Tan<sup>1</sup> and Chin Voon Tong<sup>1</sup>

<sup>1</sup>Institut Endokrin, Hospital Putrajaya

#### INTRODUCTION

Palpation thyroiditis is an underrecognized condition that occurs after parathyroidectomy. Symptoms range from mild to overt thyrotoxicosis that may result in life-threatening cardiac arrhythmias and acute coronary syndrome. Diagnosis is made by having suppressed thyroid-stimulating hormone (TSH) and elevated free thyroxine 4 (fT4) or free thyroxine 3 (fT3) and low radionuclide uptake on thyroid scan.

#### CASE

We report a case of a 72-year-old female with underlying end-stage renal disease on regular hemodialysis who underwent total parathyroidectomy for tertiary hyperparathyroidism. Her thyroid function test (TFT) pre-operatively was normal, and cardiac assessment showed normal echocardiogram findings and sinus rhythm on electrocardiogram. Her operation was uncomplicated, involving neck exploration and all 4-gland removal. Postoperatively, she had new-onset atrial fibrillation (AF) with rapid ventricular response at day 5, requiring electrical and chemical cardioversion. She had recurrent tachyarrhythmias on day 6. Her repeated TFT showed suppressed TSH, 0.036 mIU/L (NR 0.38–5.33) and raised fT4, 35.4 pmol/L (NR 7.9–14.4), fT3–fT4 ratio 0.26 (<0.3), consistent with thyrotoxicosis. She was treated as thyroid storm (Burch-Wartofsky Point Scale 45), after ruling out other causes. She was started on glucocorticoids, propylthiouracil, and Lugol's iodine. Despite biochemical improvement, she continued to develop recurrent AF up till Day 12 post-op, requiring multimodal treatment, including beta-blocker and antiarrhythmic agents. She was later discharged well on low-dose carbimazole. Her ultrasound neck showed a normal thyroid gland, and her thyroid antibodies were negative.

## CONCLUSION

A high level of suspicion is needed to detect thyroiditis post-parathyroidectomy due to its potential adverse impact on surgical outcomes. Treatment is mainly symptomatic, and the disease is self-limiting. Risk factors identified include secondary/tertiary hyperparathyroidism and bilateral neck exploration that involves manipulation of the thyroid gland.

## EP\_A154

### SUBACUTE HYPOTHYROID MYOPATHY AS AN ATYPICAL PRESENTATION FOLLOWING RADIOIODINE THERAPY

Thesapiriya Jeyapal<sup>1</sup>, Nur Aini Eddy Warman<sup>1</sup>, Nur Haziqah Baharum<sup>1</sup>, Aimi Fadilah Mohamad<sup>1</sup>, Mohd Hazriq Awang<sup>1</sup>, Fatimah Zaherah Mohamed Shah<sup>1</sup>, Rohana Abdul Ghani<sup>1</sup>

<sup>1</sup>Department of Internal Medicine, Faculty of Medicine, Universiti Teknologi MARA

#### INTRODUCTION

Hypothyroidism is the most common outcome following radioiodine (RAI) therapy for Graves' disease, affecting up to 80% of patients, usually within 6 months. While symptoms are often nonspecific, musculoskeletal complaints may be the predominant or sole manifestation. Hypothyroid myopathy occurs in 30–80% of patients, typically causing myalgias, cramps, fatigue, and slowly progressive, symmetric proximal weakness with delayed reflex relaxation. We report an atypical case with subacute and evolving weakness after levothyroxine initiation.

#### CASE

A 43-year-old female with Graves' disease underwent RAI therapy (25 mCi) and developed hypothyroidism 7 weeks later. She was started on levothyroxine 50 mcg daily. Two weeks into treatment, she presented with progressive proximal lower limb weakness (power 4/5), while distal strength and reflexes remained intact. Labs revealed elevated creatine kinase (259 U/L), hypokalemia (3.3 mmol/L), creatinine (57 µmol/L), and severe hypothyroidism (thyroid-stimulating hormone [TSH] 52.88 mIU/L, free thyroxine 4 [FT4] 7.79 pmol/L). Levothyroxine was increased to 100 mcg daily. Two weeks later, she developed proximal upper limb weakness (power 4/5), while lower limb strength had normalized. Nerve conduction studies and electromyography were unremarkable. Labs showed creatine kinase (244 U/L) and creatinine (58 µmol/L). As she remained hypothyroid (TSH 20.85 mIU/L, FT4 11.61 pmol/L), levothyroxine 100 mcg daily was continued. Her symptoms gradually improved alongside biochemical recovery (TSH 8.83 mIU/L, FT4 15.90 pmol/L) after 4 weeks, consistent with hypothyroid myopathy.

## CONCLUSION

This case highlights an atypical subacute presentation of hypothyroid myopathy following RAI, with evolving weakness and transient worsening after starting thyroid hormone therapy. Although other serious causes should be excluded, clinicians must maintain a high index of suspicion to avoid unnecessary investigations and ensure timely optimization of thyroid hormone therapy, as clinical improvement parallels biochemical recovery.

## EP\_A155

### HASHIMOTO'S THYROIDITIS PRESENTING WITH RECURRENT MASSIVE PLEURAL EFFUSION SUGGESTIVE OF LYMPHOCYTIC INTERSTITIAL PNEUMONITIS

Endah Pratamaningtias<sup>1</sup> and Nyoman Satvika Dharma Yudha<sup>1</sup>

<sup>1</sup>Division of Endocrinology, Metabolism and Diabetes, Department of Internal Medicine, Saiful Anwar Hospital-Faculty of Medicine Brawijaya University, Indonesia

## INTRODUCTION

Hashimoto's thyroiditis is a common autoimmune thyroid disease; however, pulmonary involvement is a rare manifestation. Lymphocytic interstitial pneumonitis is commonly associated with autoimmune diseases, but its association with Hashimoto's thyroiditis remains poorly understood.

## CASE

A 63-year-old male with prior diagnosis of Hashimoto's thyroiditis presented with recurrent massive pleural effusion and progressive dyspnea. He also experienced fatigue, cold intolerance, and constipation. Physical examination revealed facial puffiness, diffuse goiter, and dry skin. Thyroid function tests performed 6 months before admission confirmed overt hypothyroidism (thyroid-stimulating hormone [TSH] 80.30  $\mu$ IU/mL, free thyroxine 4 [FT4] 0.46 ng/dL). One month prior to admission, laboratory findings showed subclinical hypothyroidism (TSH 9.09  $\mu$ IU/mL, FT4 1.42 ng/dL). Despite levothyroxine treatment TSH levels remained elevated at 21.8  $\mu$ IU/mL during admission. Anti-thyroid peroxidase antibodies were positive (13.95 IU/mL). Repeated thoracentesis revealed exudative pleural effusion with lymphocytic predominance and no evidence of malignancy in cytological examination. Infectious etiologies and malignancy were ruled out. Thyroid ultrasonography demonstrated diffuse hypoechoic enlargement of the thyroid gland. Chest radiography showed massive unilateral pleural effusion, while thoracic computed tomography revealed ground-glass opacities with a reticulogranular pattern and interlobular septal

thickening, accompanied by multiple thin-walled cysts, highly suggestive of lymphocytic interstitial pneumonitis. Thyroid immunohistochemical analysis was performed (CD 20, CD 3, CD 10, CD 138, Ki 67, BCL 2, BCL 6, Thyroglobulin, MUM 1, Cyclin D1), consistent with lymphocytic thyroiditis. Significant clinical and laboratory improvement was achieved after combined treatment with levothyroxine and corticosteroid.

## CONCLUSION

This case underscores the importance of considering autoimmune-related lymphocytic interstitial pneumonitis in patients with Hashimoto's thyroiditis who present with unexplained recurrent pleural effusion after exclusion of more common etiologies, such as infection and malignancy. Early recognition may lead to favorable improvement.

## EP\_A156

### A RARE CASE OF COMPLETE HEART BLOCK SECONDARY TO NON-AUTOIMMUNE NON-FAMILIAL FORM OF THYROTOXICOSIS

Ket Meng Chin<sup>1</sup>, Katherine Khor<sup>2</sup>, Nor Azmi Kamaruddin<sup>3</sup>

<sup>1</sup>Department of Internal Medicine, Hospital Tuanku Fauziah

<sup>2</sup>Department of Endocrinology, Hospital Tuanku Fauziah

<sup>3</sup>Department of Cardiology, Institut Jantung Negara

## INTRODUCTION

Thyrotoxicosis typically manifests as a hypermetabolic state characterized by tachyarrhythmias, such as sinus tachycardia or atrial fibrillation. Bradyarrhythmia, specifically atrioventricular block (AVB), is a rare and atypical cardiac manifestation. While Graves' disease is the leading cause of hyperthyroidism, non-autoimmune etiologies must be considered when thyroid-stimulating antibodies are absent. The exact mechanism for AVB in thyrotoxicosis remains unclear but may involve myocardial inflammation of the conduction system or autonomic dysfunction.

## CASE

A 16-year-old male with no previous medical history presented with a sudden syncopal attack. Clinical evaluation revealed a complete heart block (CHB) in association with biochemical evidence of thyrotoxicosis, requiring a temporary transcutaneous pacemaker insertion. There were no features of Graves' disease, such as exophthalmos and thyroid acropachy, and further investigation showed a negative thyroid receptor antibody (TRAb) titer with no family history of thyroid disorders. Thyroid ultrasonography showed increased vascularity, while scintigraphy imaging showed diffuse, homogeneous, and increased uptake in both thyroid lobes. The combination of

negative serology and the absence of a family history, along with a hyperfunctional state on imaging, likely suggests a rare presentation of sporadic, non-autoimmune, non-familial form of thyrotoxicosis. Following the initiation of anti-thyroid therapy, the CHB completely resolved without the need for further cardiological intervention. He achieved a complete clinical remission after a few months and is being planned for radioactive iodine therapy.

#### CONCLUSION

Most of the thyrotoxicosis-associated CHB reported in the literature was due to Graves' disease or some forms of autoimmune thyrotoxicosis, with auto-antibodies and activated lymphocytes having a role in the pathogenesis of the CHB. CHB in association with a non-autoimmune, non-familial form of thyrotoxicosis is indeed rare, and as this case illustrates, it completely went into spontaneous sinus rhythm upon initiation of conventional anti-thyroid therapy. This rare presentation of CHB is believed to have a benign clinical course.

### EP\_A157

#### STEROID-RESPONSIVE ENCEPHALOPATHY ASSOCIATED WITH THYROIDITIS

**Chua Chong Yee<sup>1</sup>, Nur Haziqah Baharum<sup>2</sup>, Fadzliana Hanum Jalal<sup>3</sup>, Gunavathy Muthusamy<sup>1</sup>**

<sup>1</sup>Department of Internal Medicine, Hospital Shah Alam

<sup>2</sup>Hospital Al-Sultan Abdullah UiTM

<sup>3</sup>Avisena Specialist Hospital

#### INTRODUCTION

Steroid-responsive encephalopathy associated with thyroiditis (STREAT) is a rare clinical entity. Clinical presentations of STREAT can range from a stroke-like presentation to psychiatric symptoms. STREAT is diagnosed based on four major criteria which include altered cognitive function, new or worsening psychiatric symptoms, elevated antithyroid antibodies, and exclusion of infectious, toxic, metabolic, or neoplastic causes. Corticosteroids are the cornerstone of treatment, with reported excellent response in neurocognitive symptoms resolution.

#### CASE

This was a case of a 48-year-old male with Graves's disease who underwent radioiodine therapy 4 months earlier and was started on levothyroxine 100 mcg 2 weeks prior to presentation. He presented with 4 days of behavioral symptoms, irritable mood with auditory and visual hallucinations. There was no history of fever, headache, limb weakness, or seizure. On general appearance, the patient was agitated, talking incoherently, and disorientated with normal vitals. There was no delayed relaxation of the reflex.

The examination of the cranial nerve, motor, sensory, and cerebellar system was normal. A lumbar puncture showed normal opening pressure with a high protein CSF content of 1,596 mg/L. The thyroid-stimulating hormone (TSH) was elevated at 72.7 uIU/mL and T4 at 9.56 pmol/L. Serum anti-thyroid peroxidase was elevated at 877.42 IU/mL, and anti-TSH receptor antibody at 21.30 IU/L. CSF oligoclonal band, serum aquaporin-4, and viral screening were negative; non-contrasted computed tomography brain revealed normal findings. Based on the clinical history and examination, a diagnosis of STREAT was made at the emergency department. The patient was initiated on hydrocortisone 100 mg three times a day. Within 24–48 hours of steroid therapy, marked improvement and subsequent resolution of the mental status and behavioral symptoms were seen.

#### CONCLUSION

Hashimoto's thyroiditis can rarely lead to STREAT, a condition with diverse neurological manifestations, where early recognition and prompt corticosteroid therapy are essential for favorable outcomes.

### EP\_A158

#### MUSCLE WEAKNESS IN THYROID DISEASE: WHEN IT IS NOT THYROTOXIC MYOPATHY?

**Hamizah Hamzah<sup>1</sup>, Sarojini Devi Simanchalam<sup>1</sup>, Yap Yon Lek<sup>2</sup>, Wong Poh Shean<sup>1</sup>, Nor Afidah Karim<sup>1</sup>, Nadiyah Mohd Noor<sup>1</sup>, Noor Lita Adam<sup>1</sup>**

<sup>1</sup>Endocrinology Unit, Department of Medicine, Hospital Tuanku Ja'afar Seremban

<sup>2</sup>Rheumatology Unit, Department of Medicine, Hospital Tuanku Ja'afar Seremban

#### INTRODUCTION

Muscle weakness in thyroid disease is commonly attributed to thyrotoxic myopathy or hypokalemic periodic paralysis. Nevertheless, autoimmune conditions such as idiopathic inflammatory myopathies (IIM) and myasthenia gravis (MG) should be considered, as they may coexist with Graves' disease.

#### CASE

A 54-year-old female with hypertension and Graves' disease, treated with carbimazole for 2 years, had her therapy discontinued after remission. She was restarted on low-dose carbimazole following symptom recurrence. Three weeks later, she developed progressive proximal weakness, dysphagia, hoarseness, anorexia, and weight loss. On examination, body mass index was 22 kg/m<sup>2</sup> with mild proptosis, symmetrical proximal weakness (MRC 4/5), and erythematous rashes on thighs and shins. Otorhinolaryngology evaluation confirmed bilateral vocal

cord palsy. Investigations revealed markedly elevated creatine kinase (7,950 U/L), aspartate aminotransferase (349 U/L), and alanine aminotransferase (179 U/L), with euthyroid biochemistry (thyroid-stimulating hormone 5.21 mIU/L, free thyroxine 4 16.6 pmol/L). Hypokalemia correction failed to improve symptoms, excluding periodic paralysis. ANA, C3, and C4 were normal. Myositis panel showed strong anti-Cytosolic 5'-nucleotidase 1A positivity with borderline anti-Ro-52. A diagnosis of IIM with bulbar involvement was made. She was treated with intravenous methylprednisolone and intravenous immunoglobulin, with clinical improvement.

#### CONCLUSION

This case highlights the diagnostic challenge of muscle weakness in thyroid disease. While thyrotoxic myopathy is often presumed, markedly elevated creatinine kinase, rash, and bulbar involvement should prompt suspicion of IIM. Early immunosuppressive therapy is essential to achieve favorable outcomes.

## EP\_A159

### GRAVES' DISEASE PRESENTING WITH PANCYTOPENIA: A RARE REVERSIBLE HEMATOLOGICAL ABNORMALITY IN THYROTOXICOSIS

Wei Ton Wong<sup>1</sup>, Che Azzah Hanim Che Yahya<sup>1</sup>, Nurul Atikah Abdul Aziz<sup>1</sup>

<sup>1</sup>Internal Medicine Unit, Hospital Besut

#### INTRODUCTION

Graves' disease is associated with various hematological abnormalities, including anemia, leucopenia, and thrombocytopenia. However, pancytopenia involving all three cell lines is a rare and often under-recognized manifestation of thyrotoxicosis. We present a case of newly diagnosed Graves' disease complicated by pancytopenia, in which cell counts normalized rapidly following carbimazole initiation.

#### CASE

A 51-year-old female with underlying type 2 diabetes mellitus, hypertension, and dyslipidemia presented with dysphagia for 3 months, significant weight loss (from 95 to 75 kg over 6 months), and a 1-week history of fever, palpitations, tremors, orthopnea, and bilateral lower limb swelling. On examination, she was febrile (38.2°C) with bibasal crepitations, pitting edema up to the mid-shins, bilateral hand tremors, and a multinodular neck mass moving with deglutition. Investigations confirmed

thyrotoxicosis (thyroid-stimulating hormone [TSH] 0.01 mIU/L, free T4 130.1 pmol/L, T3 >30.8 pmol/L) with positive autoantibodies (thyroid receptor antibody 31.9 IU/L, anti-thyroid peroxidase 195 IU/mL). Full blood count showed pancytopenia: white cell count  $2.73 \times 10^9/L$ , hemoglobin 10.3 g/dL, and platelets  $108 \times 10^9/L$ . Peripheral blood film suggested normocytic normochromic anemia with leucopenia and thrombocytopenia. Chest radiography showed cardiomegaly with fluid overload, and echocardiography revealed an ejection fraction of 77%. She was treated for impending thyroid storm secondary to pneumonia with Lugol's iodine, hydrocortisone, propylthiouracil, and intravenous antibiotics. She was discharged on day 3 with a transition to carbimazole. At outpatient follow-up approximately 9 days later, thyroid function had improved significantly (free thyroxine 4 reduced from 130.1 to 29.34 pmol/L with suppressed TSH), and repeat full blood count demonstrated complete normalization of all three cell lines.

#### CONCLUSION

This case illustrates that pancytopenia can be a direct consequence of severe thyrotoxicosis and may reverse completely with effective antithyroid therapy. The temporal relationship between biochemical improvement and hematological recovery supports a causal link. Clinicians should be aware of this rare association to avoid misdiagnosis and unnecessary invasive investigations.

## EP\_A160

### A COSTLY ASSUMPTION: MISINTERPRETATION OF THYROID FUNCTION TESTS DELAYING GUILLAIN-BARRÉ SYNDROME DIAGNOSIS IN PREGNANCY

Chen Huey Ng<sup>1</sup> and Wei Ton Wong<sup>2</sup>

<sup>1</sup>Hospital Sultan Ismail Petra

<sup>2</sup>Hospital Besut

#### INTRODUCTION

A common diagnostic error is the tendency to attribute new symptoms directly to the most obvious laboratory abnormality. In pregnancy, a suppressed thyroid-stimulating hormone (TSH) with elevated free T4 is frequently presumed to indicate primary hyperthyroidism, overlooking the possibility of benign gestational transient thyrotoxicosis (GTT). We report a case where this pattern led to the misattribution of acute flaccid paralysis to thyrotoxic periodic paralysis, critically delaying the diagnosis of Guillain-Barré syndrome (GBS).

#### CASE

A 21-year-old female Malay primigravida at 19 weeks and 5 days presented with a 2-week history of progressive, descending bilateral lower limb weakness culminating in paralysis, associated with vomiting and 5 kg weight loss. On admission, she was febrile (38.0°C) and tachycardic (150 bpm). Neurological examination revealed proximal-predominant flaccid paralysis and hyporeflexia with intact sensation, without thyroid eye signs or goiter. Thyroid function tests showed profound thyrotoxicosis (TSH <0.005 mIU/L, free thyroxine 4 20.16 pmol/L) with hypokalemia (2.9 mmol/L). A neck ultrasound was normal. A provisional diagnosis of thyrotoxic periodic paralysis with impending storm was made, leading to treatment with potassium replacement, propylthiouracil, and hydrocortisone. Despite biochemical improvement, her paralysis persisted. On day 5, she developed acute bulbar palsy and respiratory failure requiring intubation. A subsequent comprehensive workup for infectious, autoimmune (including thyroid antibodies), and nutritional causes was unremarkable. Nerve conduction studies confirmed the acute motor axonal neuropathy (AMAN) variant of GBS. Treatment with a 5-day course of intravenous immunoglobulin resulted in neurological improvement and successful extubation.

#### CONCLUSION

This case highlights the critical pitfall of prematurely attributing acute neurological deficits to abnormal thyroid function tests in pregnancy. Biochemical thyrotoxicosis, including GTT, should not preclude urgent evaluation for life-threatening neurological conditions such as GBS, particularly when weakness is progressive or refractory to metabolic correction.

### EP\_A161

#### BETA BLOCKER-INDUCED RAYNAUD PHENOMENON IN A CASE OF GRAVES' DISEASE

Lui Tjun Yew<sup>1</sup> and Gerard Jason Mathews<sup>1</sup>

<sup>1</sup>Hospital Canselor Tuanku Muhriz UKM

#### INTRODUCTION

Beta-blockers are frequently used as adjunctive therapy in hyperthyroidism to manage adrenergic symptoms, yet their potential to precipitate secondary Raynaud's phenomenon remains under-recognized. This adverse effect is attributed to  $\beta_2$ -adrenoceptor blockade, which impairs peripheral vasodilation and promotes reflex vasoconstriction. Non-selective agents such as propranolol carry this particular risk.

#### CASE

A 22-year-old female presented with a 6-month history of palpitations, 11 kg weight loss, and fine tremors. There was no personal or family history of autoimmune or connective tissue disease. She denied any malar rash, joint swelling, alopecia, myopathy, oral ulcers, or uveitis. She also denied using any supplements or any herbal or traditional remedies. Examination revealed tachycardia, fine tremors, and Graves' ophthalmopathy, but no acropachy or organomegaly. Investigations confirmed Graves' disease: Free T4 of 73 pmol/L, thyroid-stimulating hormone <0.05 mIU/L, with elevated anti-thyroid peroxidase and anti-thyroglobulin antibodies. Full blood count, renal, and liver function were unremarkable.

She was commenced on carbimazole 20 mg daily and propranolol 40 mg three times daily. After 8 months of treatment, she developed cold-induced digital color changes and skin tightening consistently, suggestive of Raynaud's phenomenon. Dose reduction of propranolol to 20 mg BD only yielded partial improvement. Propranolol was subsequently substituted with verapamil, a non-dihydropyridine calcium channel blocker, resulting in significant resolution of Raynaud's phenomenon.

#### CONCLUSION

Propranolol-induced Raynaud's phenomenon is an under-recognized complication in the management of Graves' disease, and this case illustrates that it may develop insidiously after months of therapy and can persist despite dose reduction. Substitution with verapamil achieves rate control without  $\beta_2$ -adrenergic antagonism. Clinicians should maintain a low threshold for recognizing this adverse effect and consider early substitution with verapamil in affected patients. While verapamil does not confer the same adrenergic blockade as propranolol, its vasodilatory properties make it a rational and effective alternative in this context.

## EP\_A162

### LYMPHOCYTIC TURNED LYMPHOMATOUS: A CASE OF HASHIMOTO'S THYROIDITIS

Suprhamanyam Evali<sup>1</sup>, Amie-Anne Augustine<sup>1</sup>,  
Shamharini Nagaratnam<sup>1</sup>

<sup>1</sup>Endocrine Institute, Hospital Putrajaya

#### INTRODUCTION

Primary thyroid lymphoma (PTL) is a rare malignancy representing 1–5% of all thyroid cancers, most frequently arising on a background of chronic autoimmune thyroiditis.

#### CASE

We report a 73-year-old Malay male who initially presented with large goiter, symptomatic bradycardia, and subsequently developed severe primary hypothyroidism (thyroid-stimulating hormone 231 mIU/L, anti-thyroid peroxidase 643 IU/mL), consistent with Hashimoto's thyroiditis. During his clinical course, he also sustained a non-ST elevation Myocardial Infarction which was attributed to demand-supply mismatch of hypothyroidism. Computed tomography scan of the neck revealed a large multinodular goiter with retrosternal extension, tracheal compression, and extensive nodal lymphadenopathy. Initial Fine needle biopsy was non-diagnostic, but a repeat biopsy was performed due to rapidly enlarging goiter within weeks with suspicious nodules seen on bedside thyroid ultrasound. Ultrasound-guided core biopsy confirmed Diffuse Large B-cell Lymphoma (DLBCL), non-germinal centre B-cell (non-GCB) subtype. Despite initiation of levothyroxine and corticosteroid therapy, the patient deteriorated with remarkable rapidity over the ensuing weeks, culminating in a 15 × 10 cm compressive neck mass, Type 1 respiratory failure, hypercalcemia, complete dysphagia, and concurrent pneumonia. He was then transferred to hematology tertiary centre for commencement of his chemotherapy.

#### CONCLUSION

This case of PTL presenting in the background of Hashimoto's thyroiditis emphasizes the role of early tissue diagnosis in patients with rapidly enlarging goiter. Identification of PTL is critical because management shifts from surgical intervention to systemic chemotherapy.

## EP\_A163

### DISCORDANT TFT AFTER TOTAL THYROIDECTOMY: CHALLENGES OF DIAGNOSING RESISTANCE TO THYROID HORMONE

Tan Jia Miao<sup>1</sup>, Pavai Sthaneshwar<sup>2</sup>, Shireene Ratna  
Vethakkan<sup>1</sup>

<sup>1</sup>Endocrine Unit, Department of Medicine, University Malaya

<sup>2</sup>Chemical Pathology Unit, Department of Pathology, University Malaya

#### INTRODUCTION

Thyroid hormone resistance syndrome (THR) is a disorder characterized by reduced responsiveness of target tissues to thyroid hormones with non-suppressed thyroid-stimulating hormone (TSH) despite elevated free thyroxine 4 (FT4). Diagnosing and managing THR in athyreotic patients, however, is challenging; indeed, TSH levels post thyroidectomy for Differentiated Thyroid Carcinoma in patients with THR have been reported to reach levels as high as 112.59 mIU/L despite high-dose thyroxine-suppressive therapy. This case highlights the complexities in diagnosing Resistance to Thyroid Hormone (RTH) post-thyroidectomy.

#### CASE

A 63-year-old female with end-stage renal failure (ESRF) on hemodialysis and prior parathyroidectomy for tertiary hyperparathyroidism underwent total thyroidectomy in 1997 for presumed benign goiter. Following surgery, she demonstrated persistently elevated TSH, ranging from 93.2 to 670.4 mIU/L (0.55–4.78 mIU/L), with normal to mildly elevated FT4 levels, ranging from 17 to 35 pmol/L (11.5–22.7 pmol/L), while on thyroxine replacement doses as low as 0.86 ug/kg. Discordant thyroid function tests (TFTs) were consistent across different assay platforms. Polyethylene glycol precipitation excluded macro-TSH interference.

Intermittent levothyroxine increments suppressed TSH but led to thyrotoxic symptoms, including weight loss, heat intolerance, insomnia, and fragility fracture. Uncontrasted pituitary magnetic resonance imaging (risk of nephrogenic systemic fibrosis with gadolinium in ESRF) showed a small pituitary gland without adenoma, excluding TSH-oma. T3 suppression test was relatively contraindicated due to her advanced age and co-morbidities. There was no family history of thyroid disorder; the patient's only child had a normal TFT, and her parents/siblings could not be tested. A working diagnosis of RTH $\beta$  was made. She declined genetic testing for RTH. She is currently on levothyroxine 50 mcg OD (1.07 ug/kg) with FT4 16.1 pmol/L and TSH 562 mIU/L with no symptoms/signs of hypo or hyperthyroidism.

## CONCLUSION

This case highlights the diagnostic challenges in managing possible RTH $\beta$  post-total thyroidectomy. Treatment should be guided by clinical status and target of mid-to-normal FT4 rather than TSH to avoid iatrogenic thyrotoxicosis.

## EP\_A164

### FROM STABILITY TO STORM: THYROID STORM AFTER A DECADE OF ANTITHYROID DRUG

Jun Kit Khoo<sup>1</sup>, Tharsini Sarvanandan<sup>1</sup>, Ying Guat Ooi<sup>1</sup>, Quan Hziung Lim<sup>1</sup>, Carolyn Wai Ling Chee<sup>1</sup>, Lee Ling Lim<sup>1</sup>, Jeyakantha Ratnasingam<sup>1</sup>, Shireene Ratna Vethakkan<sup>1</sup>, Nicholas Ken Yoong Hee<sup>1</sup>

<sup>1</sup>Endocrine Unit, Department of Medicine, Faculty of Medicine, University Malaya

## INTRODUCTION

Long-term antithyroid drug (LT-ATD) has emerged as a feasible treatment strategy for patients who decline radioactive iodine (RAI) or thyroidectomy for relapsed or refractory Graves' disease (GD). Benefits include faster achievement of euthyroidism, lower risk of hypothyroidism, a more favorable cardiovascular profile, and avoidance of surgical risks. Although fluctuations in thyroid status may occur despite good compliance, thyroid storm is exceedingly rare in patients on LT-ATD. While there is no specific data on the incidence of thyroid storm in this cohort, surveys suggest an overall low incidence (0.2–0.76 cases per 100,000 annually). We report a patient with stable GD who developed a thyroid storm despite more than 10 years of LT-ATD.

## CASE

A 40-year-old female was diagnosed with GD 11 years earlier during pregnancy. Treatment was stopped at 25 weeks' gestation, but she relapsed at 7 months postpartum and was started on carbimazole. She declined RAI or surgery following a relapse and remained on carbimazole 5–10 mg daily, with good compliance. She presented with a 1-day history of fever, cough, rhinorrhea, diarrhea, and palpitations. She was compliant with carbimazole 5 mg daily. On presentation, BP was 132/70 mmHg, HR 140 bpm, temperature 38.5°C, and SpO<sub>2</sub> 98% on air. She was alert without agitation, had a diffuse goiter, mild proptosis, and conjunctival injection, with otherwise normal findings. Electrocardiogram showed sinus tachycardia. Laboratory investigations demonstrated mild transaminitis, leukocytosis, markedly elevated free T<sub>4</sub> (>154 pmol/L), suppressed thyroid-stimulating hormone (<0.008 mIU/L), and elevated thyroid-stimulating immunoglobulin (2.25

IU/L, reference <0.55). Thyroid function tests 1 month ago was normal. Her Burch-Wartofsky score was 60, consistent with thyroid storm, likely precipitated by upper respiratory tract infection. She improved with treatment and was discharged with carbimazole 30 mg daily with planned tapering, subsequently agreeing to RAI as definitive treatment.

## CONCLUSION

Infection may trigger thyroid storm despite good compliance with LT-ATD. Patients should be counselled regarding this risk and advised to seek early medical attention if thyrotoxic symptoms recur.

## EP\_A165

### UNEXPECTED CARDIOVASCULAR COLLAPSE AFTER RADIOIODINE THERAPY IN A PATIENT WITH SEVERE GRAVES' CARDIOMYOPATHY

Choon Peng Sun<sup>1</sup> and Ahmad Affan Bin Hassannuddin<sup>1</sup>

<sup>1</sup>Hospital Teluk Intan

## INTRODUCTION

Graves' disease may lead to thyrotoxic cardiomyopathy, a potentially reversible condition following restoration of euthyroidism. Radioiodine (RAI) therapy is commonly used as definitive treatment for patients with long-standing Graves' disease or poor compliance with antithyroid medications. However, individuals with severe underlying cardiomyopathy may remain vulnerable to cardiovascular instability during the peri-treatment period.

## CASE

We report a 39-year-old male with a 10-year history of Graves' disease who had previously defaulted on follow-up and was admitted with thyroid storm. Echocardiography during that admission demonstrated severe dilated cardiomyopathy with global hypokinesia and an ejection fraction (EF) of 26%. Following treatment with carbimazole and propranolol, he achieved biochemical euthyroidism and remained clinically stable (NYHA class I). In view of his long-standing disease and prior thyroid storm, he underwent RAI therapy as definitive therapy as per the guidelines.

One week following RAI, he developed a persistent cough and progressive dyspnea. Six weeks later, he presented to the emergency department with hypotension (BP 60/31 mmHg) and new-onset atrial fibrillation (heart rate 100 bpm), requiring intubation and inotropic support for cardiogenic shock. Laboratory evaluation showed low free

T4 (5.31 pmol/L) with normal thyroid-stimulating hormone (2.1 mIU/L). Repeat echocardiography demonstrated persistent severe left ventricular dysfunction (EF ~25%) without new structural abnormalities. The patient improved rapidly with supportive management and was successfully extubated after stabilization.

Although RAI is considered a safe and effective definitive therapy, transient thyroid hormone fluctuations and inflammatory thyroid destruction may occur following treatment. In patients with severe pre-existing cardiomyopathy, these physiological changes may precipitate arrhythmias or acute cardiac decompensation. In this case, new-onset atrial fibrillation in the setting of markedly reduced myocardial reserve likely triggered cardiogenic shock despite biochemical euthyroidism.

#### CONCLUSION

This case highlights that patients with advanced Graves' cardiomyopathy may remain at risk of acute cardiovascular deterioration following RAI therapy. Careful cardiovascular risk assessment, optimization of heart failure therapy, and close monitoring after definitive treatment should be considered in this high-risk population.

## EP\_A166

### ACUTE ISCHEMIC STROKE MASKING UNDERLYING HYPERTHYROIDISM: A DIAGNOSTIC PITFALL OF NON-THYROIDAL ILLNESS SYNDROME

Ashwin Kaur<sup>1</sup> and Ooi Chuan Ng<sup>1,2</sup>

<sup>1</sup>Department of Internal Medicine, Faculty of Medicine and Health Sciences, Universiti Putra Malaysia

<sup>2</sup>Department of Internal Medicine, Hospital Sultan Abdul Aziz Shah, Universiti Putra Malaysia

#### INTRODUCTION

Non-thyroidal illness syndrome commonly occurs during acute systemic illnesses and is characterized by suppressed or inappropriately normal thyroid-stimulating hormone with low or low-normal thyroid hormone levels. This biochemical pattern may obscure or delay the diagnosis of underlying hyperthyroidism, especially in mild or borderline cases. Acute stroke is a recognized trigger of non-thyroidal illness syndrome, yet its masking effect on hyperthyroidism is under-recognized in clinical practice.

#### CASE

A 58-year-old Malay male with cardiovascular risk factors presented with an acute ischemic stroke involving the left occipital lobe and right internal capsule. He developed new-onset atrial fibrillation (CHA<sub>2</sub>DS<sub>2</sub>-VASc 3) and mild left ventricular systolic dysfunction. Initial thyroid function tests during the acute stroke phase showed mildly suppressed thyroid-stimulating hormone (TSH) (0.30 mIU/L) with high-normal free T4 (21.2 pmol/L), interpreted in the context of acute illness. The patient was clinically stable without overt thyrotoxic features.

One month post-stroke, repeat testing revealed further TSH suppression (0.09 mIU/L) and rising free T4 (27.6 pmol/L). Detailed history uncovered prior Graves' disease in 2019 with treatment default. Examination revealed a small diffuse goiter without ophthalmopathy. The biochemical evolution following recovery from acute illness confirmed recurrent hyperthyroidism previously masked by non-thyroidal illness syndrome.

#### CONCLUSION

Acute stroke can induce cytokine-mediated suppression of the hypothalamic-pituitary-thyroid axis and altered peripheral deiodination, leading to misleading thyroid function tests. In this case, non-thyroidal illness syndrome blunted the biochemical severity of hyperthyroidism, delaying recognition despite high-risk features such as atrial fibrillation and prior Graves' disease. Reliance on a single thyroid function test during acute illness may therefore result in underdiagnosis.

## EP\_A167

### WHEN THYROID MEETS DENGUE AND HEPATITIS: A CASE OF SEVERE THYROTOXICOSIS WITH MULTIORGAN DYSFUNCTION

Shamila Sutharsan<sup>1</sup> and Yusniza Yusoff<sup>1</sup>

<sup>1</sup>Hospital Sungai Buloh

#### INTRODUCTION

Severe thyrotoxicosis is an endocrine emergency that may present with multiorgan dysfunction, particularly when precipitated by systemic infection. Management becomes challenging when hepatic injury limits the use of standard antithyroid therapy. We report a case of severe thyrotoxicosis with acute hepatitis in the setting of dengue IgM positivity.

## CASE

A 44-year-old male with chronic alcohol use presented with epistaxis. On examination, he was deeply jaundiced and had tremors on outstretched hands. Initial investigations showed severe hepatitis with AST 2029 U/L, ALT 698 U/L, total bilirubin 236  $\mu\text{mol/L}$ , alkaline phosphatase 138 U/L, and thrombocytopenia ( $34 \times 10^9/\text{L}$ ). Viral hepatitis HBV, HCV, HIV, and autoimmune hepatitis screen were negative. Dengue IgM was positive.

Thyroid function tests demonstrated overt thyrotoxicosis with free thyroxine 4 (FT4) 58.6 pmol/L and suppressed thyroid-stimulating hormone.

He was managed as severe thyrotoxicosis with impending thyroid crisis in view of systemic illness and multiorgan involvement. Due to significant hepatic dysfunction, he was treated with propranolol, dexamethasone, and lithium carbonate 300 mg BD. Over 5 days, there was marked clinical improvement with resolution of tachycardia and tremors. FT4 decreased to 44.8 pmol/L. Liver function tests improved significantly (AST 157 U/L, ALT 195 U/L, bilirubin 163  $\mu\text{mol/L}$ ), and thrombocytopenia resolved (platelets  $323 \times 10^9/\text{L}$ ). He remained hemodynamically stable with normal Glasgow Coma Scale throughout admission.

## CONCLUSION

This case highlights severe thyrotoxicosis with acute hepatitis and dengue infection, where management was complicated by contraindication to conventional antithyroid therapy. Lithium and corticosteroids provided effective biochemical and clinical improvement. Early recognition and individualized therapy are crucial in complex multisystem thyrotoxic presentations.

## EP\_A168

### PRESENCE OF MACRO-TSH: A RARE MIMICKER OF SUBCLINICAL HYPOTHYROIDISM

Zi Yang Lian<sup>1</sup>, Nicholas Ken Yoong Hee<sup>2</sup>, Shireene Vethakkan<sup>1</sup>, Jeyakantha Ratnasingam<sup>1</sup>, Farhi Ain Jamaluddin<sup>3</sup>

<sup>1</sup>Endocrine Unit, Department of Medicine, Faculty of Medicine, Universiti Malaya

<sup>2</sup>Endocrine Unit, Department of Medicine, Universiti Malaya Medical Centre

<sup>3</sup>Division of Laboratory Medicine, Department of Pathology, Faculty of Medicine, University Malaya

## INTRODUCTION

Macro-thyroid-stimulating hormone (macro-TSH) is a rare complex formed by monomeric TSH with anti-TSH autoantibodies. Macromolecules of TSH are not renally excreted due to its large size, leading to elevated TSH measurements without clinical consequences. This rare condition frequently mimics subclinical hypothyroidism, often leading to misdiagnosis and inappropriate levothyroxine therapy.

## CASE

A 17-year-old female with major depressive disorder was biochemically diagnosed with subclinical hypothyroidism (TSH 39.06 mIU/L, free thyroxine 4 12.9 pmol/L, anti-thyroid peroxidase negative) and commenced on levothyroxine. Over 5 years, her TSH levels heavily fluctuated (0.48–82.59 mIU/L) and remained persistently elevated with high-normal free T4 levels despite treatment adherence. An endocrinology consult was obtained, and clinical evaluation revealed a clinically asymptomatic and euthyroid patient, with no family history of thyroid disease or supplement use, and there was no goiter. Assay interference was excluded by analyzing her thyroid function tests on a different platform, which yielded similar biochemical results. Subsequently, a polyethylene glycol (PEG) precipitation test was performed. Her pre-PEG TSH of 29.24 mIU/L decreased significantly to 2.78 mIU/L post-PEG. This yielded a remarkably low TSH recovery rate of 9.5%, strongly indicating the presence of macro-TSH. Levothyroxine was then stopped, and she remained clinically euthyroid.

## CONCLUSION

While gel filtration chromatography remains the gold standard for diagnosing this condition, PEG precipitation is a more accessible, cost-effective, and reliable screening method in clinical practice. A TSH recovery rate below 20% is considered highly suggestive of macro-TSH. Clinicians

should maintain a high index of suspicion for macro-TSH in asymptomatic patients presenting with isolated TSH elevations that do not respond to thyroxine therapy. Prompt recognition prevents misdiagnosis and avoids the potential risks of unnecessary thyroid hormone replacement.

## EP\_A169

### OVERT HYPOTHYROIDISM PRESENTING WITH ISOLATED LOWER MOTOR NEURON FACIAL NERVE PALSY

Murshidah Ainun Mukhtar<sup>1</sup>, Rabeah Md Zuki<sup>2</sup>, Wei Chin Mow<sup>3</sup>, Nurul Farehah Mohd Nazri<sup>3</sup>

<sup>1</sup>Medical Unit, Hospital Sik

<sup>2</sup>Medical Department, Hospital Sultanah Bahiyah

<sup>3</sup>Medical Department, Hospital Sultan Abdul Halim

#### INTRODUCTION

Cranial nerve palsies have been reported in patients with uncontrolled hypothyroidism. We describe a case of overt hypothyroidism due to treatment disruption following radioiodine therapy, presented with a unilateral lower motor neuron seventh cranial nerve palsy.

#### CASE

A 32-year-old female presented with hypertension, dyslipidemia, class III obesity, and Graves' disease post radioiodine therapy. She had stable thyroid function test with levothyroxine replacement post radioiodine. She presented with a 3-day history of right-sided facial droop associated with lethargy, weight gain, and constipation. She reported inadequate levothyroxine supply due to 2-month lapses in follow-up.

On examination, there was a right-sided lower motor neuron 7<sup>th</sup> cranial nerve palsy with delayed ankle reflexes. No additional neurological deficits, goiter, cutaneous rashes, or vesicular lesions were noted. There was no preceding viral illness or otologic symptoms.

Thyroid function tests showed overt hypothyroidism with thyroid-stimulating hormone 38 mIU/L, free thyroxine <5.4 pmol/L with a deranged lipid profile (total cholesterol: 8.8 mmol/L, low-density lipoprotein: 5.72 mmol/L, triglyceride: 1.77 mmol/L). Renal and liver function tests were within normal limits, with no leukocytosis. Neuroimaging of the brain was unremarkable.

She was commenced on a short course of high-dose prednisolone, with no improvement in symptoms. Levothyroxine replacement therapy initiated led to progressive restoration of thyroid function, accompanied by symptom recovery.

#### CONCLUSION

Isolated lower motor 7<sup>th</sup> nerve palsy has been reported as a manifestation of hypothyroidism. This case underscores the importance of early recognition to enable timely and appropriate management, as patients with hypothyroidism-induced isolated seventh nerve palsy demonstrate marked recovery with adequate levothyroxine replacement.

## EP\_A170

### FIRE IN THE GLAND: A RARE CASE OF GRAVES' DISEASE IN CYSTIC FIBROSIS

Mohd Deenie Mohd Rodzhan<sup>1,2,3</sup>, Yik Hin Chin<sup>1,3</sup>, Norasyikin A. Wahab<sup>1,2</sup>, Norlaila Mustafa<sup>1,2</sup>, Ilham Ismail<sup>2</sup>, Mahrunissa Mahadi<sup>2</sup>

<sup>1</sup>Department of Medicine, Faculty of Medicine, Universiti Kebangsaan Malaysia

<sup>2</sup>Department of Medicine, Hospital Canselor Tuanku Muhriz

<sup>3</sup>Ministry of Health Malaysia

#### INTRODUCTION

Cystic fibrosis (CF) is an autosomal recessive disorder caused by mutations in the CFTR gene. Complications such as cystic fibrosis-related diabetes (CFRD) are well recognized. The association between CF and autoimmune thyroid disease, however, is rare and poorly understood. We report a case of CFRD complicated by Graves' disease.

#### CASE

A 22-year-old male was diagnosed with CF at age 5, confirmed by a positive sweat chloride test. Following the diagnosis, lifelong pancreatic enzyme replacement therapy (Creon) was initiated to treat exocrine pancreatic insufficiency. In 2021, he developed type 3c diabetes, attributed to endocrine pancreatic insufficiency, and required regular basal insulin therapy.

In early 2024, he developed hypokalemic periodic paralysis with proximal myopathy, despite potassium correction, and was admitted to the hospital. On admission, examination revealed a fine tremor and diffuse bilateral neck swelling. Biochemical evaluation showed thyrotoxicosis with Free T4 of 37 pmol/L and thyroid-stimulating hormone (TSH) <0.01 mIU/L. He started a tapering dose of carbimazole and propranolol. An urgent neck ultrasound showed a heterogeneous thyroid parenchyma with increased vascularity and no nodules. Elevated anti-thyroid peroxidase (anti-thyroid peroxidase, >600 IU/mL) and TSH receptor antibodies (thyrotropin receptor antibody, 2.57 IU/L) confirmed a diagnosis of Graves' disease.

During follow-ups, he had issues with compliance with the antithyroid therapy. However, the latest thyroid function test in February 2026 showed Free T4 of 20.5 pmol/L with suppressed TSH of <0.01 mIU/L. He remains clinically euthyroid throughout the follow-up.

#### CONCLUSION

This case highlights a rare but clinically relevant coexistence. Clinicians managing symptomatic CF patients should vigilantly screen for thyroid dysfunction to ensure early diagnosis and timely intervention. Early recognition and treatment may improve patient outcomes. Further research is needed to clarify the immunological link between CF and autoimmunity.

## EP\_A171

### THYROID-LIVER INTERPLAY: EARLY RECOGNITION OF CARBIMAZOLE-INDUCED CHOLESTASIS AMID THYROTOXICOSIS

Zhi Ling Ng<sup>1</sup>, Siti Nabihah Hatta<sup>2</sup>, Yohggesh Arumugam<sup>1</sup>, Ooi Chuan Ng<sup>1</sup>

<sup>1</sup>Faculty of Medicine and Health Sciences, Universiti Putra Malaysia

<sup>2</sup>Department of Internal Medicine, Hospital Sultan Abdul Aziz Shah, Universiti Putra Malaysia

#### INTRODUCTION

Carbimazole is a first-line therapy for thyrotoxicosis and is generally well tolerated. Drug-induced liver injury is rare (<1%) and typically presents as cholestatic hepatotoxicity, in contrast to propylthiouracil, which more commonly causes hepatocellular injury. Clinical presentation may mimic obstructive jaundice, and delayed recognition can lead to unnecessary investigations and interruption of definitive thyroid management.

#### CASE

A 70-year-old female with toxic multinodular goiter developed painless jaundice 4 weeks after starting carbimazole 20 mg daily for thyrotoxicosis precipitated by urinary tract infection. She had no prior liver disease or alcohol exposure. Examination revealed isolated icterus without features of chronic liver disease.

Initial thyroid function tests showed suppressed thyroid-stimulating hormone (<0.01 mIU/L) with markedly elevated free T4 (>100 pmol/L), improving after 4 weeks (free T4 29.1 pmol/L). She subsequently developed progressive jaundice without abdominal pain, fever, pruritus, or encephalopathy. Liver biochemistry demonstrated a cholestatic pattern

(R factor 1.1) with conjugated hyperbilirubinemia (peak bilirubin 227 µmol/L), mild transaminitis, and elevated alkaline phosphatase.

Imaging, including hepatobiliary ultrasonography, contrast computed tomography, and endoscopic ultrasound, excluded biliary obstruction. Viral, autoimmune, and structural causes were negative. Carbimazole-induced cholestatic jaundice was diagnosed based on temporal association and exclusion of alternatives. Carbimazole was discontinued, ursodeoxycholic acid was initiated, and radioactive iodine therapy was performed, followed by gradual recovery.

#### CONCLUSION

Carbimazole-induced hepatotoxicity (0.1–0.2%) is likely idiosyncratic and not dose dependent. Differentiating drug-induced liver injury from thyrotoxicosis-related liver dysfunction is critical, as restoration of euthyroidism alone may normalize liver enzymes. Diagnosis relies on the exclusion of obstruction and recognition of drug chronology. Early drug withdrawal and multidisciplinary management are essential to prevent progression while ensuring timely definitive therapy.

## EP\_A172

### THE EVOLVING BIOCHEMICAL PROFILE: FROM LOW FT4/LOW TSH TO ISOLATED HYPOTHYROXINEMIA IN PREGNANCY

Wei Ton Wong<sup>1</sup>, Muhammad Amir Arif Mohammad Nizam<sup>1</sup>, Amila Syahida Rusli<sup>1</sup>

<sup>1</sup>Internal Medicine Unit, Hospital Besut

#### INTRODUCTION

Isolated hypothyroxinemia (IH) in pregnancy, characterized by low free thyroxine 4 (FT4) with normal thyroid-stimulating hormone (TSH), has a reported prevalence of 1.3–8%. We present a diagnostically challenging case that initially mimicked central hypothyroidism before evolving into classic IH.

#### CASE

A 37-year-old G4P3 female at 22 + 3 weeks gestation with β-thalassemia trait presented with palpitations and tachycardia (150–184 bpm). A bedside echocardiogram showed volume depletion. Her heart rate improved to 108–116 bpm following a 1.5 L normal saline bolus. Incidentally, thyroid function tests (TFTs) revealed both low FT4 6.04 pmol/L (7.86–14.41) and low TSH 0.009 mIU/L (0.38–5.33). Anti-thyroid peroxidase antibody was markedly elevated at 360 IU/mL (<35).

At 24 + 4 weeks, TFTs showed persistently low FT4 (5.84 pmol/L) and TSH (0.022 mIU/L). Differential diagnoses included central hypothyroidism or assay interference. Tests were repeated using different platforms. Both the Beckman system (FT4: 5.73 pmol/L, TSH: 0.086 mIU/L) and Roche system (FT4: 8.83 pmol/L [12.0–22.0], TSH: 0.11 mIU/L [0.27–4.20]) confirmed low values, ruling out assay interference. Following endocrinology consultation and given her asymptomatic status, IH was considered most likely, and a plan for close monitoring was initiated.

Serial follow-up demonstrated biochemical evolution. By 31 + 6 weeks, TFTs showed a low TSH (0.753 mIU/L) with an FT4 level (5.86 pmol/L) within the normal reference range, a pattern typical of IH in pregnancy. Repeat TFTs 6 weeks postpartum showed both TSH and FT4 within normal range.

#### CONCLUSION

This case illustrates a rare and unexpected biochemical progression of IH in pregnancy, initially presenting with a pattern indistinguishable from central hypothyroidism. It underscores that in an asymptomatic, fertile patient, IH can manifest with an atypical pattern early in gestation. The findings suggest that vigilant serial monitoring, rather than immediate extensive pituitary workup, may be a prudent initial approach in such scenarios, as the biochemical profile can normalize toward the classic IH pattern as pregnancy advances.

## EP\_A173

### WHEN TSH SUPPRESSION BECOMES HARMFUL: THYROXINE OVER-REPLACEMENT DRIVING CARDIOVASCULAR DECOMPENSATION IN ADVANCED HEART FAILURE

Ahmad Syahmi Yusof Zaki<sup>1,2</sup>, Nur Izat Muhamad<sup>2</sup>, Ezelea Elwina Walter Sandosam<sup>2</sup>, Wan Mohd Izani Wan Mohamed<sup>2</sup>

<sup>1</sup>Faculty of Medicine, University Sultan Zainal Abidin

<sup>2</sup>Department of Internal Medicine, School of Medical Sciences, University Science Malaysia

#### INTRODUCTION

Thyroid stimulating hormone (TSH) suppression following differentiated thyroid carcinoma is widely recommended to reduce recurrence risk. However, this strategy assumes cardiovascular tolerance to supraphysiologic thyroid hormone exposure. In patients with advanced structural heart disease, this assumption may fail, exposing a critical limitation of guideline-directed TSH suppression.

#### CASE

We report a 71-year-old male with end-stage renal failure on hemodialysis and severe ischemic cardiomyopathy (ejection fraction 23%) who presented with acute decompensation characterized by dyspnea, rapid atrial fibrillation, and non-ST-elevation myocardial infarction. He had a history of papillary thyroid carcinoma treated with total thyroidectomy and radioactive iodine over 20 years prior and was maintained on levothyroxine 200 mcg daily for TSH suppression. Despite biochemically euthyroid indices (TSH 1.8 mIU/L, free thyroxine 4.17 pmol/L), he developed recurrent arrhythmia with heart failure decompensation.

This case highlights a dissociation between biochemical euthyroidism and tissue-level thyrotoxicity in a structurally compromised myocardium. Papillary thyroid carcinoma after definitive therapy typically follows an indolent course with low short-term mortality. In contrast, in severe left ventricular dysfunction, excess thyroid hormone increases adrenergic sensitivity and myocardial oxygen demand, precipitating arrhythmia and ischemia. This risk is amplified in end-stage renal disease, where altered hormone handling renders biochemical indices less reliable.

#### CONCLUSION

Biochemical euthyroidism does not equate to physiological safety. In patients with advanced cardiovascular disease, thyroid hormone therapy should be titrated to cardiovascular tolerance rather than oncologic targets alone, and routine TSH suppression may be inappropriate.

## EP\_A174

### SEVERE BIOCHEMICAL THYROTOXICOSIS WITHOUT CLINICAL HYPERTHYROIDISM IN ESRF FOLLOWING PARATHYROIDECTOMY: A DIAGNOSTIC AND THERAPEUTIC PITFALL

Ahmad Syahmi Yusof Zaki<sup>1,2</sup>, Nur Izat Muhamad<sup>2</sup>, Ezelea Elwina Walter Sandosam<sup>2</sup>, Wan Mohd Izani Wan Mohamed<sup>2</sup>

<sup>1</sup>Faculty of Medicine, University Sultan Zainal Abidin

<sup>2</sup>Department of Internal Medicine, School of Medical Sciences, University Science Malaysia

#### INTRODUCTION

Thyrotoxicosis following neck surgery is typically attributed to transient destructive thyroiditis from follicular disruption. In end-stage renal failure (ESRF), however, altered thyroid hormone kinetics, including reduced protein binding, impaired peripheral metabolism, and decreased clearance, can distort biochemical interpretation.

This creates a high-risk scenario where laboratory values overestimate tissue thyrotoxicity, predisposing to inappropriate antithyroid therapy. We present a case demonstrating marked clinical–biochemical dissociation, reframing postoperative thyrotoxicosis in ESRF as a disorder of hormone handling rather than hormone overproduction.

#### CASE

A 45-year-old female with ESRF on maintenance hemodialysis and tertiary hyperparathyroidism underwent total parathyroidectomy. Preoperative thyroid function was consistently euthyroid. Within 48 hours postoperatively, she developed severe biochemical thyrotoxicosis (thyroid-stimulating hormone 0.28 mIU/L, free thyroxine 4 [FT4] 68 pmol/L). Despite this, she remained clinically euthyroid, with stable hemodynamics, absence of adrenergic or neuropsychiatric features, and no evidence of thyroid eye disease.

The temporal relationship strongly suggested destructive thyroiditis secondary to surgical manipulation, with passive release of preformed thyroid hormone. In the context of ESRF, impaired hormone clearance and altered binding likely amplified circulating free hormone levels without proportional end-organ effect, resulting in striking clinical–biochemical dissociation.

A conservative strategy was adopted. Antithyroid drugs were withheld, given the non-synthetic mechanism of hormone excess, and the patient was managed with close monitoring and symptom-guided beta-blockade. Serial thyroid function demonstrated spontaneous improvement without complications.

#### CONCLUSION

Post-parathyroidectomy thyrotoxicosis in ESRF represents exaggerated biochemical derangement without true tissue toxicity. Management must prioritize physiology over laboratory values, as misclassification risks iatrogenic harm. This case demonstrates that in ESRF, elevated FT4 may not reflect true tissue thyrotoxicity, and reliance on biochemical severity alone can lead to inappropriate antithyroid therapy and iatrogenic harm.

## EP\_A175

### THYROTOXICOSIS ASSOCIATED WITH GUILLAIN–BARRÉ SYNDROME: A RARE AUTOIMMUNE OVERLAP

**Nur Asmak Abdullah<sup>1</sup>, Rabeah Md Zuki<sup>2</sup>, Mohamed Azlam Micdhadhu<sup>3</sup>**

<sup>1</sup>*Internal Medicine Unit, Department of Medicine, Hospital Sultan Abdul Halim (HSAH)*

<sup>2</sup>*Endocrinology Unit, Department of Medicine, Hospital Sultan Abdul Halim (HSAH)*

<sup>3</sup>*Neurology Unit, Hospital Seberang Jaya*

#### INTRODUCTION

The coexistence of thyroid storm and Guillain–Barré syndrome (GBS) is rare, with few reported cases. A shared autoimmune mechanism has been suggested, although the exact pathophysiology remains unclear. In severe thyrotoxicosis, new neurological symptoms may be overlooked or attributed to metabolic causes, delaying diagnosis and posing a diagnostic and therapeutic challenge. We report a case of a 43-year-old female with Graves' disease complicated by thyroid storm and Acute Motor Axonal Neuropathy (AMAN), a variant of GBS, highlighting the importance of early recognition and multidisciplinary management.

#### CASE

A 43-year-old female with no prior medical illness presented with fever, generalized weakness, fine tremors, and 10 kg weight loss over 5 months. On arrival, she was lethargic, febrile (40.2°C), and tachycardic (148 bpm), consistent with thyroid storm by Burch–Wartofsky criteria. She denied preceding diarrheal illness or upper respiratory tract symptoms. The thyroid function test showed markedly elevated free thyroxine 4 (>64.35 pmol/L) and suppressed thyroid-stimulating hormone (TSH) (<0.008 mIU/L). Subsequent testing revealed elevated TSH receptor antibodies (>40 IU/L), confirming Graves' disease.

Her course was complicated by anaphylactic shock with transient cardiac arrest, followed by acute kidney injury and respiratory failure requiring intensive care unit admission and mechanical ventilation. Following extubation, symmetrical limb weakness with generalized areflexia and bilateral foot drop was observed. Nerve conduction studies demonstrated a symmetrical axonal motor-predominant polyneuropathy consistent with AMAN.

She received five sessions of plasma exchange and showed marked neurological improvement, while thyroid and renal function normalized at discharge.

## CONCLUSION

This case highlights a rare and potentially life-threatening association of thyroid storm and AMAN. Severe thyrotoxicosis can precipitate atypical autoimmune complications, underscoring the need for vigilance. Clinicians should consider neurological evaluation in patients with severe thyrotoxicosis presenting with new-onset motor weakness.

## EP\_A176

### SYNERGISTIC USE OF PLASMAPHERESIS AND LITHIUM IN REFRACTORY THYROID STORM

Humaira Nuraqilah Mohd Yusof<sup>1</sup>, Nur Aini Eddy Warman<sup>1</sup>, Nur Haziqah Baharum<sup>1</sup>, Aimi Fadilah Mohamad<sup>1</sup>, Mohd Hazriq Awang<sup>1</sup>, Fatimah Zaherah Mohamed Shah<sup>1</sup>, Rohana Abdul Ghani<sup>1</sup>

<sup>1</sup>Department of Internal Medicine, Faculty of Medicine, Universiti Teknologi MARA

## INTRODUCTION

Thyroid storm is a life-threatening endocrine emergency with a mortality rate of 8–25% despite optimal therapy. Some patients exhibit a refractory phenotype characterized by rapid clinical deterioration and failure of conventional treatment, necessitating early escalation. Therapeutic plasmapheresis and lithium represent adjunctive therapies targeting different aspects of thyroid hormone physiology, yet their combined use remains underexplored.

## CASE

A 55-year-old male with Graves' disease, non-adherent to treatment since 2020, presented with fever, palpitations, and dyspnea for 2 days. He recently started on carbimazole 30 mg daily and propranolol 1 week prior. On examination, blood pressure was 158/74 mmHg, heart rate 180 bpm, Glasgow Coma Scale 15/15 with bibasal crepitations. Electrocardiogram showed atrial fibrillation at 168 bpm. His Burch-Wartofsky score was 95, consistent with thyroid storm. Standard therapy with propylthiouracil 250 mg QID, Lugol's iodine, intravenous hydrocortisone 100 mg TDS, and carvedilol was commenced. However, after 3 days of treatment, he developed acute confusion and persistent fast atrial fibrillation requiring cardioversion. Liver function remained normal. Plasmapheresis was initiated on day 4 for six sessions. Propylthiouracil was switched to methimazole due to a declining white cell count from  $(5.5-3.2 \times 10^9/L)$ . Lithium 300 mg BD was added on day 13 due to inadequate free thyroxine 4 (FT4) reduction. After 1 week of combined therapy, FT4 decreased from 70 to 35 pmol/L.

## CONCLUSION

Early recognition of refractory disease and timely escalation are critical as refractory thyroid storm carries high mortality, especially with cardiovascular and neurological involvement. When conventional therapy fails, plasmapheresis facilitates rapid clearance of circulating thyroid hormones and inflammatory mediators, while lithium inhibits thyroid hormone release, providing an alternative mechanism when thionamides alone are insufficient. Their combined use offers a synergistic approach and targets both circulating and intrathyroidal hormone pools, suggesting that early dual-modality intervention is essential to overcome therapeutic resistance and improve overall outcomes in refractory disease.

## EP\_A177

### HYPERTHYROIDISM AND GESTATIONAL TROPHOBLASTIC DISEASE: A CASE REPORT

K.J. Lingeswary<sup>1</sup>, Jean Mun Cheah<sup>1</sup>, Fei Bing Yong<sup>1</sup>, Jen Hoong Oon<sup>1</sup>, Aniqah Shamimi<sup>1</sup>, Sharifah Noor Adrilla binti Long Mohd Noor Affendi<sup>1</sup>, Gayathri Devi A/P Krishnan<sup>1</sup>, Shazatul Reza Binti Mohd Redzuan<sup>1</sup>, Subashini Rajoo<sup>1</sup>

<sup>1</sup>Endocrine Unit, Hospital Kuala Lumpur

## INTRODUCTION

Gestational trophoblastic disease (GTD) is an uncommon but important cause of secondary hyperthyroidism, termed trophoblastic hyperthyroidism, resulting from the structural similarity between human chorionic gonadotropin (hCG) and thyroid-stimulating hormone (TSH). Excessively elevated hCG levels can stimulate the TSH receptor, leading to increased thyroid hormone production and clinically significant thyrotoxicosis. Early recognition is essential as uncontrolled hyperthyroidism may lead to serious perioperative complications.

## CASE

We report a 50-year-old female who presented with persistent vaginal bleeding following a prior uterine evacuation. Clinical examination and ultrasonography revealed a uterine mass corresponding to approximately 14 weeks' gestation. Serum  $\beta$ -hCG was markedly elevated at  $>1,000,000$  IU/L. Histopathological evaluation confirmed choriocarcinoma. Thyroid function tests demonstrated severe biochemical hyperthyroidism, with suppressed TSH and elevated free thyroxine levels. Notably, the patient did not exhibit classic symptoms or signs of hyperthyroidism such as palpitations, tremor, goiter, or thyroid eye signs. She was started on beta-blockers and carbimazole for initial

control. Given the underlying pathology, early definitive surgical management was planned with multidisciplinary input, and she subsequently underwent total abdominal hysterectomy with bilateral salpingo-oophorectomy successfully.

Hyperthyroidism in GTD is well described, but patients may remain clinically asymptomatic despite significant biochemical derangement, as seen in this case. Markedly elevated  $\beta$ -hCG can mimic primary thyroid disease and may lead to misinterpretation if the underlying cause is not recognized. While antithyroid drugs such as carbimazole are commonly initiated, they may have limited effect in this setting, as the hyperthyroidism is driven by hCG rather than intrinsic thyroid overactivity. Beta-blockers play an important role in controlling symptoms and reducing peripheral conversion of T4–T3. Early definitive treatment of the underlying trophoblastic disease remains the key to resolution.

#### CONCLUSION

Trophoblastic hyperthyroidism is a reversible condition secondary to the underlying disease process. Treatment of the trophoblastic tumor results in resolution of the thyrotoxic state. Early recognition and appropriate preoperative optimization are essential to ensure safe patient outcomes.

## EP\_A178

### A DIAGNOSTIC MASQUERADE: RESISTANCE TO THYROID HORMONE MIMICKING TSH-SECRETING PITUITARY ADENOMA

Deviga Lachumanan<sup>1</sup>

<sup>1</sup>Department of Medicine, Hospital Port Dickson

#### INTRODUCTION

Discordant thyroid function tests (TFTs), characterized by elevated free thyroxine 4 (FT4) with non-suppressed thyroid-stimulating hormone (TSH), pose a significant diagnostic challenge. Differentiating between Resistance to Thyroid Hormone (RTH) and TSH-secreting pituitary adenoma (TSH-oma) is essential, as management strategies differ substantially.

#### CASE

A female with a history of hyperthyroidism diagnosed in 2011 was treated with antithyroid drugs for 1 year before defaulting on follow-up. She was later found to have discordant TFTs at a private centre, where a brain computed

tomography scan was reportedly normal. She was referred to our centre for optimization of thyroid function prior to planned thyroidectomy for a solitary large right thyroid nodule measuring 4.2 × 2.8 × 4.7 cm. Fine-needle aspiration cytology demonstrated a benign follicular lesion (Bethesda II).

Despite restarting antithyroid medication, she remained clinically euthyroid with no overt thyrotoxic symptoms apart from intermittent palpitations without documented tachycardia. Antithyroid therapy was discontinued. Serial TFTs across multiple assay platforms consistently demonstrated elevated FT4 with inappropriately normal TSH levels. Thyroid autoantibodies, including TSH receptor and anti-thyroid peroxidase antibodies, were negative.

Pituitary magnetic resonance imaging showed no evidence of adenoma, and serum  $\alpha$ -subunit level was normal (0.3 ng/mL), making TSH-oma unlikely. Dynamic testing was not performed as thyrotropin-releasing hormone stimulation was unavailable at our centre, while T3 suppression testing was deemed inappropriate due to symptomatic palpitations. Family screening was not possible as the patient was not in contact with her relatives. In the absence of pituitary pathology and given her largely euthyroid clinical status, RTH was considered the most likely diagnosis.

#### CONCLUSION

This case highlights the importance of considering RTH in patients with persistent discordant TFTs, particularly when clinical findings do not correlate with biochemical abnormalities. Early recognition and appropriate pituitary evaluation are essential to prevent misdiagnosis and avoid unnecessary antithyroid therapy or thyroidectomy.

## EP\_A179

### DYNAMIC AUTOIMMUNE THYROIDITIS IN MYELODYSPLASTIC SYNDROME: FROM PAINLESS THYROTOXICOSIS TO OVERT HYPOTHYROIDISM

Dekritiana Dian Pratiwi<sup>1</sup> and Hemi Sinorita<sup>1</sup>

<sup>1</sup>Department of Internal Medicine, Faculty of Medicine, Public Health and Nursing Gadjah Mada University/ Dr. Sardjito Hospital, Indonesia

#### INTRODUCTION

Autoimmune thyroid disease can follow a triphasic course: thyrotoxicosis, a transient euthyroid period, and eventual hypothyroidism, and may coexist with myelodysplastic syndrome (MDS) in the context of immune dysregulation.

### CASE

We describe a 35-year-old male with MDS (multilineage dysplasia) receiving cyclosporine who initially presented with painless thyrotoxicosis, with suppressed thyroid-stimulating hormone (TSH) and elevated free thyroxine (FT4). During this hyperthyroid phase, thyrotropin receptor antibody (TRAb) was positive. Over time, his thyroid status fluctuated, progressing to overt hypothyroidism, and he had poor adherence to thyroid medications. On admission, he had prominent hypothyroid features (fatigue, cold intolerance, slowed movement, periorbital puffiness) with severe biochemical hypothyroidism (TSH 49.5  $\mu$ IU/mL; FT4 0.419 ng/dL). Anti-thyroid peroxidase (anti-TPO) antibodies 12.62 IU/mL (negative <5.61 IU/mL; positive  $\geq$ 5.61 IU/mL) showed an autoimmune response to the thyroid. Thyroid ultrasound showed heterogeneous, hyperechoic with some hypoechoic parts, and no significant increase in thyroid vascularity was observed, supporting autoimmune thyroiditis representation. His hematologic profile remained consistent with MDS, with chronic macrocytic anemia and thrombocytopenia.

### CONCLUSION

This case highlights a dynamic autoimmune thyroiditis phenotype progressing from a hyperthyroid phase with TRAb positivity to higher anti-TPO overt hypothyroidism in a patient with MDS. In individuals with MDS and changing thyroid function tests, clinicians should keep autoimmune thyroiditis variants in mind and use thyroid antibodies together with ultrasound to secure the diagnosis when the clinical pattern is typical.

## EP\_A180

### A THORN IN THE TREATMENT OF GRAVES' DISEASE: THE HIDDEN ALLERGEN

Suprhamanyam Evali<sup>1</sup>, Siew Huang Lee<sup>2</sup>, Karen Christelle<sup>3</sup>, Anilah Abdul Rahim<sup>4</sup>

<sup>1</sup>Endocrinology Unit, Hospital Putrajaya

<sup>2</sup>Pharmacy Department, Hospital Kuala Kangsar

<sup>3</sup>Family Medicine, Klinik Kesihatan Felda Bersia

<sup>4</sup>Endocrinology Department, Hospital Raja Permaisuri Bainun

### INTRODUCTION

Graves' disease is typically managed with antithyroid drugs (ATDs) and beta-blockers like propranolol. While allergic reactions to ATDs are common, beta-blockers are rarely identified as allergens.

### CASE

A 42-year-old female with Graves' disease was started on carbimazole 5 mg daily and propranolol 40 mg daily. She developed mild itchiness, which was tolerable. One month later, liver enzyme derangement led to the discontinuation of carbimazole. Propylthiouracil (PTU) 300 mg daily was initiated while continuing propranolol, but caused generalized urticaria, necessitating its cessation. Prednisolone was started, but her thyroid function worsened. Alternative therapies were proposed but declined by the patient. Upon resolution of urticaria, PTU was reintroduced at 50 mg daily without adverse effects, and propranolol was discontinued. Her cutaneous symptoms did not recur, implicating propranolol as the allergen.

### CONCLUSION

In hyperthyroidism, increased hepatic clearance reduces plasma propranolol levels, minimizing the risk of adverse effects. However, as thyroid function normalizes, propranolol clearance slows, leading to drug accumulation and increased susceptibility to side effects. Clinicians should consider all medications as potential allergens and understand how thyroid states affect drug metabolism to optimize treatment.

## EP\_A181

### TITRATING THE MIND: REFRACTORY SCHIZOPHRENIFORM PSYCHOSIS AS AN ISOLATED "CEREBRAL STORM" IN GRAVES' DISEASE

Fang Chan Lim<sup>1</sup>

<sup>1</sup>Department of Internal Medicine, Hospital Tawau

### INTRODUCTION

Neuropsychiatric manifestations of thyrotoxicosis range from mild anxiety to severe psychosis. While the Burch-Wartofsky Point Scale (BWPS) reliably identifies systemic thyroid storms, an isolated "cerebral storm"—where profound thyrotoxic encephalopathy presents without peripheral autonomic signs—remains a diagnostic challenge. This case highlights the neuromodulatory pathogenesis of thyrotoxic psychosis and the critical role of biochemical control for psychiatric resolution.

## CASE

A 31-year-old male with Graves' disease and poor medication adherence presented with a 2-week history of aggressive behavior and auditory hallucinations. Initial investigations revealed overt thyrotoxicosis (thyroid-stimulating hormone <0.01 mIU/L; free thyroxine 4 (FT4) 59.53 pmol/L) and an unremarkable computed tomography brain. Despite his severe neuropsychiatric decompensation, a BWPS of 20 precluded a clinical diagnosis of systemic thyroid storm.

His symptoms remained refractory to aggressive psychotropic polypharmacy, including haloperidol, olanzapine, lithium, and diazepam. Management was therefore focused on the underlying thyrotoxicosis with an optimized antithyroid regimen of carbimazole and propranolol. Clinical resolution of psychotic symptoms was achieved only after FT4 declined significantly to 20.46 pmol/L, allowing the successful tapering of all psychiatric medications. He was discharged in a stable, clinically euthyroid state with integrated medical and psychiatric follow-up.

## CONCLUSION

The failure of standard antipsychotics suggests that thyrotoxic psychosis is driven by distinct neuromodulatory mechanisms rather than primary dopaminergic dysfunction. The chronic thyrotoxic state secondary to prolonged treatment non-adherence likely upregulates and sensitizes dopamine receptors while simultaneously suppressing inhibitory GABAergic pathways. This neurochemical imbalance lowers the neurological threshold, precipitating an isolated cerebral storm. This case illustrates the limitations of the BWPS in purely neuropsychiatric presentations and reinforces that restoring euthyroidism is the definitive treatment for thyrotoxic psychosis.

## EP\_A182

### SUBACUTE THYROIDITIS VS SUPPURATIVE THYROIDITIS: A DIAGNOSTIC CHALLENGE

**Jia En Chew<sup>1</sup>, Ju Vern Ew<sup>1</sup>, Albert Li Ren Chong<sup>1</sup>, Eunice Yi Chwen Lau<sup>1</sup>**

<sup>1</sup>Endocrinology Unit, Department of Medicine, Sibu Hospital

## INTRODUCTION

Subacute thyroiditis (SAT) and acute suppurative thyroiditis (AST) are two distinct inflammatory conditions but share many overlapping clinical and biochemical features, which may pose a diagnostic challenge. We report a case of SAT mimicking AST.

## CASE

A 39-year-old female presented with a 3-week history of painful neck swelling and symptoms of thyrotoxicosis, including palpitations, heat intolerance, and diaphoresis. She had no family history of thyroid disease. On examination, she was febrile and had a smooth and tender goiter. Her blood tests showed leukocytosis with elevated erythrocyte sedimentation rate and C-reactive protein. Her thyroid function test (TFT) showed thyroid-stimulating hormone of 0.023 mIU/L and free thyroxine 4 of 32.15 pmol/L.

An urgent ultrasound revealed a large, ill-defined heterogeneously hypoechoic lesion predominantly at the left lobe of the thyroid gland with mild intralesional vascularity. These were reported as features of thyroiditis with infective or early suppurative changes. Fine needle aspiration (FNA) of the lesion was attempted by the radiologist but was unsuccessful.

She was treated with intravenous antibiotics and non-steroidal anti-inflammatory drugs (NSAIDs), but symptoms persisted. Repeated ultrasound and computed tomography scans about 1 week later confirmed an enlarged thyroid gland with no obvious lesion or collection within the gland. The diagnosis was revised to SAT, and prednisolone 15 mg OD was started. This resulted in rapid improvement in her symptoms and inflammatory markers.

Four weeks later, she remained asymptomatic, and prednisolone was gradually tapered off. Serial TFT monitoring showed a classic triphasic pattern with an initial hyperthyroid phase, followed by hypothyroidism before returning to euthyroidism.

## CONCLUSION

SAT can present with a focal lesion on the ultrasound during the early stage of the disease, making it difficult to distinguish from a thyroid abscess due to overlapping features. Good clinical judgement guided by FNA and appropriate follow-up imaging may be helpful in differentiating between the two conditions.

## EP\_A183

### RESCUE PLASMA EXCHANGE IN THYROID STORM: SUCCESSFUL BRIDGING TO THIONAMIDE THERAPY

Pei Sun Tan<sup>1</sup>, Hafizah Mohd Amadzun<sup>1</sup>, Sharifah Noor Adrilla Long Mohd Noor Affendi<sup>1</sup>, Gayathri Devi Krishnan<sup>1</sup>, Shazatul Reza binti Mohd Redzuan<sup>1</sup>, Subashini Rajoo<sup>1</sup>

<sup>1</sup>Endocrine Unit, Department of Internal Medicine, Hospital Kuala Lumpur

## INTRODUCTION

Therapeutic plasma exchange (TPE) has emerged as a rescue therapy in thyroid storm. Multiple cycles are often required to achieve adequate reduction in circulating thyroid hormone levels. We report a case of thyroid storm with multiorgan failure successfully managed with only two cycles of TPE, followed by carbimazole.

## CASE

A 43-year-old female with no significant past medical history presented with a 5-month history of altered bowel habits. She has a small goiter, which was not investigated before. She underwent elective esophagogastroduodenoscopy and colonoscopy at a private centre, both of which were unremarkable. Post-procedure, she developed unstable tachyarrhythmia and cardiac arrest. Return of spontaneous circulation was achieved after three cycles of cardiopulmonary resuscitation, and she was transferred to the intensive care unit. Biochemical evaluation revealed severe thyrotoxicosis (thyroid-stimulating hormone [TSH] <0.008 mIU/L, free thyroxine 4 [FT4] >100 pmol/L). Burch-Wartofsky Point Scale was 90.

Her clinical course was complicated by multiorgan failure, including ischemic hepatitis with coagulopathy and oliguric acute kidney injury requiring continuous veno-venous hemodialysis. Lugol's iodine and corticosteroids were initiated as thionamides were contraindicated due to severe hepatic dysfunction. She developed refractory tachyarrhythmia despite electrical cardioversion. Following a multidisciplinary discussion, TPE was initiated due to the limited choice of antithyroid medication.

After two TPE sessions, thyroid function improved markedly (TSH 0.01 mIU/L, FT4 26.2 pmol/L), accompanied by improvement in hepatic and renal function, allowing safe commencement of carbimazole. Thyroid function remained stable with FT4 of 19.3 pmol/L 1 week post TPE. Echocardiography demonstrated mildly reduced left ventricular ejection fraction (45–50%) with bi-atrial dilatation.

## CONCLUSION

This case highlights the role of limited-cycle TPE as an effective rescue therapy and bridging strategy to definitive treatment in severe thyroid storm with multiorgan failure. Timely TPE initiation may improve biochemical control and clinical outcomes in critically ill patients.

## Paediatric Oral Presentation

### OP\_P001

#### **BRIDGING THE GAP: ADOPTION AND BARRIERS TO CONTINUOUS GLUCOSE MONITORING IN PAEDIATRIC TYPE 1 DIABETES**

Sok Bee Lim<sup>1</sup>, Siti Sarah Ahmad Dardiri<sup>1</sup>, Nalini M. Selveindran<sup>1</sup>, Arini Nuran Md Idris<sup>1</sup>, Janet Yeow Hua Hong<sup>1</sup>  
<sup>1</sup>Paediatric Endocrine Unit, Hospital Putrajaya

#### **INTRODUCTION**

ISPAD guidelines recommend continuous glucose monitoring (CGM) as the standard of care for paediatric type 1 diabetes (T1DM). However, a “real-world” adoption gap persists, particularly in resource-limited settings. The Introductions of the study were to evaluate CGM adoption prevalence, identify documented barriers, and compare glycemc outcomes between active and non-active users.

#### **METHODOLOGY**

This retrospective review analyzed electronic medical records (EMR) of 125 paediatric T1DM patients at Hospital Putrajaya (2025). Data included CGM status, insulin delivery method, and documented barriers. Independent T-tests compared mean hemoglobin A1c (HbA1c) between groups, and multivariable logistic regression identified independent predictors of adoption.

#### **RESULTS**

Cohort mean age was  $11.8 \pm 3.8$  years. Active CGM users were 32.8% ( $n = 41$ ), of whom 29.3% ( $n = 12$ ) utilized predominantly automated insulin delivery (AID) systems. The remaining 67.2% ( $n = 84$ ) were classified as non-active users, comprising both never-users and ex-users (discontinued use). Active users achieved significantly lower mean HbA1c than non-active users (8.73% vs 9.86%;  $p < 0.001$ ), with no significant difference in rates of DKA ( $p = 0.564$ ) or severe hypoglycemia ( $p = 0.250$ ). Among never-users, 42.9% lacked documented technology counselling ( $p = 0.001$ ). Multivariable analysis identified funding source as the sole independent predictor of CGM adoption (adjusted OR = 7.76,  $p < 0.001$ ). While the primary documented barrier was financial (31.0%), a lack of documented barriers was noted in 61.9% of non-active users.

#### **CONCLUSION**

A substantial technology gap exists, primarily driven by financial access rather than clinical demographics. The difference of 1.13% in HbA1c between groups underscores the need to address financial setbacks to improve technology access in Malaysia and prevent diabetes complications.

## OP\_P002

### CENTRAL PRECOCIOUS PUBERTY: EVALUATION OF PREDICTED AND FINAL ADULT HEIGHT IN GIRLS WHO RECEIVED GNRH ANALOGS

Adam Mohd Noor<sup>1</sup>, Muhammad Yazid Jalaludin<sup>2</sup>, Lixian Oh<sup>2</sup>

<sup>1</sup>Hospital Raja Permaisuri Bainun Ipoh

<sup>2</sup>Universiti Malaya Medical Centre

#### INTRODUCTION

Central precocious puberty (CPP) is defined as the early occurrence of puberty before the age of 8 years in girls and 9 years in boys. CPP has many implications for the patient's physical, emotional, and psychological aspects. The most sought-after benefit of the treatment is the preservation of the growth potential of final adult height. This study aims to evaluate the predicted and final adult height in girls with CPP who received treatment in the University Malaya Medical Centre (UMMC), Malaysia.

#### METHODOLOGY

In this retrospective longitudinal study, 32 CPP patients who received treatment with GnRH analogs in UMMC between 2010 and 2025 were identified. The demographic and clinical data of the patients were retrieved from the medical record system and analyzed.

#### RESULTS

The study revealed that predicted adult height (PAH) by using bone age closely approximated the actual final adult height (FAH) with no significant difference observed ( $p = 0.793$ ), and a strong positive correlation ( $r = 0.75, p < 0.001$ ). The predicted height based on the genetic potential of mid-parental target height (MPTH) showed a significant underestimation of FAH (mean difference = -1.89 cm,  $p < 0.01$ ), although it remained a robust predictor ( $r = 0.75, p < 0.01$ ). Across age groups, the correlation between PAH and FAH was strongest in girls aged 6–8 years old. Notably, girls treated before age 6 exhibited a significant height gain compared to initial prediction values, underscoring the importance of early intervention.

#### CONCLUSION

From this study, we concluded that the FAH outcome in girls with CPP who received treatment with GnRH analogs is preserved, similar to the PAH calculated by bone age. However, the FAH is significantly lower than the MPTH (genetic potential). The baseline height SDS appears to be a strong predictor of FAH. The bone age value is the strongest predictor of FAH. The preservation of adult height potential is more prominent when subjects developed CPP before 6 years and were treated immediately.

## OP\_P003

### ETIOLOGICAL YIELD AND TREATMENT PATTERNS IN PAEDIATRIC ARGININE VASOPRESSIN DEFICIENCY: A SINGLE-CENTRE COHORT STUDY

Siti Sarah Ahmad Dardiri<sup>1</sup>, Nalini M Selveindran<sup>1</sup>, Sok Bee Lim<sup>1</sup>, Arini Nuran Md Idris<sup>1</sup>, Janet YH Hong<sup>1</sup>

<sup>1</sup>Paediatric Endocrine Unit, Hospital Putrajaya

#### INTRODUCTION

Arginine vasopressin deficiency (AVP-D), previously termed central diabetes insipidus, is a rare paediatric endocrine disorder that may present as an early manifestation of diverse hypothalamic-pituitary conditions. Identifying the underlying etiology is crucial for guiding management and surveillance; however, in some children, the cause remains unresolved, leading to primarily symptomatic treatment. In Malaysia, published literature on paediatric AVP-D has been limited to isolated case reports, with no cohort-level data available. This study aims to describe the clinical features, etiological spectrum, and treatment patterns of paediatric AVP-D in a single-centre Malaysian cohort, emphasizing diagnostic yield, unresolved causes, and the central role of neuroimaging.

#### METHODOLOGY

A retrospective review was conducted of children diagnosed with AVP-D. Data collected included age at symptom onset, age at presentation, clinical features, etiological classification, neuroimaging findings, comorbidities, treatment modalities, and follow-up outcomes. Descriptive statistics were used for analysis.

#### RESULTS

Twelve children were included, with a median age of 9.8 years; two-thirds were male. Children were referred at a median age of 3.4 years, with presentation ranging from the neonatal period to 10.4 years. Diagnostic delay was minimal overall, although 25% experienced delays exceeding 1 year. The water deprivation test was performed in 33.3% of patients. Magnetic resonance imaging (MRI) was completed in all children and served as the principal determinant of etiology. Structural abnormalities were identified in 50% of the cohort, including semilobar holoprosencephaly (33.3%), Arnold-Chiari I malformation (8.3%), and pituitary stalk interruption syndrome (8.3%). The posterior pituitary bright spot was absent in most patients, and 50% required repeat MRI to clarify evolving neurohypophyseal features. Tumor-related AVP-D accounted for 8.3%, while one-third had no definitive etiology despite imaging. Initial therapy included desmopressin (58.3%), hydrochlorothiazide (25%), and diluted sublingual desmopressin (8.3%), with most requiring dose escalation. Growth impairment occurred in 66.7% of patients, and delayed puberty in 16.7%.

#### CONCLUSION

MRI played a central role in defining etiology, with half of the cohort demonstrating congenital structural abnormalities. Persistent unresolved cases highlight the diagnostic challenges of AVP-D and underscore the importance of early MRI and longitudinal endocrine follow-up.

## OP\_P004

### HEALTH-RELATED QUALITY OF LIFE IN CHILDREN AND ADOLESCENTS WITH X-LINKED HYPOPHOSPHATEMIA (XLH) AT UNIVERSITI MALAYA MEDICAL CENTRE

Nur Syafiqah Hamizi<sup>1,2</sup>, Muhammad Yazid Jalaludin<sup>1</sup>, Mohd Shafiq Azanan<sup>1</sup>, Nur Sabrina Rusli<sup>1</sup>

<sup>1</sup>Universiti Malaya Medical Center

<sup>2</sup>Ministry of Health Malaysia

#### INTRODUCTION

X-linked hypophosphatemia (XLH) is a rare genetic disorder caused by PHEX mutations, characterized by chronic hypophosphatemia and renal phosphate wasting, resulting in skeletal, dental, and extra-skeletal complications. To date, no data from Malaysia are currently available on clinical characteristics or health-related quality of life (HRQoL) in paediatric patients.

#### METHODOLOGY

This cross-sectional study evaluated HRQoL among children and adolescents with XLH, using validated PROMIS (Patient-Reported Outcomes Measurement Information System) instruments, sociodemographic and clinical factors associated with HRQoL. This includes children and adolescents with confirmed XLH followed up at Universiti Malaya Medical Centre (UMMC) between November 2024 and March 2025.

#### RESULTS

Seventeen patients were analyzed (76.5% female and 23.5% male). The mean age at symptom onset was  $2.82 \pm 2.42$  years, with a mean age at diagnosis of  $5.21 \pm 3.29$  years. All patients continued to have musculoskeletal complications, including short stature (76.5%), bowing of legs (76.5%), bone/joint pain (47.1%), muscle pain (47.1%), and dental complications (52.9%). Serum alkaline phosphatase improved significantly ( $p = 0.011$ ); persistent hypophosphatemia and ongoing musculoskeletal manifestations indicated suboptimal disease control. Elevated parathyroid hormone levels and an increase in urine calcium-to-creatinine ratio ( $p = 0.020$ ) lead to secondary hyperparathyroidism and nephrocalcinosis. Adherence to conventional therapy was poor. Non-adherence was associated with worse pain outcomes (higher pain interference [ $p = 0.037$ ] and greater pain intensity [ $p = 0.025$ ]). PROMIS scores revealed severely impaired mobility (mean T-score  $31.31 \pm 12.17$ ), increased fatigue (mean T-score  $54.22 \pm 7.60$ ), and high pain interference (mean T-score  $63.11 \pm 9.50$ ). Larger household size was also strongly associated with higher pain intensity ( $p = 0.004$ ).

#### CONCLUSION

Malaysian children and adolescents with XLH continue to have significantly poor HRQoL, particularly in mobility, fatigue, and pain. These findings highlight the need for access to targeted therapies, such as burosumab, to improve long-term outcomes and QOL in XLH patients.

## OP\_P005

### PREVALENCE AND NEONATAL PREDICTORS OF METABOLIC BONE DISEASE OF PREMATURITY IN HOSPITAL TUNKU AZIZAH KUALA LUMPUR

Muhamad Hanif Halim<sup>1</sup>, Choi Siang Choong<sup>2</sup>, Arini Nuran Md Idris<sup>2</sup>, Yee Lin Lee<sup>1</sup>

<sup>1</sup>Department of Paediatrics, Faculty of Medicine and Health Sciences, Hospital Sultan Abdul Aziz Shah, Universiti Putra Malaysia

<sup>2</sup>Department of Paediatrics, Hospital Tunku Azizah

#### INTRODUCTION

Metabolic bone disease of prematurity (MBDP) is characterized by biochemical and radiological findings related to bone demineralization in premature babies. Despite early recognition, MBDP is still a prevalent problem and is associated with significant morbidities in premature babies. This study aims to determine the prevalence and neonatal predictors of MBDP.

#### METHODOLOGY

This retrospective cross-sectional study involved premature babies with gestational age  $\leq 32$  weeks and birth weight  $\leq 1.5$  kg, admitted to Hospital Tunku Azizah, Kuala Lumpur, between January 1, 2020, and January 31, 2024. Babies whose serum phosphate was  $\leq 1.5$  mmol/L and serum alkaline phosphatase  $>500$  IU/L at 3–6 weeks of age fulfilled the diagnosis of MBDP. The maternal and neonatal characteristics of the study population were retrieved from the medical records. Neonatal predictors for MBDP were analyzed by simple and multiple logistic regression.

#### RESULTS

A total of 292 subjects were enrolled. The prevalence of MBDP was 13.4%. On simple logistic regression, male gender, low gestational age, poor APGAR score, delayed enteral feed initiation, prolonged TPN, delayed vitamin D supplementation, use of unfortified expressed breast milk, patent ductus arteriosus, and bronchopulmonary dysplasia, cholestasis, prolonged hospital stay, and prolonged ventilation were risk factors for MBDP ( $p < 0.05$ ). On multiple logistic regression, only cholestasis ( $p 0.014$ ), prolonged TPN use ( $p < 0.001$ ), and prolonged hospitalization ( $p < 0.001$ ) were independent neonatal predictors for MBDP.

#### CONCLUSION

The risk of MBDP can be reduced by shortening TPN duration and hospitalization duration and preventing cholestasis. This may be achieved by early enteral feeding initiation and use of fortified EBM, thus preventing the development of MBDP.

## Paediatric Best Poster Presentation

### BP\_P001

#### DIABETES-RELATED DISTRESS IN ADOLESCENTS WITH TYPE 1 DIABETES

Nur Sabrina Rusli<sup>1,2</sup>, Mohd Shafiq Azanan<sup>1</sup>, Azriyanti Anuar Zaini<sup>1</sup>

<sup>1</sup>Universiti Malaya

<sup>2</sup>Universiti Sains Islam Malaysia

#### INTRODUCTION

Adolescents with type 1 diabetes (T1D) are vulnerable to diabetes-related distress (DRD), an emotional burden that may adversely affect glycemic control. Data on DRD among adolescents in Southeast Asia, particularly Malaysia, remain limited. This study aims to determine the prevalence of DRD and examine its association with glycemic control and socio-demographic background among Malaysian adolescents with T1D.

#### METHODOLOGY

This cross-sectional study recruited adolescents aged 10–19 years with T1D attending a tertiary Paediatric Endocrine Clinic in Malaysia between May and August 2025. DRD was assessed using two validated instruments: the Problem Areas in Diabetes–Teen version (PAID-T) and the Type 1 Diabetes Distress Scale (T1-DDS). Sociodemographic and clinical data, including glycated hemoglobin (HbA1c), were collected. Associations between distress, glycemic control, and other variables were analyzed using non-parametric tests, correlation analyses, and multiple linear regression.

#### RESULTS

Seventy adolescents participated (median age: 14.65 years). Moderate to severe DRD was reported by 32.9% using PAID-T and 38.6% using T1-DDS. Higher distress scores on both instruments were significantly correlated with poorer current and prior HbA1c levels. Adolescents with HbA1c  $\leq 7.0\%$  were more likely to report minimal distress compared to those with higher HbA1c ( $p = 0.042$ , T1-DDS). Subdomain analyses revealed strong associations between emotional distress domains, particularly powerlessness and family/friends distress, and higher HbA1c. In multivariable regression, DRD, body mass index, and family/friends distress together explained 35% of the variance in HbA1c. Attendance at diabetes management camps was not associated with differences in distress levels.

#### CONCLUSION

Approximately one-third of Malaysian adolescents with T1D experience clinically significant DRD, which is strongly associated with suboptimal glycemic control. Emotional and family-related distress appear to play a particularly important role. Routine screening and targeted psychosocial interventions should be integrated into adolescent diabetes care to improve both emotional well-being and metabolic outcomes.

## BP\_P002

### INCIDENCE, CLINICAL PRESENTATION, AND OUTCOME OF HYPERTHYROIDISM IN CHILDREN AND ADOLESCENTS: A SINGLE-CENTRE STUDY

Sivaneshwary Selvam<sup>1,2</sup> and Nurshadia Binti Samingan<sup>2</sup>

<sup>1</sup>Hospital Tunku Azizah (HTA)

<sup>2</sup>Universiti Malaya Medical Centre

#### INTRODUCTION

Hyperthyroidism in children and adolescents, although uncommon, has significant effects on growth, neurodevelopment, and quality of life. Local data in Malaysia are limited, and regional variations may influence disease presentation and outcomes. This study aimed to determine the incidence, clinical characteristics, and treatment outcomes of paediatric hyperthyroidism at a tertiary centre.

#### METHODOLOGY

A retrospective cohort study was conducted at the Paediatric Endocrine Clinic, Universiti Malaya Medical Centre, from 2014 to 2024. Patients aged below 18 years with confirmed hyperthyroidism were included. Demographic, clinical, biochemical, and treatment data were analyzed. Descriptive statistics were used, and associations were tested using chi-square and Fisher's exact tests, with  $p < 0.05$  considered significant.

#### RESULTS

Forty-three patients were included, representing 9.7% of paediatric thyroid disorders. The cohort was predominantly female (74.4%) and majority Malay, with a median age of 11.7 years. Most patients presented with typical features, including palpitations (72.5%), goiter (62.5%), weight loss (45.0%), and heat intolerance (40.0%). However, atypical presentations such as learning difficulties and psychological disturbances were also observed and, in some cases, constituted the chief complaints. Notably, 82.5% of patients presented with severe thyrotoxicosis. Grave's disease was the predominant etiology. All patients received antithyroid drugs, mainly carbimazole, with 80.0% achieving disease control and a median time to euthyroid state of 2 months. The duration of antithyroid drug therapy prior to cessation was shorter than international recommendations, indicating a significant reduction in time to treatment completion. Relapse occurred in 25.0% and was significantly associated with poor disease control ( $p = 0.014$ ), while no significant associations were found with demographic or biochemical factors. Definitive therapy was required in 35.0%, with older age, growth stunting, and prior relapse identified as significant predictors ( $p < 0.05$ ).

#### CONCLUSION

Paediatric hyperthyroidism in this Malaysian cohort is predominantly due to Graves' disease and frequently presents with both classical and atypical manifestations, which may delay diagnosis. Despite a high proportion of severe thyrotoxicosis at presentation, antithyroid drug therapy was effective, with a shorter duration to treatment cessation compared to international standards. Poor disease control emerged as the strongest predictor of relapse, while older age, growth stunting, and prior relapse predicted progression to definitive therapy. Early recognition and individualized management are essential to optimize outcomes. Larger multicentre studies are needed to inform national clinical practice guidelines.

## BP\_P003

### GLYCEMIC CONTROL IN ADOLESCENTS WITH TYPE 1 DIABETES MELLITUS (T1DM): THE ROLE OF HEALTH LITERACY AND NUMERACY

Sharon Chung Tuang Yuk<sup>1,2</sup>, Joyce Hong Soo Synn<sup>1</sup>, Lim Poi Giok<sup>3</sup>, Yang Wai Wai<sup>1,2</sup>

<sup>1</sup>Department of Paediatrics, Hospital Tunku Ampuan Besar Tuanku Aishah Rohani, Universiti Kebangsaan Malaysia

<sup>2</sup>Department of Paediatrics, Faculty of Medicine, Universiti Kebangsaan Malaysia

<sup>3</sup>Department of Paediatrics, Hospital Tunku Azizah

#### INTRODUCTION

Type I diabetes mellitus (T1DM) is the most common form of diabetes diagnosed in childhood. The Diabetes in Children and Adolescents Registry (Di-CARE) in Malaysia reported that many of these patients are between 10 and 19 years old. However, little is known about the association of their health literacy and numeracy with their glycemic control.

#### METHODOLOGY

A cross-sectional study among T1DM patients aged 12 to 19 years old who attended Paediatric Endocrine Clinic at Hospital Tunku Ampuan Besar Tuanku Aishah Rohani and Hospital Tunku Azizah was conducted from March 2025 to March 2026. Participants answered 14 questions on the Diabetes Numeracy Test (DNT-14) and completed a 29-item health literacy questionnaire (myMOHLAA-Q). Data analysis was performed using SPSS version 30. The relationship of health literacy and numeracy with glucose control (HbA1c) was analyzed using Spearman's rank order correlation.

#### RESULTS

A total of 43 adolescents with T1DM were recruited with a median age of 15.2 years (IQR: 13.2–17.2 years). There were 22 female (51.2%) and 21 male (48.8%) participants. The majority of the participants ( $n = 27$ , 62%) had moderate glycemic control with a median HbA1c of 8.3% (IQR: 7.5–9.6%). A Spearman's correlation revealed a negative relationship between mean HbA1c and knowledge on blood glucose monitoring,  $r_s(43) = -0.34$ ,  $p < 0.05$ . Additionally, positive relationships were found of knowledge on blood glucose monitoring and knowledge on insulin with total DNT-14 score,  $r_s(43) = 0.54$ ,  $p < 0.001$  and  $r_s(43) = 0.78$ ,  $p < 0.001$ , respectively. The small sample size may have limited the ability to detect other significant relationships.

#### CONCLUSION

The majority of T1DM adolescents have moderate glycemic control. Active intervention in improving knowledge on blood glucose monitoring and insulin helps to improve glycemic control, reiterating the importance of diabetes education in the long-term management and glycemic control in adolescents with type 1 diabetes.

## BP\_P004

### **METABOLIC DYSFUNCTION-ASSOCIATED STEATOTIC LIVER DISEASE AMONG CHILDREN AND ADOLESCENTS IN A TERTIARY CENTRE IN SARAWAK**

**Geraldine Yee Pei Lim<sup>1</sup>, Victoria David<sup>1</sup>, Kiew Siong Lau<sup>2</sup>, Chiong Hung Kiew<sup>3</sup>, Hooi Peng Cheng<sup>3</sup>**

<sup>1</sup>*Nursing Unit, Sarawak General Hospital*

<sup>2</sup>*Department of Radiology, Sarawak General Hospital*

<sup>3</sup>*Department of Paediatrics, Sarawak General Hospital*

#### **INTRODUCTION**

The global rise in paediatric obesity has led to an increasing burden of metabolic comorbidities, including metabolic dysfunction-associated steatotic liver disease (MASLD). Obstructive sleep apnea (OSA), characterized by chronic intermittent hypoxia, has been implicated in the pathogenesis of liver injury. This study aimed to evaluate the prevalence of MASLD and its association with OSA among children and adolescents in a tertiary centre.

#### **METHODOLOGY**

A retrospective cross-sectional study was conducted involving children aged 6–15 years who were admitted for polysomnography at Sarawak General Hospital between 2024 and 2025. Clinical, biochemical, and lifestyle data were obtained from medical records and parental questionnaires. Hepatic steatosis was assessed using hepatobiliary ultrasound in a subset of patients.

#### **RESULTS**

A total of 132 children (mean age  $10.8 \pm 2.7$  years; 87.5% male) were included. The median BMI SDS was 2.50 (IQR: 2.29–2.93). The mean apnea-hypopnea index (AHI) was  $12.0 \pm 7.9$ , with 60% classified as severe OSA.

Among the 16 children who underwent liver ultrasound, MASLD was identified in 81.2%, including five cases of grade 1 and eight cases of grade 2 steatosis. Liver transaminitis was present in six patients. Metabolic comorbidities were common, with 43.8% requiring metformin for insulin resistance or impaired glucose tolerance, and four patients requiring antihypertensive therapy.

Unhealthy lifestyle behaviors were prevalent: 64.2% consumed sugary drinks  $\geq 3$  times weekly, 42.9% consumed fast food  $\geq 3$  times weekly, and only 24.3% reported daily fruit or vegetable intake. Physical inactivity ( $\leq 2$  times/week) was observed in 71.4%, while 64.3% had screen time exceeding 2 hours daily.

#### **CONCLUSION**

Children and adolescents with moderate-to-severe OSA exhibit a high burden of metabolic dysfunction, including MASLD. The findings support a potential contributory role of OSA-related hypoxia in paediatric fatty liver disease and highlight the need for integrated screening and early intervention in this high-risk population.

## BP\_P005

### EFFECTIVENESS AND SAFETY OF LOW-DOSE DIAZOXIDE IN TRANSIENT HYPERINSULINEMIC HYPOGLYCEMIA

Nuramalina Mazeli<sup>1</sup>, Yong Hong Lee<sup>1</sup>, Pian Pian Tee<sup>1</sup>, Song Hai Lim<sup>1</sup>

<sup>1</sup>Paediatric Department, Sabah Women and Children's Hospital

#### INTRODUCTION

Diazoxide is an effective treatment for hyperinsulinemic hypoglycemia (HH), though its dosage for the transient form of HH is not well established. Recently, a Singapore cohort reported effective low-dose diazoxide in treating HH secondary to small for gestational age (SGA). We aim to study the effectiveness and safety of this low-dose regimen in transient HH.

#### METHODOLOGY

This was a retrospective cohort study. All infants diagnosed with transient HH and treated with diazoxide between 1 January 2024 and 31 December 2025 were included. The primary objective was to determine the effective diazoxide dose in maintaining euglycemia (blood glucose  $\geq 3.5$  mmol/L). The secondary objective was to monitor complications following diazoxide usage.

#### RESULTS

A total of 21 infants were recruited with a median gestational age of 37 weeks (IQR: 35–37.5) and a median birth weight of 1,980 grams (IQR: 1,670–2,340). The risk factors were SGA (71.4%,  $n = 15$ ), infants of diabetic mothers (19%,  $n = 4$ ), and others (14%,  $n = 3$ ). A median glucose infusion rate of 12.6 (IQR: 10.4–14.5) mg/kg/minute was required to treat the hypoglycemia. Eleven infants (52.3%) required adjunct glucagon therapy before transitioning to diazoxide therapy, with a median dose of 8 mcg/kg/hour (IQR: 7–12).

Diazoxide was initiated at a median of 20 days of life (IQR: 14–30), with a median starting dose of 3.0 mg/kg/day (IQR: 3.0–3.55). Euglycemia was fully achieved in 95.2% ( $n = 20$ ) of infants within a median of 5 days (IQR: 3–9) post diazoxide initiation. At discharge, the median diazoxide dose was 3.3 mg/kg/day (IQR: 3.0–4.8). Adverse events occurred in five cases (23.8%), primarily limited to transient fluid retention ( $n = 4$ ) and gastrointestinal symptoms ( $n = 1$ ). None developed echocardiography-proven pulmonary hypertension in this cohort.

#### CONCLUSION

Low-dose diazoxide (3–5 mg/kg/day) is effective and well-tolerated for managing the transient form of HH in our setting. This benefit appears not to be limited to babies born with SGA, but may extend to other risk factors as well.

## Paediatric Best Case Report Presentation

### BC\_P001

#### MEDICAL MANAGEMENT OF PAEDIATRIC CUSHING SYNDROME PRESENTING WITH SEVERE HYPERCORTISOLISM

Yee Lin Lee<sup>1</sup>, Chun Jie Lee<sup>1</sup>, Tzer Hwu Ting<sup>1</sup>, Ooi Chuan Ng<sup>2</sup>

<sup>1</sup>Department of Paediatrics, Hospital Sultan Abdul Aziz Shah, Universiti Putra Malaysia

<sup>2</sup>Department of Medicine, Hospital Sultan Abdul Aziz Shah, Universiti Putra Malaysia

#### INTRODUCTION

Endogenous Cushing syndrome is a rare manifestation of chronic cortisol excess. It may present with severe hypercortisolism complicated by life-threatening opportunistic infections. Surgical management of a cortisol-secreting tumor is the mainstay of therapy. However, when the source is not found or when surgery is not feasible, medical therapies may be employed for rapid control of hypercortisolism.

#### CASE

A 13-year-old male presented with breathlessness for one day. He also had a cough associated with weight loss, weakness, and hallucinations for 1 month. On presentation, he was tachypneic and had moon facies, acne, fine moustache, limb wasting, and pigmented nail beds. He was also hypertensive and developed an episode of seizure during admission. Investigation results showed severe hypokalemia and lymphopenia. Radiological examination revealed pneumothorax with multiple lung cavitations and brain tuberculomas. Bronchoalveolar lavage (BAL) was positive for *Aspergillus fumigatus*. However, both BAL and CSF PCR and culture for TB were negative. Serum ACTH was 379 pg/mL (0–46), and morning serum cortisol was 2,948 nmol/L with loss of diurnal rhythm. His 24-hour urine cortisol was 14,252 nmol/24 hour (31.7–282). This is consistent with ACTH-dependent Cushing syndrome. He was started on anti-TB and anti-fungal treatment. Serum cortisol levels were persistently high while on high-dose intravenous dexamethasone treatment for TB meningitis. An MRI pituitary and a CT scan thorax, abdomen, and pelvis could not reveal an ACTH-secreting tumor source. Metyrapone was started and titrated upwards to control the hypercortisolism. Serum cortisol reduced to 200–300 nmol/L after 1 month, and 24-hour urinary cortisol was down to 22.4 nmol/24 hour after 4 months, requiring weaning of metyrapone doses.

#### CONCLUSION

Metyrapone is effective in the rapid control of severe hypercortisolism with life-threatening complications, as illustrated in this case. However, it warrants careful monitoring and titration.

## BC\_P002

### PAEDIATRIC NODAT FOLLOWING KIDNEY TRANSPLANT: CLINICAL CHARACTERISTICS OF FOUR CASES AT HOSPITAL TUNKU AZIZAH

Rohani Ahmad<sup>1</sup>, Yap Yok Chin<sup>2</sup>, Arliena Amin<sup>1</sup>, Lim Poi Giok<sup>1</sup>

<sup>1</sup>Paediatric Endocrinology Unit, Department of Paediatrics, Hospital Tunku Azizah

<sup>2</sup>Paediatric Nephrology Unit, Department of Paediatrics, Hospital Tunku Azizah

#### INTRODUCTION

New-onset diabetes after transplantation (NODAT) is a clinically significant complication associated with adverse metabolic and graft outcomes and affects patients' quality of life. Data in paediatric populations are limited. This case series describes the incidence, clinical characteristics, and early outcomes of NODAT in a paediatric kidney transplant cohort.

#### CASES

Thirty patients (aged 5–17 years; 16 males, 14 females; 14 Malay, 15 Chinese, 1 Indian) underwent renal transplantation at Hospital Tunku Azizah between 2019 and 2025.

NODAT was identified using standard diagnostic criteria and occurred in four patients (13.3%). Among patients who developed NODAT, three were Malay and one Chinese; all were aged 10–17 years, with a predominance of females ( $n = 3$ ). All were non-obese (body mass index [BMI]: 11–21.4 kg/m<sup>2</sup>), and only one had a family history of type 2 diabetes mellitus. Underlying causes of ESRF in these patients included focal segmental glomerulosclerosis (FSGS,  $n = 2$ ), CAKUT ( $n = 1$ ), and unknown etiology ( $n = 1$ ). Two patients received kidneys from living donors, and two from cadaveric donors. Two patients demonstrated reduced C-peptide levels, consistent with impaired insulin secretion. All patients received steroid induction and maintenance therapy alongside tacrolimus-based immunosuppression, with one patient also receiving everolimus. Two patients developed post-transplant CMV viremia, which has been associated with NODAT.

The onset of NODAT was early, occurring within 2 weeks post-transplant in three patients and at 1 month in one patient. Insulin therapy achieved glycemic control in all cases. Two patients were able to discontinue insulin within 3–4 months, suggesting recovery of endogenous glycemic regulation, while the remaining two required ongoing insulin therapy.

#### CONCLUSION

NODAT affects a substantial proportion of paediatric kidney transplant recipients and may present despite the absence of conventional risk factors. Early surveillance is essential. The observed potential for insulin independence may indicate a reversible component of  $\beta$ -cell dysfunction, which warrants further investigation in larger cohorts.

## Paediatric E-Poster

### EP\_P001

#### EVALUATION OF ACANTHOSIS NIGRICANS AS A PREDICTIVE CLINICAL MARKER FOR METABOLIC RISK IN CHILDREN WITH OBESITY

Annie Leong<sup>1</sup>, Nurshadia Samingan<sup>1</sup>, Muhammad Yazid Jalaludin<sup>1</sup>, Azriyanti Anuar Zaini<sup>1</sup>

<sup>1</sup>Paediatric Department, University Malaya Medical Centre

#### INTRODUCTION

Childhood obesity is associated with significant metabolic morbidity, particularly insulin resistance (IR) and metabolic syndrome. Acanthosis nigricans (AN) is frequently observed in children with obesity and may represent a practical clinical marker of IR. This study evaluated the association between AN, IR, and metabolic complications in paediatric obesity.

#### METHODOLOGY

A retrospective review was performed of 148 children (88 males, 60 females; median age 12 years) attending the Paediatric Obesity Clinic at Universiti Malaya Medical Centre. Data included anthropometry, AN grading, family history, HOMA-IR, and metabolic screening. Outcomes assessed were dyslipidemia, metabolic-associated fatty liver disease (MAFLD), hypertension, obstructive sleep apnea syndrome (OSAS), and glucose dysregulation. Comparisons were made between children with and without AN at baseline and over follow-up (median 2.4 years).

#### RESULTS

AN was present in 81.8% of patients, and 82.4% had central obesity. Increasing AN grade was significantly associated with higher BMI SDS and American Academy of Paediatrics obesity class ( $p < 0.05$ ). AN was more prevalent among Malay and Indian children and was associated with a family history of obesity ( $p < 0.05$ ). Baseline metabolic abnormalities were common, including dyslipidemia (high triglycerides 31.8%, low HDL 30.4%, high LDL 29.7%), MAFLD (23.6%), OSAS (31.1%), and glucose dysregulation (27.7%), with no significant difference between groups. During follow-up, children with AN and more severe obesity developed significantly more metabolic complications, particularly MAFLD and OSAS, with increased requirement for non-invasive ventilation ( $p < 0.05$ ). Higher HOMA-IR was associated with glucose dysregulation but was not independently associated with AN.

#### CONCLUSION

AN is strongly associated with greater adiposity and predicts the progression of metabolic complications in children with obesity. Routine assessment of AN may help

identify high-risk patients who would benefit from early, intensive intervention to reduce long-term cardiometabolic morbidity.

### EP\_P002

#### PHENOTYPIC SPECTRUM AND GONADAL OUTCOMES IN CHILDREN WITH 45,X/46,XY MOSAICISM: A LONGITUDINAL COHORT STUDY

Vaidevi Poospalingam<sup>1</sup>, Janet Hong<sup>1</sup>, Arini Nuran<sup>1</sup>, Nalini M Selveindran<sup>1</sup>

<sup>1</sup>Paediatric Endocrine Unit, Hospital Putrajaya

#### INTRODUCTION

45,X/46,XY mosaicism is a rare disorder of sex development characterized by marked phenotypic variability, ranging from typical male or female genitalia to significant genital ambiguity. Data describing long-term clinical outcomes in affected patients remain limited. This study aimed to characterize the phenotypic spectrum and longitudinal outcomes of patients with 45,X/46,XY mosaicism, focusing on growth, associated comorbidities, and gonadal pathology.

#### METHODOLOGY

We conducted a retrospective longitudinal study at a tertiary paediatric endocrine referral centre between January 2006 and January 2025. Patients with cytogenetically confirmed 45,X/46,XY mosaicism or related variants were included. Clinical presentation, karyotype, anthropometry, hormonal profiles, imaging findings, and gonadal histology were reviewed. External genital phenotype was quantified using the External Masculinization Score (EMS). Height was expressed as standard deviation scores (SDS) relative to population norms and compared with genetic potential.

#### RESULTS

Fourteen patients (10 males, 4 females) with 45,X/46,XY mosaicism were identified. Ambiguous genitalia was the predominant presenting feature, observed in 11 of 12 patients with available phenotype data. Growth impairment was common; median height SDS was  $-2.62$  (range  $-3.26$  to  $-2.00$ ) in females and  $-0.46$  (range  $0.13$  to  $-1.70$ ) in males, both below expected genetic potential. Associated congenital anomalies were present in 25% of patients, including cardiac and renal abnormalities. Male patients demonstrated variable degrees of undervirilization with a median EMS of 4.5 (3.75–7.25). Müllerian duct remnants were identified in 66% of patients on imaging. Testicular microlithiasis was observed in two males. During follow-up, two patients underwent gender reassignment. Histological analysis of 14 gonads obtained via gonadectomy or biopsy

revealed abnormal gonadal architecture in all cases. All intra-abdominal gonads demonstrated streak gonads or dysgenetic testicular tissue.

#### CONCLUSION

45,X/46,XY mosaicism demonstrates a broad phenotypic spectrum with frequent genital ambiguity, growth impairment, and abnormal gonadal development. The high prevalence of gonadal dysgenesis underscores the importance of careful surveillance and individualized multi-disciplinary management guided by clinical, endocrine, and histopathological findings.

## EP\_P003

### HEIGHT VELOCITY AND BODY MASS INDEX CHANGES DURING GONADOTROPIN-RELEASING HORMONE AGONIST THERAPY IN CHILDREN WITH CENTRAL PRECOCIOUS PUBERTY (CPP)

Alexis Lordudass<sup>1,2</sup>, Nuratikah Mohd Ghazali<sup>1</sup>, Jay Yin Lim<sup>1</sup>, Mazidah Noordin<sup>1,2</sup>, Noor Shafina Mohd Nor<sup>1,2</sup>

<sup>1</sup>Department of Paediatrics, Hospital Al-Sultan Abdullah, Universiti Teknologi Mara (UiTM)

<sup>2</sup>Department of Paediatrics, Faculty of Medicine, Sungai Buloh Campus, Universiti Teknologi Mara (UiTM)

#### INTRODUCTION

Precocious puberty is increasingly recognized in children. Effect of gonadotropin-releasing hormone agonist (GnRHa) on height velocity (HV) and body mass index (BMI) during treatment of Central Precocious Puberty (CPP) is not well-documented.

#### METHODOLOGY

Records of all patients treated with GnRH for CPP who attended the paediatric endocrine clinic over a 5-year period (2021–2025) [N1.1] were reviewed retrospectively for HV and BMI changes for 3 consecutive years. Basal luteinizing hormone levels  $\geq 0.3$  IU/L or stimulated levels  $\geq 5$  IU/L are considered diagnostic of CPP.

#### RESULTS

Twenty patients were reviewed and median age at the start of study was 7.8 years (4.3–10.3). Majority were female ( $n = 18$ , 90%) with median Tanner Stage 3 and of Malay origin ( $n = 18$ , 90% [N2.1]). Median chronological age was 7.8 years (4.3–10.3) with bone age 10.3 years (5.8–13.4).

Causes of CPP were idiopathic ( $n = 16$ , 80%), CNS lesion ( $n = 2$ , 10%) and poorly controlled congenital adrenal hyperplasia ( $n = 2$ , 10%). Nine (82%) of the 11 patients who had MRI brain done had normal findings.

After 1 year of treatment, the median HV SDS was  $-0.83$  (range  $-2.45$  to  $2.42$ ), and BMI SDS was  $0.45$  ( $-1.94$  to  $2.15$ ). After 2 years ( $n = 12$ ), HV SDS declined to  $-1.3$  ( $-3.44$  to  $0.69$ ), with BMI SDS of  $0.13$  ( $-1.16$  to  $1.79$ ). After 3 years ( $n = 9$ ), HV SDS declined further to  $-1.51$  ( $-3.52$  to  $3.13$ ), and BMI SDS was  $0.16$  ( $-0.12$  to  $1.25$ ).

After 1 year of treatment, 20% ( $n = 4$ ) of patients were overweight and 10% ( $n = 2$ ) were obese. By 3 years, 22% ( $n = 2$ ) remained overweight, and none were obese.

#### CONCLUSION

Premature growth plate senescence induced by prior estrogen exposure may lead to HV decline. Although obesity is a risk factor for the onset of CPP, whether GnRHa treatment directly increases BMI remains controversial as our cohort's BMI change reveals otherwise.

## EP\_P004

### A SPECTRUM OF THYROID DYSFUNCTION IN CHILDREN WITH DOWN SYNDROME: A MALAYSIAN TERTIARY CENTRE EXPERIENCE

Priyadarshini Puvanendran<sup>1</sup>, Azriyanti Binti Anuar Zaini<sup>1</sup>, Wan Hanaa Mardhiah Binti Wan Zainuddin<sup>1</sup>

<sup>1</sup>Universiti Malaya Medical Centre

#### INTRODUCTION

Endocrine abnormalities are frequently observed in children with Down syndrome, with thyroid dysfunction being the most common. The distribution and patterns of thyroid disorders vary between populations.

#### METHODOLOGY

Retrospective data were collected from the electronic medical records of children with Down syndrome who attended the paediatric clinic at University Malaya Medical Centre from the year 2000 to 2025. Data were analyzed to determine the frequency and distribution of thyroid disorders in this cohort.

#### RESULTS

The study included 57 patients, the majority of whom were identified through routine screening ( $n = 56$ , 98.2%). Only one child (1.8%) was diagnosed following a symptomatic presentation of diarrhea. Within the cohort, 51 patients were diagnosed with hypothyroidism and six with hyperthyroidism.

Among those with hypothyroidism, the mean TSH was  $22.5$  mIU/L, with a median age at presentation of 61 days (IQR:  $19$ – $211.5$ ). Notably, 25% of the cohort presented within the

first 19 days, while the rest presented after 7 months of age. Of these, 24 cases (47.1%) were transient, with medications successfully discontinued at a mean age of  $4.0 \pm 2.13$  years. Only 26 patients underwent thyroid scan, which was normal except for one case of thyroid agenesis. Imaging was not performed in others due to early discontinuation of therapy or loss to follow-up.

All hyperthyroid patients had autoimmune thyroid disease (4 Graves' disease, 2 Hashimoto's thyroiditis) with positive autoantibodies. The median age at presentation was 5.4 years (IQR: 2.3–10.2).

### CONCLUSION

Screening for thyroid dysfunction successfully identified almost all cases in patients with Down syndrome. Notably, patients with hyperthyroidism in this cohort had co-occurring autoimmune thyroid dysfunction and demonstrated a significantly earlier age of presentation compared to the general paediatric population.

## EP\_P005

### PREVALENCE OF HYPOTHYROIDISM AND GROWTH OUTCOMES AMONG PATIENTS WITH DOWN SYNDROME

Siti Nur Khairiah Bt Mohd Rozali<sup>1,2</sup>, Suhaimi Hussain<sup>1,3</sup>, Surini Yusoff<sup>1</sup>

<sup>1</sup>Department of Paediatrics, School of Medical Sciences, Universiti Sains Malaysia

<sup>2</sup>Hospital Miri

<sup>3</sup>Hospital Pakar Universiti Sains Malaysia, Health Campus, Universiti Sains Malaysia

### INTRODUCTION

Children with Down syndrome (DS) have a higher prevalence of hypothyroidism compared to the general population, and both conditions are linked to impaired growth. This study aimed to determine the prevalence and subtypes of hypothyroidism in DS and to compare growth outcomes with controls from general population at 2 years of age.

### METHODOLOGY

A retrospective review was conducted on 248 children with DS (aged 2–18 years) followed at Hospital Pakar Universiti Sains Malaysia from 2020 to 2025. Growth outcomes were analyzed in a subgroup of 41 DS children with hypothyroidism compared to 46 controls. Growth was compared using standard CDC charts for and z-scores calculated with PediTools (CDC 2–20 age). Mid-parental height, target height attainment, and height velocity were evaluated. Statistical analysis used t-tests and chi-square tests ( $p < 0.05$ ).

### RESULTS

Of the 248 children with DS, 63.7% had hypothyroidism, predominantly subclinical (85.4%). No cases of acquired or secondary hypothyroidism were found. Children with DS had significantly lower mean height z-scores ( $-1.91 \pm 1.45$  vs.  $-0.54 \pm 1.25$ ;  $p < 0.001$ ), borderline lower height velocity ( $5.80 \pm 2.15$  vs.  $6.92 \pm 3.56$  cm/year;  $p = 0.050$ ), and fewer achieved target height (35% vs. 64.1%;  $p = 0.030$ ) compared to controls. Baseline characteristics were similar between groups. Thyroid ultrasound showed normal anatomy in 50%, hypoplasia in 28.6%, and nodules in 21.4%.

Common comorbidities included congenital heart disease (78.4%), pulmonary complications (16.2%), and other anomalies (32.4%).

### CONCLUSION

Subclinical hypothyroidism was the predominant subtype in DS. Affected children demonstrated poorer growth, with reduced height z-scores, slower growth velocity, and lower likelihood of achieving target height.

## EP\_P006

### CLINICAL CHARACTERISTICS AND OUTCOMES OF PAEDIATRIC HYPERTHYROIDISM: A 10-YEAR SINGLE CENTRE RETROSPECTIVE COHORT STUDY FROM NEGERI SEMBILAN

Munzir Jamil<sup>1</sup>, Mastura Ibrahim<sup>1</sup>, Meenal Mavinkurve<sup>2</sup>

<sup>1</sup>Department of Paediatrics, Hospital Tuanku Ja'afar

<sup>2</sup>Department of Paediatrics, International Medical University

### INTRODUCTION

The commonest cause of paediatric hyperthyroidism is Graves' disease. Previous studies in the Malaysian context haven't captured data from Negeri Sembilan. This study aims to describe the demographic and clinical features of children with hyperthyroidism from Hospital Tuanku Jaafar.

### METHODOLOGY

A retrospective cohort study collating socio-demographic and clinical data from electronic medical records was conducted. Statistical analysis was conducted using Microsoft Excel (v2602).

### RESULTS

Fourteen children between 2015 and 2025 were identified. Females comprised 93% ( $n = 13$ ). The mean age at diagnosis was  $9.76 \pm 3.4$  years, with 64% ( $n = 9$ ) aged  $>10$  years. Malay ethnicity comprised 64% ( $n = 9$ ). Family history was positive in 43% ( $n = 6$ ). Three (21%) children were detected

on routine screening. At presentation, 50% ( $n = 7$ ) were prepubertal and 36% ( $n = 5$ ) were underweight, with mean BMI SDS  $-1.4 \pm 1.2$ . All had high fT4  $78.43 \pm 72$  pmol/L and suppressed TSH TRAb positivity was 86% ( $n = 12$ ). Anti-TPO or anti-thyroglobulin antibodies positivity was 79% ( $n = 11$ ). In one child, all three antibodies were negative. Thyroiditis was the commonest ultrasound finding. Carbimazole starting dose was 0.6 mg/kg/day and average treatment duration was  $3.5 \pm 2.4$  years, which achieved biochemical euthyroidism in 49 days. Relapse rate on carbimazole was 57% ( $n = 8$ ). No adverse effects occurred, and none had definitive therapy. Currently, 71% ( $n = 10$ ) are euthyroid on a mean carbimazole dose of 0.2 mg/kg/day; one is off carbimazole. Current height is  $-1.1 \pm 1.31$  SD and BMI SDS  $-0.42 \pm 1.7$  SD respectively.

#### CONCLUSION

Graves' disease is the commonest form of paediatric hyperthyroidism in Negeri Sembilan, affecting prepubertal Malay females who commonly present with thyrotoxicosis. Carbimazole effectively achieves biochemical euthyroidism with minimal side effects. However, linear growth is affected. Future studies should evaluate the factors associated with these findings.

## EP\_P007

### CLINICAL AUDIT OF CLONIDINE AS A FIRST-LINE PROVOCATIVE AGENT TO EXCLUDE GROWTH HORMONE DEFICIENCY IN CHILDREN WITH SHORT STATURE

Mazidah Noordin<sup>1,2</sup>, Sook Weih Lew<sup>1,2</sup>, Alexis Anand Dass<sup>1,2</sup>, Jay Yin Lim<sup>2</sup>, Noor Shafina Mohd Nor<sup>1,2</sup>

<sup>1</sup>Department of Paediatrics, Faculty of Medicine, Sungai Buloh Campus, Universiti Teknologi Mara (UiTM)

<sup>2</sup>Department of Paediatrics, Hospital Al-Sultan Abdullah, UiTM Puncak Alam, Universiti Teknologi Mara (UiTM)

#### INTRODUCTION

Clonidine is frequently utilized as a stimulus of growth hormone secretion to diagnose growth hormone deficiency in children. This clinical audit evaluates the efficacy and safety profile of clonidine as a sensitive, first-line screening agent to exclude GHD in children.

#### METHODOLOGY

A clinical audit was conducted on seven patients (4 females, 3 males) aged 7.1 to 12.3 years (median age 11.1) evaluated with clonidine stimulation test. The cohort included one prepubertal and six post-pubertal (highest tanner 2) children. Bone age was delayed at BA/CA ratio at 0.63–0.9 (median 0.8). Baseline IGF-1 levels ranged from 56 to 264

ng/mL. None of the children received sex steroid priming. A peak GH threshold of  $>10$  ng/mL was utilized to exclude GHD. Safety profiles, specifically hemodynamic stability and level of consciousness, were actively monitored.

#### RESULTS

Clonidine effectively stimulated GH secretion and excluded GHD in six out of seven patients, yielding peak GH levels between 10.3 and 20.6 ng/mL. One patient with peak GH of 7.6 ng/mL with clonidine, and subsequent test with insulin tolerance test (ITT), confirmed GHD with a peak GH of 7.4 ng/mL. All participants ( $n = 7$ ) experienced drowsiness. Hemodynamic adverse events were notable. Three patients experienced mild hypotension, and three patients developed clinically significant hypotension requiring normal saline fluid bolus.

#### CONCLUSION

Clonidine is a highly effective, sensitive first-line screening agent to exclude GHD, as it reliably stimulates GH peaks above diagnostic thresholds. However, close supervision is required due to drowsiness and the potential for severe hypotension requiring fluid resuscitation. Clinical judgment remains essential as secondary testing with another GH secretagogue is warranted when clinical suspicion persists.

## EP\_P008

### CLINICAL OUTCOMES OF GONADOTROPIN-RELEASING HORMONE AGONIST THERAPY IN CHILDREN WITH CENTRAL PRECOCIOUS PUBERTY

Siti Zakiyyah Bakhtiar<sup>1</sup>, Jia Nyuk Chong<sup>1</sup>, Hooi Peng Cheng<sup>2</sup>

<sup>1</sup>Department of Pharmacy, Sarawak General Hospital

<sup>2</sup>Department of Paediatrics, Sarawak General Hospital

#### INTRODUCTION

Central precocious puberty (CPP) is the premature activation of the hypothalamic-pituitary-gonadal axis, often compromising adult height and psychosocial well-being. Timely treatment with gonadotropin-releasing hormone agonists (GnRHa) such as triptorelin is critical to halt pubertal progression and preserve growth potential. This study evaluated the clinical outcomes of triptorelin therapy in CPP at Sarawak General Hospital (SGH).

#### METHODOLOGY

A retrospective cross-sectional study was conducted among patients with CPP treated with triptorelin at the Paediatric Endocrine Clinic, SGH, including those currently receiving

therapy and those who had discontinued treatment. Demographic and clinical data were extracted from medical records and analyzed using SPSS version 25. Descriptive statistics summarized patient characteristics, while t-tests and non-parametric equivalents assessed treatment outcomes ( $p < 0.05$  significant).

## RESULTS

Eleven patients were included (mean age  $6.88 \pm 2.21$  years; 90.9% female). Two patients (18.2%) were obese at initial diagnosis, and the mean baseline body mass index was  $17.64 \pm 2.25$  kg/m<sup>2</sup>. Most cases were idiopathic (54.5%), while pituitary microadenoma was identified in 36.4%. At diagnosis, the bone age was advanced by a mean of  $3.51 \pm 1.39$  years. Six patients discontinued therapy: four after completion and two at parental request. Among completers, mean treatment duration was  $3.21 \pm 2.42$  years, ending at a mean age of  $10.13 \pm 0.95$  years. Final height did not differ significantly from mid-parental height ( $p = 0.225$ ). Triptorelin significantly improved final height standard deviation score (SDS) ( $p = 0.005$ ) and reduced the bone age/chronological age ratio ( $p = 0.049$ ), though predicted adult height gains were not statistically significant ( $p = 0.321$ ). No adverse effects were reported.

## CONCLUSION

GnRHa therapy slowed pubertal progression and preserved growth potential in children with CPP, with favorable safety outcomes. Larger prospective studies are warranted to validate long-term benefits and identify predictors of optimal response.

## EP\_P009

### PAEDIATRIC GLUCOCORTICOID-INDUCED HYPERGLYCEMIA AND DIABETIC KETOACIDOSIS: AN UNDER-RECOGNIZED COMPLICATION OF CANCER THERAPY

Sasirekha Krisnan Morthy<sup>1</sup>, Annie Leong<sup>1</sup>, Nurshadia Samingan<sup>1</sup>, Azriyanti Anuar Zaini<sup>1</sup>

*Paediatric Endocrine Unit, Department of Paediatric, University Malaya Medical Centre*

## INTRODUCTION

Paediatric glucocorticoid-induced hyperglycemia (GIH) and diabetes are frequently under-recognized complications of cancer therapy. Early identification is essential, as delayed diagnosis may lead to severe metabolic consequences, including diabetic ketoacidosis (DKA). This study aims to characterize the clinical features, risk factors, and outcomes of GIH in a tertiary centre.

## METHODOLOGY

A descriptive cross-sectional study was conducted at the Paediatric Endocrinology Unit, University Malaya Medical Centre, reviewing cases from January 2023 to December 2025. Data were extracted from electronic records, including demographic, clinical, and treatment-related variables.

## RESULTS

Twelve cases of GIH or diabetes were identified, including two presenting with DKA. Most patients had leukemia (92%), with a male predominance (75%). The median age was 13.6 years, and the median body mass index was 22.1 kg/m<sup>2</sup>. Over half (54%) were overweight or obese, and 45% exhibited acanthosis nigricans. A family history of diabetes was present in 75% of cases.

Hyperglycemia developed early in 66% of cases, typically within 2–5 days of initiating high-dose glucocorticoids. Median random blood glucose was 21.9 mmol/L, while median HbA1c was 6.4%. Half were symptomatic, most commonly with polyuria. Insulin therapy was required in 75% of cases, with a median duration of 26 days. Metformin was used in 50% of cases, often in combination with insulin. Most cases resolved following cessation of glucocorticoid therapy, except one who continues to receive metformin for a pre-diabetes state.

## CONCLUSION

Adolescents, those with obesity, insulin resistance, and a positive family history of diabetes, represent high-risk groups for GIH. Importantly, GIH may present with life-threatening DKA. Routine glucose monitoring and risk stratification during glucocorticoid therapy are recommended. The development of local screening and management guidelines is crucial for improving early detection and optimizing patient outcomes.

## EP\_P010

### INFANT HYPOGLYCEMIA REVEALING FACTITIOUS DISORDER IMPOSED ON ANOTHER

Mastura Ibrahim<sup>1</sup>, Munzir Jamil<sup>1</sup>, Meenal Mavinkurve<sup>2</sup>

<sup>1</sup>Department of Paediatrics, Hospital Tuanku Ja'afar Seremban

<sup>2</sup>Department of Paediatrics, International Medical University, Seremban

#### INTRODUCTION

Hyperinsulinemic hypoglycemia of infancy may be congenital or acquired, and rarely due to factitious hypoglycemia imposed by another. A thorough medical and social history, critical sampling, and screening for inborn errors of metabolism are crucial.

#### CASE

A 5-month-old, ex-29 weeker, twin female infant, born to a non-consanguineous couple was admitted at 4 months with severe refractory hypoglycemia and seizures requiring a glucose infusion rate (GIR) of 16 mg/kg/min. Critical sampling suggested hypoglycemia due to exogenous insulin: glucose 1.1 mmol/L, ketones 0.2 mmol/L, insulin 1,208 pmol/L (17.8–173), and C-peptide 18.2 pmol/L (366–1,466). Free fatty acids were not raised; growth hormones were 2.223 µg/L (0.14–6.27) and cortisol >1,000 nmol/L (145.4–619.4). Metabolic and genetic testing excluded glycogen storage disorder. Two months prior, she was admitted with a severe human metapneumovirus and parainfluenza infection, hypoglycemia, lactic acidosis and left ventricular hypertrophy. Her twin had died of sudden infant death syndrome. Examination revealed a small puncture mark on the abdomen, but otherwise it was unremarkable. The GIR dropped dramatically over 3 days and the intravenous dextrose was discontinued. Normoglycemia was maintained on 3-hourly feeds and she tolerated an age-appropriate fast before discharge. No hypoglycemic episodes were reported. Of note, the mother suffered from bipolar disorder and had access to insulin for gestational diabetes mellitus. The infant is currently in foster care, is scheduled to have neuroimaging and continues to have growth and developmental follow-up.

#### CONCLUSION

Factitious hypoglycemia should be suspected when there are red flags in the clinical history and critical sampling demonstrates high insulin levels, suppressed C-peptide in the face of hypoglycemia with low ketones and low free fatty acids. A multidisciplinary approach involving paediatrics, psychiatry, and child protective services is mandatory.

## EP\_P011

### A SILENT COMPLICATION OF PROLONGED IMMOBILIZATION: FRAGILITY FRACTURE IN A CHRONICALLY ILL ADOLESCENT WITH THALASSEMIA

Saw Shi Hui<sup>1</sup>

<sup>1</sup>Hospital Raja Permaisuri Bainun

#### INTRODUCTION

Adolescence is a crucial period for achieving peak bone mass. Risk factors such as chronic inflammation, endocrine issues, corticosteroid use, and extended immobility can lead to severe secondary osteoporosis and fragility fractures.

#### CASE

A 15-year-old female with transfusion-dependent thalassemia had been hospitalized for over a year following severe acute gastroenteritis complicated by septic shock, multiorgan failure, and secondary hemophagocytic lymphohistiocytosis (HLH). She received pulse methylprednisolone therapy for HLH, which was tapered over 6 months. Her clinical course was further complicated by critical illness polyneuropathy and post-infectious bronchiectasis, leading to ventilator dependence and a bedbound state.

During regular physiotherapy sessions, she developed a sudden onset of severe left shoulder pain. A radiograph of the left shoulder revealed a closed fracture of the humeral neck.

Biochemical evaluation showed normal serum calcium and phosphate levels, adequate vitamin D status, and normal alkaline phosphatase levels. However, follicle-stimulating hormone, luteinizing hormone (LH), and estradiol levels were undetectable, consistent with arrested puberty due to chronic illness. A bone mineral density scan showed a lumbar spine Z-score of -6, indicating severe osteoporosis.

She was started on intravenous zoledronate for secondary osteoporosis, and physiotherapy was resumed to improve musculoskeletal strength.

#### CONCLUSION

This patient was treated with bisphosphonate therapy for severe secondary osteoporosis caused by multiple risk factors, including chronic illness, prolonged immobility, corticosteroid use, and hypogonadotropic hypogonadism, with limited potential for spontaneous bone recovery. This case highlights the importance of early endocrine monitoring and bone health assessments to identify impaired bone growth and prevent fragility fractures in high-risk adolescents.

## EP\_P012

### A RARE PAEDIATRIC CASE OF AVPR2-RELATED NEPHROGENIC SYNDROME OF INAPPROPRIATE ANTIDIURESIS IN PENANG

Wei Lian Lean<sup>1</sup>, Raja Aimee Binti Raja Abdullah<sup>1</sup>,  
Gaik Siew Ch'ng<sup>2</sup>, Voon Lee Lim<sup>3</sup>

<sup>1</sup>Paediatric Endocrinology Unit, Department of Paediatric, Hospital Pulau Pinang

<sup>2</sup>Genetic Unit, Hospital Pulau Pinang

<sup>3</sup>General Paediatric, Department of Paediatric, Hospital Pulau Pinang

#### INTRODUCTION

Nephrogenic syndrome of inappropriate antidiuresis (NSIAD) is an uncommon X-linked genetic condition marked by euvolemic hyponatremia, which arises from a gain-of-function mutation in the arginine vasopressin receptor type 2 (AVPR2) gene. In contrast to the classic syndrome of inappropriate antidiuretic hormone secretion (SIADH), NSIAD is characterized by urine that is inappropriately concentrated even when arginine vasopressin (AVP) levels are low or undetectable. Failure to recognize NSIAD may result in recurrent hyponatremia and neurological morbidity.

#### CASE

A 2-year-old male was referred to us after recurrent vomiting and subsequently developed generalized tonic-clonic seizures due to hyponatremia (with a sodium level of 115 mmol/L). He needed sodium replacement through an intravenous drip of 3% saline and was stabilized with oral sodium chloride 20%. Urine osmolality was elevated, serum osmolality remained normal, and copeptin levels were low. He was discharged after a 10-day hospital stay. During follow-up, hyponatremia recurred despite his typical fluid intake of 1,200 mL/day. He was instructed to limit his fluid intake to 600–700 mL, which successfully normalized his serum sodium levels. Serum levels of adrenocorticotropic hormone, the aldosterone-to-renin ratio, thyroid function tests, and serum cortisol were all within normal ranges. Plasma AVP was unusually low (4.0 pmol/L). Whole exome sequencing (WES) confirmed a likely pathogenic hemizygous variant in AVPR2 gene located on chromosome Xq28, which was inherited from his mother. He is the only child, born from a non-consanguineous marriage, with no other significant family medical history.

#### CONCLUSION

Nephrogenic syndrome of inappropriate antidiuresis (NSIAD), is an uncommon, yet clinically significant condition. This case highlights the importance of considering a broad range of differential diagnoses when a

patient presents with hyponatremic seizure. Furthermore, obtaining a detailed family history is essential to identify potential hereditary factors that could contribute to the condition and for genetic counseling.

## EP\_P013

### PARTIAL ANDROGEN INSENSITIVITY SYNDROME PRESENTING AS AMBIGUOUS GENITALIA IN A 46, XY INFANT

Muhammad Shafiq Safwan bin Md Latip<sup>1</sup>, Shi Chyn Lim<sup>1</sup>, Yee Lin Lee<sup>1</sup>

<sup>1</sup>Department of Paediatrics, Faculty of Medicine and Health Science, Hospital Sultan Abdul Aziz Shah, Universiti Putra Malaysia

#### INTRODUCTION

Partial androgen insensitivity syndrome is a rare X-linked 46, XY disorder caused by androgen receptor dysfunction, producing variable genital ambiguity and complex diagnostic challenges in early infancy and childhood.

#### CASE

We report a term infant, currently aged 9 months, who was admitted to the Neonatal Intensive Care Unit at birth for glucose-6-phosphate dehydrogenase (G6PD) deficiency and noted to have ambiguous genitalia. The infant had no hypoglycemia, feeding intolerance, or electrolyte disturbances throughout admission. She is the second child of non-consanguineous parents, with no family history of disorders of sex development. Examination of the external genitalia revealed a prominent phallus without erectile tissue with mildly pigmented and rugated labioscrotal folds. There was no labioscrotal fusion. Bilateral gonads were palpable in both labioscrotal folds with one opening seen.

Pelvic ultrasonography showed bilateral small testes within the labioscrotal folds, with absence of Müllerian structures. Karyotype analysis confirmed 46, XY genotype. Human chorionic gonadotropin stimulation (HCG) testing at day 7 of life demonstrated normal baseline testosterone 4.9 nmol/L, but minimal testosterone rise 5.4 nmol/L at day 4 post HCG. Normal testosterone to dihydrotestosterone ratio and testosterone to androstenedione ratio excluded defects in androgen synthesis, while normal adrenal steroid profile ruled out congenital adrenal hyperplasia.

Gonadotropin-releasing hormone stimulation at 2 months old revealed a peak follicle-stimulating hormone of 8 IU/L and peak LH of 4 IU/L. Anti-Müllerian hormone level was markedly elevated >328 pmol/L (normal 5.5–103 pmol/L).

Whole-exome sequencing identified a hemizygous androgen receptor gene variant, p.(Pro818Ala), classified as a variant of uncertain significance with deleterious in silico predictions, consistent with X-linked partial androgen insensitivity syndrome.

#### CONCLUSION

This case highlights the necessity of early, systematic endocrine evaluation integrated with genomic testing in 46, XY DSD to achieve a definitive diagnosis, optimize sex assignment, and guide longitudinal, multidisciplinary management.

## EP\_P014

### CONGENITAL TOXOPLASMOSIS WITH CRANIAL DIABETES INSIPIDUS AND HYDROCHLOROTHIAZIDE

May Hou Yap<sup>1</sup>, Nurul Farah Wahidah Abd Razak<sup>1</sup>, Sze Teik Teoh<sup>1</sup>

<sup>1</sup>Hospital Sultanah Bahiyah

#### INTRODUCTION

Congenital toxoplasmosis (CTox) is common in Malaysia and classically presents with brain and eye involvement, causing hydrocephalus, intracranial calcifications, cataract, chorioretinitis, blindness, epilepsy, and psychomotor or mental impairment. Cranial diabetes insipidus (CDI) and panhypopituitarism rarely complicate its clinical course.

#### CASE

From 2024 to 2026, we had encountered three cases of CTox infants, of whom 2 (C1, C2) had a stormy neonatal period and passed away by 3 months old due to refractory seizures, while the 3rd (C3) survived. C1 (2.2 kg) was diagnosed antenatally from fetal ultrasound brain with severe ventriculomegaly, whereas C2 (2.47 kg) had multiple syndromic features, cleft lip, palate and anophthalmos. C3 (2.6 kg) was only diagnosed later by 1-month-old when she had afebrile seizures. C1 and C2 had severe hypernatremia (Na >150 mmol/L) within 1st week of life, but C3 had hypernatremia after surgical drainage of her hydrocephalus and administration of steroids. All were diagnosed with CDI and fulfilled the triad of polyuria, hypernatremia and inappropriate paired osmolality. During acute period, they were managed with IV vasopressin infusion with intensive monitoring. At low dose (0.1–0.3 mcg/kg/hour), all achieved eunatremia and euvolemia within 12 hours with no inadvertent hyponatremia. They also had central hypothyroidism and received L-thyroxine, with prior oral hydrocortisone, except C1. Their CDI persisted with highest Na 165 mmol/L in C1. They were started on tab hydrochlorothiazide (HCTZ) alongside low renal solute

load formula (LRSL) and EBM. HCTZ dose was titrated gradually from 0.5 to 1.0 mg/kg/dose and further to 1.5 mg/kg/dose. In between, subcutaneous desmopressin (DDAVP) 0.02–0.04 mcg were given during breakthrough DI. All cases responded to HCTZ at 1.5 mg/kg/dose, with varying intervals (daily to TDS). C3 went home after 6 weeks with HCTZ, L-thyroxine and hydrocortisone, together with oral anti-toxoplasmosis and anticonvulsants.

#### CONCLUSION

CTox with CDI presents a challenge during infancy, and a combination of LRSL with thiazide diuretics is an acceptable alternative, prior to definitive DDAVP therapy later.

## EP\_P015

### STARVED BONES, FAILING HEART: UNCOMMON YET LIFE THREATENING HYPOCALCEMIC CARDIOMYOPATHY IN NUTRITIONAL RICKETS

Siti Nur Hanim Najwa binti Sheikh Osman<sup>1</sup> and Sze Teik Teoh<sup>1</sup>

<sup>1</sup>Paediatric Department Hospital Sultanah Bahiyah

#### INTRODUCTION

We report an insidious presentation of hypocalcemic dilated cardiomyopathy (HDCM) in an infant with nutritional rickets and severe hypocalcemia, highlighting the myocardium's strict reliance on calcium-phosphate homeostasis.

#### CASE

A 3-month-old, small-for-gestational-age male (birth weight: 1.93 kg), with congenital cataracts and persistent neonatal cholestasis (negative hepatopathy and congenital infection screens) presented acutely with post-feeding cyanosis, requiring intubation for aspiration pneumonia. The mother denied prior apneic episodes, seizures, feeding difficulties, or heart failure symptoms. Clinically, there was no murmur or hyperactive pericardium. Chest radiograph revealed globular cardiomegaly. Echocardiography confirmed HDCM (LVEF 41%).

Bloodwork revealed profound hypocalcemia (1.16 mmol/L; normal 2.1–2.6), hyperphosphatemia (2.97 mmol/L), and markedly elevated alkaline phosphatase (2,411 IU/L). 25(OH)D3 was deficient (34.08 nmol/L). Secondary hyperparathyroidism (iPTH 19.55 pmol/L) represented an appropriate response. The mother had introduced goat's milk instead of cow's milk due to inadequate lactation. She took no supplements during pregnancy and was also vitamin D deficient.

Management included IV calcium gluconate, targeted anti-failure therapy (captopril, furosemide, spironolactone), and mechanical ventilation. High-dose cholecalciferol replenished depleted stores, alongside an active vitamin D analog (alfacalcidol) to bypass impaired hepato-intestinal pathways, stimulating calcium absorption. Extubated after 2 weeks with stabilized serum calcium, he was discharged on anti-failure therapy, oral calcium carbonate (54 mg/kg/day elemental), D-cure 25,000 IU 4-weekly, Ursodeoxycholic acid (45 mg 12-hourly), and multivitamins. Repeat echocardiography is planned at 3 months.

### CONCLUSION

This case underscores the vulnerability to nutritional rickets and late-onset hypocalcemia in SGA infants with inadequate maternal nutrition and impaired GI absorption. The calcium-phosphate axis is easily disrupted; high-phosphate substitutes (goat's milk) precipitously unmask hypocalcemia, overwhelming compensatory hyperparathyroidism. Proactive, dual-therapy metabolic supplementation is paramount to avert catastrophic, yet reversible, HDCM.

## EP\_P016

### MATURITY-ONSET DIABETES OF THE YOUNG ASSOCIATED WITH A ABCC8 VARIANT

**Jia Cheng Ong<sup>1,2,3</sup> and Suhaimi Hussain<sup>1,2</sup>**

<sup>1</sup>Department of Paediatrics, School of Medical Sciences, Universiti Sains Malaysia

<sup>2</sup>Hospital Pakar Universiti Sains Malaysia (HUSM)

<sup>3</sup>Faculty of Medicine, Universiti Sultan Zainal Abidin

### INTRODUCTION

Maturity-onset diabetes of the young (MODY) is a form of monogenic diabetes typically affecting young adults. There are 14 different genes that lead to pancreatic cell dysfunction causing MODY. Occurrence of MODY12 by ATP binding cassette subfamily C member 8 (ABCC8) gene is rare, comprising 1% of all the MODY subtypes.

### CASE

A 13-year-old male was incidentally found to be hyperglycemic during medical examination. He denied any hyperosmolar symptoms, polyphagia, nocturia and recurrent skin infection. He did not have any history of neonatal diabetes mellitus. His father had been diagnosed with type 1 diabetes mellitus at the age of 22 years old. On examination, he is thinly built with no goiter or acanthosis nigricans. HbA1c was 8.8%. His insulin antibodies were negative. Whole exome sequencing revealed a heterozygous missense mutation in ABCC8

gene (c.2209G>A; p.Val737Ile), where there was a single nucleotide mutation of Valine to Isoleucine at the position 737 of the ABCC8 gene. This variant was reported in the ClinVar database as having uncertain significance. Considering the patient's clinical features, this mutation is responsible for the disease. He was initially treated with sulfonylurea, namely glibenclamide; however, his continuous glucose monitoring was not optimized and required change to insulin therapy.

### CONCLUSION

This case explores the phenotypic spectrum of ABCC8-related MODY, showing that this mutation can present without neonatal diabetes and emphasizing the requirement of insulin as part of treatment. Genetic testing should be conducted in patients presenting with atypical clinical features of diabetes mellitus to initiate personalized treatment strategies.

## EP\_P017

### RECOGNIZING RENI SYNDROME: A CASE OF ADRENAL INSUFFICIENCY, ICHTHYOSIS, AND PROTEINURIA

**Noor Zakirah Noordin<sup>1</sup>, Saw Shi Hui<sup>1</sup>, Noor Arliena binti Mat Amin<sup>2</sup>**

<sup>1</sup>Paediatric Department, Hospital Raja Permaisuri Bainun

<sup>2</sup>Paediatric Department, Hospital Tunku Azizah

### INTRODUCTION

RENI syndrome (renal, endocrine, neurologic, and immune syndrome), also known as sphingosine-1-phosphate lyase insufficiency syndrome (SPLIS), is a rare autosomal recessive disorder caused by pathogenic variants in the SGPL1 gene. This gene encodes sphingosine-1-phosphate lyase, an enzyme responsible for the final step in sphingolipid degradation. Impaired enzyme activity results in the accumulation of sphingolipid intermediates, leading to multisystem involvement affecting the kidneys, adrenal glands, skin, immune system, and nervous system. Frequently reported manifestations include steroid-resistant nephrotic syndrome, primary adrenal insufficiency, ichthyosis, and neurological abnormalities.

### CASE

We report a 15-year-old male with a history of primary adrenal insufficiency diagnosed at age three after presenting with recurrent vomiting and abdominal pain. He was started on steroid replacement therapy and remained stable without episodes of adrenal crisis. He also had ichthyosis requiring dermatological follow-up. During routine surveillance, persistent proteinuria was detected, and urinary protein excretion increased over

time. Ultrasound showed renal parenchymal changes despite preserved renal function. Whole-exome sequencing identified a homozygous variant of uncertain significance in the *SGPL1* gene, consistent with RENI syndrome. He was started on enalapril for his proteinuria and continues to undergo multidisciplinary follow-ups. Both parents are consanguineous, but were not screened.

Mutations in *SGPL1* have increasingly been recognized as a monogenic cause of syndromic steroid-resistant nephrotic syndrome, associated with endocrine and dermatological features. Renal histopathology in cases reported often shows focal segmental glomerulosclerosis, reflecting podocyte injury due to disruption of sphingolipid signaling pathways. Early recognition is crucial, as patients need multidisciplinary care.

#### CONCLUSION

This case highlights the importance of considering RENI syndrome in patients presenting with early-onset primary adrenal insufficiency accompanied by renal and dermatological symptoms. Increased clinical awareness and prompt genetic testing can enable earlier diagnosis, guide long-term monitoring, and support appropriate genetic counseling.

## EP\_P019

### 46XX, TESTICULAR DSD WITH A NEGATIVE SRY: WHAT YOU SEE IS NOT ALWAYS THE TRUTH

Chia Ying Kang<sup>1</sup> and Sze Teik Teoh<sup>1</sup>

<sup>1</sup>Paediatric Department Hospital Sultanah Bahiyah

#### INTRODUCTION

46,XX testicular DSD is rare with incidence ~1 in 20,000 live births. Over 80–90% of cases are caused by translocation of SRY gene to X-chromosome or an autosome. Most present later in life with small testes, infertility and azoospermia. In SRY-negative cases, mutations in other genes (*SOX9*, *NR5A1*, etc) or duplications of *SOX9* are implicated. Our reported case is SRY negative, presenting at birth.

#### CASE

We report a case of 1-year 4-month-old term baby with atypical genitalia at birth. External genitalia examination showed penoscrotal malformation, genital tubercle (2.5 × 1.5 cm) with chordae, single opening at perineum, and two palpable gonads within both upper labio-scrotal folds. External genital score is 8.5. Ultrasound of inguinal region and pelvis showed bilateral hypoechoic ovoid structure at bilateral inguinal region suggestive of testes, with the right testis measuring 0.4 × 0.8 cm and left testis measuring 0.4 × 0.7 cm. No müllerian structures or ovaries were visualized.

Initial chromosome results (10 cells analyzed, 30 counted) reported 46, XX. Consultation with genetic pathologist and 2nd karyotype result still revealed 46, XX with FISH analysis confirming the absence of SRY. Mini-puberty screen (at 72 hours of life) showed follicle-stimulating hormone 3.5 IU/L, LH 1.72 IU/L, and testosterone 2.29 nmol/L. HCG stimulation test indicated adequate testosterone rise from 13 nmol/L (Day 1) to 29.38 nmol/L (Day 3), confirming the presence of functional Leydig cells. Serum AMH was within normal male range for age (421.3 pmol/L, 29–364 days: 235.5–1125.9). Gender is assigned as male and he recently underwent 1st stage hypospadias repair. Whole exome sequencing result is pending.

#### CONCLUSION

46,XX testicular DSD, with a negative SRY, is rare, and early diagnosis at birth enables counseling for future concerns such as male infertility and hypergonadotropic hypogonadism. A multidisciplinary management (involving endocrinology, surgery/urology, and genetics) is needed to ensure understanding and emotional support.

## EP\_P020

### THE SYSTEMIC COST OF INTRALESIONAL TRIAMCINOLONE FOR PAEDIATRIC KELOIDS

Naveen Nair Gangadaran<sup>1</sup>, Mastura Ibrahim<sup>1</sup>, Meenal Mavinkurve<sup>2</sup>

<sup>1</sup>Department of Paediatrics, Hospital Tuanku Ja'afar

<sup>2</sup>Department of Paediatrics, International Medical University

#### INTRODUCTION

Intralesional triamcinolone acetonide (TAC) is an accepted management option for paediatric keloid. TAC is a corticosteroid with five times the potency of hydrocortisone and acts by inhibiting fibroblast growth and thus keloid size. Dermatological adverse effects of TAC are common, but repeated high-dose intralesional TAC can cause the rare complication of Cushing syndrome and suppression of the hypothalamic–pituitary–adrenal (HPA) axis.

#### CASE

We report the case of an 11-year-old female referred for worsening lower limb striae and low serum cortisol. Prior to referral, intralesional TAC was administered by a general practitioner to a left lower limb keloid which had developed following an orthopedic intervention. A total of five injections were administered over 4 months: a cumulative dose of 150 mg (equivalent to 700 mg hydrocortisone). The last dose was administered 6 months prior to referral. The morning serum cortisol was low (<13.8 nmol/L) with a concomitantly low adrenocorticotropic hormone (ACTH 0.41 pmol/L) level, consistent with suppression of the

HPA axis secondary to exogenous steroids. Renin (84.80 mU/L), aldosterone (280.40 pmol/L), testosterone (0.31 nmol/L), estradiol (85.9 pmol/L) and thyroid function were normal. Physiological oral hydrocortisone replacement was promptly commenced, with education on adrenal crisis and sick days while awaiting recovery of the HPA axis.

### CONCLUSION

This case illustrates the serious complication of Cushing syndrome with secondary HPA axis suppression due to repeated intralesional TAC therapy for paediatric keloid scars. Factors such as appropriate paediatric doses, size of the keloid, site of injection (dermal, not subcutaneous), and frequency of injections should all be given due consideration before using TAC. Clinicians prescribing steroids to children should be aware that suppression of the HPA axis is a very real and life-threatening complication and that steroids should be prescribed judiciously.

## EP\_P021

### GROWTH HORMONE THERAPY IN PAEDIATRIC ONCOLOGY SURVIVORS: CASE SERIES FROM A MALAYSIAN TERTIARY CENTRE

Nur Amalina Yusof<sup>1</sup>, Lim Poi Giok<sup>1</sup>, Arliena Amin<sup>1</sup>

<sup>1</sup>Paediatric Endocrinology Unit, Department of Paediatrics, Hospital Tunku Azizah

### INTRODUCTION

Growth hormone deficiency (GHD) is a recognized endocrine complication among childhood cancer survivors resulting from disruption of hypothalamic-pituitary axis due to tumors, neurosurgery, or cranial irradiation. While recombinant human growth hormone (rhGH) therapy improves growth and metabolic outcome, concerns remain regarding its long-term safety with risk of tumor recurrence and secondary neoplasm. We present a case series of five paediatric oncology survivors with confirmed GHD receiving rhGH in Hospital Tunku Azizah, highlighting our clinical experience in comparison with international practice.

### CASE

Five paediatric oncology survivors (acute lymphoblastic leukemia, craniopharyngioma, medulloblastoma, and supratentorial PNET) with GHD were commenced on rhGH therapy 2.5–5.5 years after completion of cancer treatment. All patients had significant short stature with a mean height SDS of -3.22 prior to the initiation of therapy. GHD was confirmed biochemically with low IGF-1 level and dynamic testing (peak GH 0.35–4.61 ng/mL). Among the four patients with brain tumors, two had stable residual

disease while the remaining were tumor-free. rhGH therapy was temporarily ceased in two patients due to minor increment in tumor size but was successfully resumed following stabilization without further complications to date. Two patients are concurrently on pubertal induction. Most patients demonstrated catch-up growth with increased height velocity, supporting the efficacy of rhGH in this population. No secondary malignancies or significant adverse events were observed during follow-up.

### CONCLUSION

Paediatric oncology survivors with GHD in this series demonstrated a favorable response to rhGH therapy, evidenced by improvements in height SDS and growth velocity, while maintaining oncological stability in the majority of cases. Our findings are consistent with international data, supporting cautious but appropriate use of rhGH in this population. Careful patient selection and close multidisciplinary monitoring remain essential.

## EP\_P022

### WHEN PUBERTY COMES TOO SOON: CENTRAL PRECOCIOUS PUBERTY WITH PITUITARY MICROADENOMA AND PINEAL CYST

Fawza Nabila Faudzi<sup>1</sup>, Asmalaini Mohamad<sup>1</sup>, Nalini M. Selveindran<sup>2</sup>

<sup>1</sup>Paediatric Department, Hospital Sultanah Nur Zahirah

<sup>2</sup>Paediatric Department, Hospital Putrajaya

### INTRODUCTION

Central precocious puberty (CPP) is defined as premature activation of the hypothalamic-pituitary-gonadal axis, resulting in the development of secondary sexual characteristics before 8 years of age in girls. While most cases are idiopathic, intracranial pathologies such as pituitary lesions may cause CPP. Early identification is essential to optimize outcomes and minimize psychosocial impact. We report a case of CPP associated with pituitary microadenoma and pineal cyst from the Paediatric Department, Hospital Sultanah Nur Zahirah.

### CASE

A 4-year-old female presented with bilateral breast enlargement, with ultrasonography showing normal fibroglandular tissue. Breast development was noted since 3 months of age, with whitish vaginal discharge from 2 years. She demonstrated accelerated growth, with height and weight above the 95th centile. There were no features suggestive of peripheral causes or raised intracranial pressure. Examination revealed Tanner stage A1B3P2. Bone age was markedly advanced (11 years vs. chronological age 4 years).

Hormonal evaluation showed elevated LH (3.28 IU/L) and follicle-stimulating hormone (4.79 IU/L), consistent with CPP. MRI demonstrated focal delayed enhancement in the posterolateral pituitary suggestive of microadenoma, and an incidental pineal cyst without complex features. Ophthalmological assessment was normal. Neurosurgical evaluation advised conservative management with annual imaging surveillance. Intramuscular Triptorelin was initiated at 4 years 1 month. Follow-up showed regression of pubertal progression, resolution of vaginal discharge, and reduced growth velocity to 6 cm/year.

#### CONCLUSION

This case highlights the importance of thorough evaluation in CPP to identify underlying intracranial pathology. Early initiation of gonadotropin-releasing hormone analog therapy effectively halts pubertal progression and preserves growth potential.

### EP\_P023

#### BECKWITH-WIEDEMANN SYNDROME PRESENTING AS PERSISTENT NON-KETOTIC HYPOGLYCEMIA IN A PRETERM INFANT

Wan Nurzahiah Wan Zakaria<sup>1</sup>, Yee Lin Lee<sup>1</sup>, Sin Yin Gan<sup>1</sup>, Tong Wooi Ch'ng<sup>2</sup>, Zurina Zainudin<sup>1</sup>

<sup>1</sup>Department of Paediatrics, Hospital Sultan Abdul Aziz Shah, Universiti Putra Malaysia

<sup>2</sup>Sunway Medical Centre

#### INTRODUCTION

Beckwith-Wiedemann syndrome (BWS) is a congenital overgrowth disorder associated with dysregulation of genes on chromosome 11p15.5. Infants with BWS can present with hyperinsulinemic hypoglycemia. There are also distinctive clinical features including macrosomia, macroglossia and visceromegaly that may raise suspicion of this diagnosis.

#### CASE

A preterm female infant of 30 weeks gestation with a birth weight of 1.87 kg (97<sup>th</sup> centile) had recurrent hypoglycemia in the neonatal period, requiring escalation to a maximum glucose infusion rate of 17.6 mg/kg/min. Hypoglycemia only resolved after starting intravenous glucagon infusion. Critical sampling during hypoglycemia revealed serum insulin 3.9 µU/mL (3–25 µU/mL), serum ketone 0.2 mmol/L, cortisol 3,053 nmol/L and growth hormone 16.2 ng/mL. These findings supported the diagnosis of non-ketotic hyperinsulinemic hypoglycemia. She was commenced on oral diazoxide with resolution of hypoglycemia and discontinuation of glucagon.

Examination at birth revealed macroglossia, hepatomegaly and ballotable kidneys. An initial US abdomen at birth revealed bilateral enlarged kidneys but normal liver. An initial chromosomal study revealed karyotype 46, XX. Over time, additional clinical features became evident fulfilling the diagnostic criteria for BWS, that is, polyhydramnios, large for gestational age, transient hypoglycemia, hyperinsulinism, macroglossia, hemihypertrophy, facial nevi, bilateral ear creases, hepatomegaly and ballotable kidney.

A repeat US abdomen surveillance at 4 months old revealed a heterogeneous liver mass with marked vascularity, prompting a diagnosis of hepatic hemangioma. She was commenced on oral propranolol, with reduction in the size and vascularity of the liver hemangioma and decline in alpha-fetoprotein levels.

#### CONCLUSION

The clinical features of BWS may not be recognizable in a preterm baby in early neonatal period. Careful clinical examination should be done in a baby with persistent hyperinsulinemic hypoglycemia for underlying syndromal causes. US surveillance should also be carried out due to increased risk of hepatoblastoma or liver hemangioma in BWS, as was seen in this case.

### EP\_P024

#### BEYOND OBESITY: DIAGNOSTIC CHALLENGES OF BARDET-BIEDL SYNDROME

Shahidatul Munirah Mohammad Salihuddin<sup>1,2</sup> and Suhaimi Hussain<sup>1</sup>

<sup>1</sup>Department of Paediatrics, School of Medical Sciences, Universiti Sains Malaysia

<sup>2</sup>Faculty of Medicine, Universiti Sultan Zainal Abidin

#### INTRODUCTION

Bardet-Biedl Syndrome is a rare autosomal recessive disorder characterized by multisystem manifestations, such as early-onset obesity, hypogonadotropic hypogonadism, retinal dystrophy, polydactyly, renal anomalies and intellectual disability. Phenotypic variability makes diagnosis challenging. Central obesity and hypogonadotropic hypogonadism are frequently observed, but often overlooked.

#### CASE

We report a 12-year-old male who was referred at the age of 10 years for evaluation of central obesity and buried penis. He was born at term with birth weight of 3,200 g. Both parents were non-consanguineous, and antenatal history was unremarkable. Early-onset excessive weight gain was noted from infancy, with hyperphagia during early childhood.

His weight remained persistently above the 95<sup>th</sup> centile, and height around the 90<sup>th</sup> centile, slightly exceeding mid-parental height expectations. Buried penis was identified at birth. Polydactyly is absent. He also demonstrates learning difficulties. Early diagnostic considerations include Klinefelter syndrome due to buried penis, and Prader-Willi Syndrome due to central obesity with co-existence of learning difficulties. Further evaluation excluded Prader-Willi Syndrome, and conventional karyotyping ruled out Klinefelter syndrome. Clinical assessment revealed pre-pubertal Tanner stage, bilaterally palpable testes (3 mL), and a stretched penile length <2 cm. Endocrine evaluation demonstrated a prepubertal response to LHRH stimulation, and poor testosterone response to hCG, suggesting hypogonadotropic hypogonadism with poor Leydig cell function. Whole exome sequencing confirmed a BBS2 gene mutation, establishing the diagnosis of Bardet-Biedl Syndrome. This mutation disrupts hypothalamic signaling, leading to the multisystem involvement observed. Over the follow-up period, he reported difficulty with night vision.

#### CONCLUSION

Not all syndromic obesity is immediately apparent—Bardet-Biedl Syndrome should be considered even in the absence of classical features. Marked phenotypic variability often leads to delayed diagnosis, highlighting the need for vigilant clinical suspicion and prompt genetic study to ensure timely recognition. Early recognition is critical, as endocrine and other associated complications can significantly impact long-term health.

## EP\_P025

### ABCD SYNDROME: A RARE BUT UNDERRECOGNIZED CAUSE OF HYPERCALCEMIA IN DOWN SYNDROME

Nurul Farah Wahidah Abd Razak<sup>1</sup> and Sze Teik Teoh<sup>1</sup>

<sup>1</sup>Hospital Sultanah Bahiyah

#### INTRODUCTION

ABCD syndrome (ABnormal Calcium-Creatinine-Calculosis in Down syndrome) is a rare tetrad of hypercalcemia, hypercalciuria, nephrocalcinosis, and renal impairment in children with Down syndrome, often with delayed diagnosis resulting in irreversible renal damage.

#### CASE

We report a 7-year-old male with Down syndrome, who previously had a stormy neonatal period due to large atrial-septal-defect and pulmonary hypertension, and required surgery at 3-years-old with prior prolonged ventilation. He was since bedbound with severe spastic diplegia, complicated by GERD and food aversion, requiring nasogastric

tube feeding. He was discovered to have hypercalcemia and renal impairment during admission in district hospital for febrile illness with gastrointestinal symptoms. Initial serum calcium was 2.78 mmol/L, phosphate 1.54 mmol/L, magnesium 0.96 mmol/L, ALP 210 IU/L, urea 18.6 mmol/L, and creatinine 266 umol/L. Renal impairment did not improve and ultrasound KUB revealed bilateral small kidneys with medullary nephrocalcinosis. Consultation with the paediatric nephrologist concluded as CKD-stage-4. He was transferred to our centre. He demonstrated severe hypercalcemia (3.44 mmol/L), hypercalciuria (urine-calcium-to-creatinine-ratio of 1.17 mmol/mmol, >95 th%), and suppressed iPTH (0.9 pmol/L, 1.6–6.9), suggesting PTH-independent process. 25-OH-Vit-D3 was 134 nmol/L (74–250, sufficient). He was more irritable and moody, but no seizures. ECG was normal. Skeletal assessment did not reveal osteolytic changes or increased resorption. He was investigated by paediatric hemato-oncologists, with negative findings, despite extensive search for hematological or bone malignancy and granulomatous disease. His ESR and immunoglobulin level was high for unknown reasons. He was treated with intravenous and oral hydration, dietary calcium restriction with modified low-calcium formula, assisted by dietitian, and IV pamidronate infusion (0.125 mg/kg) stat dose, resulting in stabilization of serum calcium level (2.5 mmol/L), which persisted for about 8 weeks during follow-up.

#### CONCLUSION

ABCD syndrome should be considered in Down syndrome children presenting with unexplained hypercalcemia. Early recognition and intervention are vital.

## EP\_P026

### BEYOND GRAVES' DISEASE AND TYPE 1 DIABETES MELLITUS: THYROTOXIC HEART FAILURE AND EMERGING POLYGLANDULAR SYNDROME TYPE 2

Sharon Mui Kim Lim<sup>1</sup>, Li Yuen Nyin<sup>2</sup>, Zulaikha Che Imbi<sup>3</sup>, Farizan AB Ghani<sup>1</sup>

<sup>1</sup>Paediatric Department, Hospital Melaka

<sup>2</sup>Radiology Department, Hospital Melaka

<sup>3</sup>Pathology Department, Hospital Putrajaya

#### INTRODUCTION

The coexistence of autoimmune thyroid disease and type 1 diabetes mellitus is well established; however, their sequential or concurrent presentation in very young children remains uncommon. We demonstrate two paediatric cases with concurrent Graves' disease and type 1 diabetes mellitus, each illustrating distinct complications and clinical courses.

## CASES

A 3-year-old female presented with anterior neck swelling, weight loss, and persistent tachycardia. Biochemical evaluation confirmed severe thyrotoxicosis (T4 152.3 pmol/L, TSH <0.008 mIU/L) with markedly elevated anti-thyroglobulin and anti-thyroid peroxidase antibodies. Thyroid ultrasonography demonstrated a diffusely enlarged, hypervascular gland with nodular changes, consistent with Graves' disease. During longitudinal follow-up, she developed polyuria, polydipsia, and hyperglycemia, with positive pancreatic autoantibodies confirming type 1 diabetes mellitus. Notably, serial early morning cortisol measurements were persistently low, raising concern for evolving adrenal insufficiency and suspicion of autoimmune polyglandular syndrome type 2. Comprehensive endocrine evaluation is ongoing.

A 4-year-old male presented with a 1-year history of recurrent self-limiting fever followed by significant fatigability for 1 month. Salient examination on admission revealed tachycardia, anterior neck swelling, and an incidental pansystolic murmur. Thyroid function tests confirmed thyrotoxicosis (T4 38.6 pmol/L, TSH <0.008 mIU/L). Serial serum glucose was markedly elevated on admission, prompting further testing that confirmed type 1 diabetes mellitus with positive pancreatic autoantibodies. Echocardiography demonstrated moderate-to-severe mitral regurgitation with heart failure secondary to prolonged uncontrolled hyperthyroidism state. Cardiac function improved with restoration of a euthyroid state, highlighting the reversible nature of thyrotoxic heart failure.

## CONCLUSION

These cases highlight the progressive nature of childhood autoimmunity, where Graves' disease may precede the development of type 1 diabetes mellitus and evolving features of autoimmune polyglandular syndrome type 2. They further emphasize that thyrotoxic heart failure is potentially reversible with restoration of a euthyroid state, underscoring the importance of early recognition and vigilant long-term surveillance.

## EP\_P027

### NOT JUST DEHYDRATION: A CASE OF EARLY ONSET PERSISTENT HYPERNATREMIA IN A PRETERM BABY

Sin Yin Gan<sup>1</sup>, Wan Nurzahiah Wan Zakaria<sup>1</sup>, Zurina Zainudin<sup>1</sup>, Yee Lin Lee<sup>1</sup>

<sup>1</sup>Department of Paediatrics, Hospital Sultan Abdul Aziz Shah, Universiti Putra Malaysia

## INTRODUCTION

Hypnatremia in preterm babies is often due to insensible water loss, inadequate fluid intake or sodium imbalance due to immature kidneys. Congenital nephrogenic diabetes insipidus (CNDI) is an uncommon cause of hypernatremia in neonates and presents shortly after birth. Early recognition is important to prevent severe dehydration, electrolytes imbalance and neurological complications.

## CASE

We report a case of a preterm 32-week female infant, with a birth weight of 1.14 kg with persistent hypernatremia (146–156 mmol/L) from day 4 of life. She received total parenteral nutrition since birth and was started on breastmilk since day 5 of life. The baby was mildly dehydrated with weight loss and high urea (6.5 mmol/L) at day 7 of life. Total fluids were increased to 160 mL/kg/day but serum sodium remained elevated even though the urea had normalized. The infant was also noted to have high urine output (5–6 mL/kg/hour) since day 3 of life and suboptimal weight gain.

Further evaluation at age 1 month revealed urine osmolality 71 mOsm/kg, serum osmolality 308 mOsm/kg and urine sodium <20 mmol/L when serum sodium was 150 mmol/L, suggestive of DI. A trial of desmopressin showed unchanged serum sodium (Na), suggesting nephrogenic DI. Administration of intravenous fluids of 1/5NSD10% resulted in further increase of both sodium (159 mmol/L) and serum osmolality (326 mOsm/kg) with low urine osmolality (111 mOsm/kg). Intravenous fluids were discontinued and she was started on hydrochlorothiazide (1 mg/kg/dose bd), resulting in gradual normalization of sodium 138 mmol/L. Post discharge, she had good weight gain and normal developmental milestones at corrected age of 1.5-month-old. Due to early onset hypernatremia, the infant was referred for genetic testing to rule out CNDI.

## CONCLUSION

Early onset persistent hypernatremia and high urine output despite adequate fluid management should prompt evaluation of DI. Early diagnosis is crucial to prevent a chronic state of hypernatremia that can lead to growth and developmental delay.

## Basic Science E-Poster

### EP\_S001

#### THE EFFECT OF TUBE TYPE AND TIME ON GLUCOSE STABILITY

Prisheila Mahendran<sup>1</sup>, Jeyakantha Ratnasingam<sup>2</sup>, Farhi Ain binti Jamaluddin<sup>1</sup>, Ai Chin Yeoh<sup>1</sup>, Nurdini binti Alias<sup>1</sup>, Khalida binti Ramdzan<sup>1</sup>, Pavai Sthaneshwar<sup>1</sup>

<sup>1</sup>Division of Laboratory Medicine, Department of Pathology

<sup>2</sup>Endocrine Unit, Department of Medicine, University Malaya

#### INTRODUCTION

Glycolysis continues after blood collection and may reduce glucose concentrations in vitro, potentially compromising diagnostic accuracy. The effectiveness of glycolysis-inhibiting additives differs among blood collection tubes. Citrate rapidly inhibits glycolysis through immediate acidification, whereas fluoride acts more slowly by inhibiting enolase at a later stage of the glycolytic pathway. This study aimed to compare short-term glucose stability in four commonly used blood collection tubes under routine laboratory conditions.

#### METHODOLOGY

Venous blood samples were collected from 100 volunteers into Rapid Serum Tubes (RST), Barricor tubes, Fluoride tubes, and Citrate tubes. Glucose concentrations were measured at 30 and 60 minutes after collection using the hexokinase method. A repeated-measures ANOVA was performed to evaluate the effects of Time, Tube Type, and the Time × Tube interaction ( $\alpha = 0.05$ ), followed by Bonferroni-adjusted pairwise comparisons.

#### RESULTS

At 30 minutes, glucose concentrations were highest in the Fluoride tube (5.528 mmol/L), followed closely by the Citrate tube (5.505 mmol/L), while lower values were observed in RST (5.434 mmol/L) and Barricor tubes (5.430 mmol/L). By 60 minutes, glucose levels had declined in all tubes; however, the decrease was more pronounced in serum-based tubes. RST values fell to 5.277 mmol/L and Barricor to 5.300 mmol/L, whereas Fluoride and Citrate tubes remained relatively stable at 5.449 mmol/L and 5.489 mmol/L, respectively. Overall, glucose decreased significantly between 30 and 60 minutes (mean decrease = 0.096 mmol/L,  $p < 0.001$ ; partial  $\eta^2 = 0.705$ ). Tube Type also had a significant effect on glucose concentrations ( $F(3,297) = 42.06$ ,  $p < 0.001$ ; partial  $\eta^2 = 0.298$ ).

#### CONCLUSION

Fluoride and Citrate tubes provided the most effective preservation of glucose concentrations over 60 minutes, showing minimal glycolytic decline. In contrast, RST and Barricor tubes demonstrated significantly greater glucose loss, highlighting the importance of rapid processing when serum-based tubes are used.

### EP\_S003

#### THERAPEUTIC PLASMA EXCHANGE FOR PREOPERATIVE STABILIZATION IN GRAVES' DISEASE COMPLICATED BY AGRANULOCYTOSIS

Muhammad Azim Puad<sup>1</sup>, Nadia Nordin<sup>1</sup>, Elliyyin Katiman<sup>1</sup>, Hazwani Aziz<sup>1</sup>, Hidayatil Alimi Keya Nordin<sup>1</sup>

<sup>1</sup>Hospital Tengku Permaisuri Norashikin

#### INTRODUCTION

Severe thyrotoxicosis is particularly difficult to manage when antithyroid drugs are contraindicated. Therapeutic plasma exchange (TPE) is an adjunctive option in complicated hyperthyroidism, including thyroid storm and refractory thyrotoxicosis, through the rapid removal of circulating thyroid hormones, hormone-binding proteins, cytokines, and thyroid autoantibodies. However, its precise role and indications remain incompletely defined. We report two patients with Graves' disease complicated by carbimazole-induced agranulocytosis in whom TPE was used as bridging therapy before total thyroidectomy.

#### CASES

The first patient was a 32-year-old female who developed carbimazole-induced agranulocytosis 1 month after the diagnosis of hyperthyroidism. Biochemical control remained unsatisfactory despite second-line therapy with high-dose lithium, cholestyramine, propranolol, corticosteroids, and 5 days of Lugol's iodine. Over 8 days, free thyroxine (fT4) increased by 13%, necessitating TPE for preoperative stabilization. Following three cycles over 4 days, fT4 decreased by 20%, from 52 to 41 pmol/L, enabling successful total thyroidectomy.

The second patient was a 26-year-old female who presented with neutropenic sepsis and severe agranulocytosis 2 months after being diagnosed with Graves' disease. She received second-line therapy, and neutrophil recovery occurred only after 7 days of granulocyte colony-stimulating factor. TPE, together with Lugol's iodine, was then initiated as bridging therapy before surgery. After 5 days of Lugol's iodine and three TPE cycles, fT4 decreased by 43%, from 58 to 33 pmol/L, permitting total thyroidectomy.

#### CONCLUSION

These cases highlight TPE as a useful bridging strategy in Graves' thyrotoxicosis when antithyroid drugs are precluded by agranulocytosis, and conventional second-line therapy fails to achieve adequate biochemical control. TPE may facilitate timely stabilization and safe progression to definitive surgical treatment.

MEMS ANNUAL CONGRESS

MEMS ANNUAL CONGRESS  
**MAC 16** 2026  
SYNERGY IN ENDOCRINOLOGY

**MEMS**  
Malaysian Endocrine  
& Metabolic Society

# MAC OLYMPIAD

## ENDOCRINE CHALLENGE CUP IS BACK!

QUEST FOR THE TITLE OF '2026 CHAMPION'  
WHO WILL EMERGE VICTORIOUS?

### TEAM NAME

The Metabolic Mavericks  
Borneo T3 Warriors  
Sabah Endocrine Kids  
Sibu EndoGenius  
HAGMA  
T3-rific team  
Triotoxicosis  
Axis Avengers  
Unique Unicorn  
Ady-know-mah  
CortiSoul  
Sugar Rush

### HOSPITAL

Hospital Port Dickson  
Hospital Queen Elizabeth II  
Hospital Queen Elizabeth II  
Hospital Sibu  
Hospital Tengku Permaisuri Norashikin  
Hospital Selayang  
Hospital Sultan Abdul Aziz Shah UPM  
Hospital Sultan Abdul Aziz Shah UPM  
Hospital Sultanah Nur Zahirah  
Hospital Putrajaya  
Hospital Putrajaya  
University Malaya Medical Centre

## SEMI FINAL & GRAND FINALE

Friday, 22<sup>nd</sup> May 2026 | 1630 – 1720  
Clarke Ballroom, Level 6, Le Meridien

LET THE GAME...  
**Begin!**

# Tour d'MAC & Tour d' Sentral

**2** Tour d'MAC  
 AD-747 Spinning  
 Exercise Bike

**1** Tour d'MAC  
 ADSPORTS 2-in-1  
 Upright Magnetic  
 Elliptical Bike Cross Trainer

**3** Tour d'MAC  
 FC 3-in-1 Mini  
 Stepper x 3 units

*Tour d' Sentral*  
 F38 Mini stepper  
 with Resistance  
 Bands x 6 units



## Rules & Regulation

1. Both the *Tour d'MAC* and *Tour d' Sentral* are open to all registered MAC16 delegates.
2. Each delegate is given 2 separate cards:
  - i. Delegates must visit ALL the Congress exhibitors' booths and complete the stamping for *Tour d'MAC*.
  - ii. Delegates must visit all the exhibitors' booths in Sentral Ballroom and complete the stamping for *Tour d' Sentral*.
3. The *Tour d' Sentral* card must be submitted to the Congress registration counter before 9:30 am on Saturday, 23 May 2026. The draw will be held after Plenary 4, in Hilton Ballroom B.
4. The *Tour d'MAC* card must be submitted to the Congress registration counter before 10:30 am on Sunday, 24 May 2026. The draw will be held during tea break at 10:50 am in Hilton Ballroom B.
5. Each participant is entitled to only one entry. No replacement card will be given for any lost cards.
6. Delegates must be present to claim and collect their prizes.
7. Collection Expenses: Winners are responsible for any additional costs to collect prizes, including transportation/courier charges.

# WITH SINCERE GRATITUDE TO OUR AMAZING SPONSORS

## Diamond Sponsor



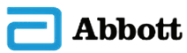## Diamond & Platinum Sponsor



## Platinum Sponsors



## Gold Sponsors



## Silver Sponsors



## Exhibitors



## Other Sponsors

